

A Comparison of 2D versus 3D Radiography in the Treatment Planning of Root Canal Treated Teeth with Periapical Lesions

Heidi Kohltharber, DDS

A thesis submitted to the faculty of the University of North Carolina at Chapel Hill in partial fulfillment of the requirements for the degree of Master of Science in the School of Dentistry, (Oral and Maxillofacial Radiology).

Chapel Hill
2012

Approved by:

Don Tyndall, DDS, MSPH, PhD

John Ludlow DDS, Msc

Eric Rivera, DDS, MS

ABSTRACT

HEIDI KOHLTFARBER, DDS: A Comparison of 2D versus 3D Radiography in the
Diagnosis and Treatment Planning of Root Canal Treated Teeth with Periapical Lesions
(Under the direction of Donald Tyndall)

Objectives: The aims of the study were to assess diagnostic efficacy in lesion detection, evaluate the effect of cone beam CT on treatment planning and clinician confidence.

Methods: Forty digital periapical radiographs alone were compared with the use of both periapical radiographs and cone beam computed tomography. The two modalities were compared by four endodontic residents. The observers were asked to diagnose periapical lesions as well as provide a treatment plan and their confidence in the treatment plan for each case. **Results:** There was a statistically significant difference between the two modalities for lesion detection (aim 1) and a statistically significant decrease in proposed treatment for the control group (aim 2) with a decrease in clinician confidence (aim 3). **Conclusion:** The additional information provided by cone beam CT led to an increase in periapical lesion detection and a treatment change in one third of the cases associated with less confidence.

To my wonderful husband and best friend, Bobby and my two beautiful girls,
Madison and Haley - thank you for your patience and willingness to go on this great
adventure with me! I love you more than words can say!!

ACKNOWLEDGEMENTS

I wish to acknowledge the sponsorship of Loma Linda University School of Dentistry for allowing me to go through the Oral and Maxillofacial Radiology Program at UNC - Chapel Hill

Many people helped to make this research possible and I wish to especially acknowledge my mentor, Dr. Donald Tyndall as well as my committee members, Dr. John Ludlow and Dr. Eric Rivera

A special thank you to my parents, Audrey and David Zinke for your wonderful support and encouragement

TABLE OF CONTENTS

List of Figures.....	vi
List of Tables.....	vii
A. Introduction.....	1
B. Background and Significance.....	4
C. Current CBCT Systems and Endodontic Applications.....	6
D. Summary of Current Literature.....	9
E. Selection Criteria	17
F. Study Aims.....	19
G. Material and Methods.....	20
H. Results.....	25
I. Discussion.....	28
J. Conclusion.....	34
K. References.....	46

LIST OF FIGURES

Figure 1. Tooth #14 demonstrates a root canal treated tooth with continued symptoms.....	35
Figure 2. Periapical radiograph and cone beam CT of tooth #9 with internal root resorption.....	35
Figure 3. Periapical radiograph and cone beam CT showing external root resorption.....	36
Figure 4. Periapical radiograph and cone beam CT showing a broken file at the apices of tooth #7.....	36
Figure 5. Example of a case where three dimensional imaging was important for the pre-planning of an apicoectomy.....	36
Figure 6. Periapical radiograph and cone beam CT of a previously root canal treated tooth(#19) with continued symptoms.....	37
Figure 7. A patient with a previously endodontically treated tooth who continued to have symptoms.....	37
Figure 8. A maxillary anterior tooth (#8) that was found to have a fracture.....	37
Figure 9. Three dimensional radiography helped to identify a dilacerated root.....	38
Figure 10. Receiver operating characteristics (ROC) and summary statistics for observer one.....	38
Figure 11. Receiver operating characteristics (ROC) and summary statistics for observer two.....	38
Figure 12. Receiver operating characteristics (ROC) and summary statistics for observer three.....	39
Figure 13. Receiver operating characteristics (ROC) and summary statistics for observer four.....	39
Figure 14. Example of beam hardening observed in a scan.....	40

LIST OF TABLES

Table 1. Small field of view cone beam CTs available in the United States as of June 2011.....	41
Table 2. Az scores and standard deviations for each modality by observer.....	42
Table 3. The results of the Univariate analysis of variance by observer and modality.....	42
Table 4. Summary statistics for the detection of lesions by observers based on imaging modality.....	43
Table 5. Overall changes and directionality of the change in treatment plans from all observers between modalities.....	43
Table 6. Change in treatment plan for the control teeth per observer.....	43
Table 7. Change in treatment plan for the sample teeth per observer.....	44
Table 8. Overall changes and directionality of change in the clinician's confidence of their treatment plan between modalities.....	44
Table 9. Change in clinician's confidence for each observer with the addition of cone beam CT.....	44
Table 10. Inter-observer Agreement for Periapical Lesion Detection	45
Table 11. Inter-observer Agreement for Treatment Plan.....	45
Table 12. Intra-observer Agreement for Each Question.....	45

Introduction:

Patients with root canal treated teeth that have periapical lesions and associated symptomatology can pose a serious challenge in terms of diagnosis and treatment planning. The exact problem is often hard to discern and a patient may have continued symptoms without any radiographic signs of further periapical disease. It is important to correctly identify the problem and plan accordingly. A survey of the literature suggests that two-dimensional radiographs are unable to clearly demonstrate three dimensional problems. This can lead to an incorrect treatment plan, poor prognosis and frustration on the part of the clinician and the patient. Studies have shown that periapical lesions that are confined within the cancellous bone are usually not detected until they start to erode the cortical plate[1, 2]. There are multiple limitations to two dimensional radiographs such as superimposition of three dimensional anatomy as well as possible exposure or geometric errors[3]. This particular area is one that would benefit from three dimensional imaging to accurately represent the true nature of the patient's problem. The advent of cone beam CT (CBCT) has changed the face of dentistry in many ways and has proven to be beneficial in diagnosing periapical lesions that periapical radiographs failed to show.

Limited volume CBCT's are excellent for endodontics because only the teeth of interest are imaged. The Kodak 9000 3D (*KODAK Dental Systems, Carestream Health Rochester NY, USA/Distributed exclusively in the USA by PracticeWorks,Atlanta, GA, USA*) in particular has a voxel size of 0.076mm which provides the highest image resolution of any CBCT currently on the market. It has a field of view of 50mm x 38mm[3]. CBCTs use

ionizing radiation and it is always important to use the lowest dose consistent with the diagnostic task. Ionizing radiation can be compared to digital panoramic radiographs that have an average effective dose of 14.7 μSv which is equivalent to about 2 days of per capita background radiation. Ludlow, J.B [4] found that the Kodak 9000 3D has an effective dose of between 5.3 to 38.3 μSv (using the 2007 ICRP tissue weights) depending on the anatomy being imaged. This is the equivalent of 0.4 to 1.6 panoramic exposures or between 1 and 5 days of per capita background radiation. This is much lower than doses for larger field of view CBCTs. When looking at a medium field of view (FOV) CBCT, the Galileos (*Sirona, Charlotte, NC*) has an effective dose of either 70 or 120 μSv depending on the exposure setting. This is the equivalent of 3 to 5 panoramic exposures (using the 2007 ICRP tissue weights) or between 9 and 16 days of average ubiquitous background radiation.

“Health care purchasers are demanding an accounting of value received for their dollars spent” [5]. When new diagnostic modalities enter the market place it is important to provide research that proves their ability to increase patient care and their benefit to society as a whole. Fryback et al[5] introduced a six stage hierarchical model of efficacy. Level 1 deals with technical efficacy such as physical characteristics. Early studies of CBCT concentrated in this area. The second level deals with diagnostic accuracy efficacy such as sensitivity, specificity and receiver operating characteristics. Multiple studies in this area have been conducted for CBCT. The third level is where diagnostic thinking efficacy is studied. This pertains to whether there was a change in the clinician’s thinking or approach in the diagnostic decision given new information. While there are many factors that contribute to the overall patient care, this has been used as a proxy for measuring the impact on the

patient. There are limited studies concerning how CBCT has changed the diagnosis when compared to conventional radiographs and more are needed in this area. Level 4 deals with therapeutic efficacy such as the percentage of time a clinician's treatment plan changed after being given new information. The percentage of time that a procedure was avoided due to this additional information is also of interest. There are very few studies concerning CBCT at this level of diagnostic research. Level 5 is concerned with patient outcome efficacy and at the present time there is only one limited study in this area[6]. Level 6 is the societal effect of the modality or how this modality benefits society as a whole and it will be some time before research concerning CBCT will be conducted in this area. Higher order investigations are needed to be able to scientifically decide whether the use of CBCT really causes the clinician to change their treatment plan and whether there is a positive outcome based on this change. The question of whether this modality actually improves patient care is still to be determined.

New modalities are often compared to a “gold standard” or ground truth. Histopathology is considered the “gold standard” and represents the ground truth for most studies in this area. However, in order to use a “gold standard” a biopsy is required which may result in a loss of structure and/or functionality. This accompanying morbidity may be difficult to ethically justify. Therefore, studies that look at the clinical effects of using CBCT will use a “silver standard” and represents a more realistic clinical approach. This “silver standard” is composed of a panel of experts in the particular field being studied. The experts determine the ground truth for the study and the data obtained will be compared with what the experts believe to be true. A common approach to finding the ground truth instead of a “gold standard” is to use the Delphi method. In this consensus method a panel of experts will

review the data individually and arrive at a conclusion. The data is then tallied and the panel is again asked for their opinion with the conclusions of their colleagues included. This method is continued until a defined consensus is reached. It has been concluded that this method will increase the accuracy of the panel of experts and has been used in multiple disciplines including oral radiology [7].

A common statistical approach to medical and dental decision making in radiography is the receiver operating characteristics (ROC). In this method an ordinal or continuous variable must be used. This approach studies the sensitivity and the specificity of the modality in question. The researcher will then plot the sensitivity on the Y axis and one minus the specificity on the X axis and a curve is constructed between the data points. The area under the curve (Az) may be used as a comparative measure of diagnostic efficacy with larger areas indicating increased efficacy. [5, 8]

The following excerpt and attached figures 1-9 along with table 1 are reproduced with permission from the *Australian Dental Journal* and is published as DA Tyndall and H Kohltfarber[9]:

Background and Significance

In a 2008 article on cone beam computed tomography (CBCT) and dento-alveolar applications Tyndall and Rathore wrote “It is in the area of endodontic applications that the literature has proved most fruitful to date.”[10] This statement is even truer today than in 2008. A review of the literature has demonstrated that, in many cases, CBCT is more

efficacious than traditional forms of 2D imaging. Endodontic applications of CBCT include the diagnosis of periapical lesions due to pulpal inflammation, identification and localization of internal and external resorption, the detection of vertical root fractures, the visualization of accessory canals, and elucidation of the causes of non-healing endodontically treated teeth. Prior to 2008 most published articles on CBCT applications in endodontics were either case reports or in vitro studies. Since that time more well designed clinically related scholarly activity has been published. This article attempts to survey the field of CBCT applications in endodontics and provide the readers with an overview of what has been found. The authors hope that this knowledge will form a foundation for appropriate clinical decision making with specific reference to selection criteria for the endodontic applications of CBCT.

The basis for this growing evidence of the efficacy of CBCT in endodontic applications is found in the classic studies on the limitations of 2D radiography for the detection of periapical lesions by Bender and Seltzer[1, 2]. Their studies revealed that in order for a lesion to be visible radiographically, the cortical plate of bone must be involved. These findings, revealing the difficulty of detecting periapical lesions, have been consistently verified in subsequent studies since that time. A review by Huuonen and Orstavik summarized much of that research postulating that such limitations exist, partly because of the 2D nature of intraoral radiographs where clinical or biologic features may not be reflected in radiographic changes[11]. While there have been many advances in receptor and x-ray tube technologies since the first dental radiograph was taken in 1896 there have been essentially no changes in imaging geometry for the dentition since that time. Even panoramic imaging is still a form of 2D imaging and has not contributed significantly to endodontic applications of x-ray imaging. CBCT is a relatively new type of imaging geometry that more

adequately describes and illuminates the 3D anatomy of the teeth and jaws. It is no surprise that such technology has resulted in a near revolution in imaging for endodontically related dental problems.

As the review below proceeds, and the case examples are shown, the reader should be aware of the paucity of literature based on double blind clinical trials using more robust, in vivo research methodologies. Since these types of time consuming studies generally use technologies that are out of date upon publication, scholars and clinicians must base case management and selection criteria decisions on the lower level of studies extant today[5].

Current CBCT Systems and Endodontic Applications:

In 1972 Sir Godfrey Hounsfield announced an invention that used image reconstruction developed in the 1960s by Alan Cormack. This new invention eventually became known as computed tomography and it transformed medicine as well as diagnostic radiology such that three dimensional imaging is now the standard of care for trauma and pathology in the medical field. In 1998 Mozzo et al [12] introduced a new volumetric CT machine using cone beam technology useful for maxillofacial imaging. The need for three-dimensional accuracy in pre-implant planning combined with a desire to decrease the radiation dosages from conventional CT were the reasons for continuing changes in what has come to be known as cone beam computed tomography.

What follows is a review of CBCT examples currently on the market with potential for endodontic applications. Large field of view (FOV) units are from 15 – 23cm and are most useful in the assessment of maxillofacial trauma, orthodontic diagnosis and treatment

planning, TMJ analysis and pathologies of the jaws. The NewTom 3G, 5G, the iCat next generation and the Kodak 9500 are such examples of units used for craniofacial imaging. These machines may also provide smaller FOV options. Medium FOV encompasses those CBCTs with a FOV of 10-15cm which are useful for mandibulo-maxillary imaging and are used primarily for pre-implant planning and pathological conditions. Machines in this category include the Galileos by Sirona, Gendex CB-500 the NewTom VGi, 3D Accuitomo 170, and the My-Ray Skyview. Small field of view units, aka limited field of views, are becoming increasingly popular and encompass FOVs less than 10 cm with some as small as 4 x 4cm in size. These units are appropriate for dento-alveolar imaging and are most desirable for endodontic applications. Examples of CBCTs with small FOVs include but are not limited to the Kodak 9000 3D, The Veraviewepocs 3D and Accuitomo from Morita as well as the Prexion. Many of the CBCTs listed above are available in multiple fields of view and voxel sizes.

Radiation dosages have received extensive media coverage lately and are a very real concern for patients. Published values of effective dose can give a broad indication of the level of detriment to health from radiation exposure. In describing the radiation risks attributed to CBCT it can be helpful to compare effective dose to radiographic exams that are common in dentistry. Ludlow et al used the 2007 ICRP weightings and found a direct digital panoramic radiograph to be 14.2 μ Sv while a full mouth series of radiographs (FMX) with F-speed film and rectangular collimation to be 34.9 μ Sv[13]. One way to help patients further understand the doses that they are receiving is to equate dental radiographic examinations to the amount of background radiation that one receives naturally on a daily basis. According to the United Nations Scientific Committee on the Effects of Atomic Radiation, the average

worldwide background radiation is about 2.4 mSv (2400 μ Sv) per year or approximately 6.7 μ Sv a day. Therefore, a panoramic radiograph would equate to just over two days of background radiation while the FMX, described above would be equivalent to 5.2 days of background radiation. CBCT dosages vary considerably based on the field of view, the exposure beam type (pulsed vs. continuous), technique settings (mAs, kVp), beam geometry and the number of basis projections. The literature also varies depending on whether the 1990 or the 2007 ICRP weighting factors are used. Table 1 gives the effective doses of several small volume CBCTs using the 2007 ICRP weighting factors broken down by panoramic and daily per capita background radiation doses. The Somatom 64 multidetector CT (MDCT) used in medicine is provided as a comparison. Although there is a reduction in dose, it is important to follow the principles of ALARA (As Low As Reasonably Achievable). The overall diagnostic benefit to the patient must outweigh the radiation risks of receiving the exam.

Several recent investigations have demonstrated the accuracy of CBCT and are briefly summarized below. Cone beam CT allows for an accurate three dimensional representation of the scanned area. Geometric accuracy has been proven since the introduction of the CBCT[12]. Kobayashi et al [14] compared limited volume CBCT to spiral CT in measuring mandibular “lesions” made in cadaver mandibles. Their data showed that limited volume CBCT could measure distances accurately. These findings agreed with a study by Lascalea et al [15] that analyzed the accuracy of linear measurements obtained by CBCT to those of digital calipers in eight dry skulls. They found that the measurements between anatomical sites of the facial area taken with CBCT were statistically similar to actual measurements. They concluded that measurements could reliably be made with

CBCT. An in-vivo study further validated the accuracy of linear measurements as well as volumetric measurements in cone beam CT by conducting two consecutive experiments with defects of known sizes. Pinsky et al [16] first used a cast acrylic block with holes of various sizes and then used a human mandible with 21 engineered simulated defects. They found that the mean linear accuracy was smaller than 0.1mm in the acrylic block and less than 0.3mm in the mandible. Using a voxel size of 0.2mm, they observed that the overall measurements were either less than or equal to two voxels. They further concluded that CBCT errors are small and not clinically significant. One study investigated the accuracy of CBCT and intraoral digital radiographs in the detection of bony and infrabony defects. The study found that CBCT had an overall more accurate assessment than digital intraoral radiographs in detecting both types of defects[17].

Summary of Current Literature

There are many reports in the literature of the benefits of CBCT particularly in endodontics. Endodontic applications include localization and detection of broken instruments, root canal treated teeth with continued symptoms, root resorption, root fractures, understanding canal morphology, trauma, detection of periapical lesions and the extent of extruded root canal material. The technology has been widely accepted and is now being used for research and clinical purposes.

Patients with endodontic problems can pose a serious challenge in terms of diagnosis and treatment planning. The exact problem is often hard to discern when a patient may have symptoms without any radiographic signs of further periapical disease. It is important to

correctly identify the problem and plan accordingly for reasons discussed above[1, 2]. There are multiple limitations to two dimensional radiographs such as superimposition of three dimensional anatomy as well as possible exposure or geometric errors[3]. Tyndall et al [10] found CBCT superior for almost all endodontically related uses when compared to conventional 2D radiographic surveys. A study by Sanfelice and colleagues [18] used CBCT instead of histological sectioning to compare four different instruments used to flare the cervical third of a root. A clinical study by Cotton et al [19] provided case examples of various applications of a high resolution limited CBCT in endodontics. It proved the usefulness of three dimensional imaging in detecting a missed canal in a root canal treated tooth, identification of root fractures, pathological conditions that were not of endodontic origin, the extent, type and prognosis for root resorption lesions as well as the assessment of anatomy in close proximity to root apices. A case report by Tsurumachi and Honda [20] used CBCT to help in the detection, localization and surgical pre-planning of a broken instrument. They felt that while periapical films give good detail mesiodistally they are inadequate to give detail in the buccolingual dimension. Therefore, it was concluded that CBCT helped not only in detecting the exact position of the instrument but also led to a safer surgical approach. Limitations of viewing structures was also noted by Low et al [21]who felt that the maxillary molars in particular were difficult to assess with two dimensional films. When comparing the diagnosis of periapical lesions, anatomical relationships and pre-planning for apical surgeries with CBCT versus periapical radiography, it was discovered that CBCT revealed 34% more lesions than periapical radiographs. They were also able to appreciate expansion of the lesions into the maxillary sinuses, thickening of the sinus mucosa, missed canals as well as apicomarginal communications much easier with CBCT. This finding is similar to the

study conducted by Lofthag-Hansen et al [22] which found 38% more apical lesions on CBCT than with two periapical radiographs taken at 10 degree horizontal angles. This study also found sinus membrane thickening more often with CBCT than with periapical films. In fact, CBCT revealed additional relevant information in 32 of the 46 cases involved. It further showed that lesions with a mean mesial distal width of 2.8mm and a mean buccolingual dimension of 4.4mm were not detected on periapical radiographs but were noticed on CBCT. The impact of three dimensional imaging was evaluated using computed tomography in the diagnosis and treatment planning of incompletely healed root canals[11]. It was discovered that of the 39 teeth observed, 30 had a second mesiobuccal (MB2) canal present and 27 of these MB2 canals had been missed and remained unfilled. 22 of the 27 teeth with missed canals had periapical lesions. The authors felt that knowledge of the size and extent of periapical lesions, buccal and lingual cortices as well as the maxillary sinus boundaries were important when deciding on a surgical approach. This potentially significant information could be provided by CBCT.

Root fractures are quite difficult to detect on two dimensional radiographs unless the x-ray beam passes directly along the fracture line[23]. The clinician must rely on a set of symptoms that cast suspicion on a diagnosis of a fractured tooth. It becomes a challenge to confidently recommend a course of action when one is not completely sure of the exact diagnosis. A systematic review conducted by Tsesis and coworkers [24] evaluated articles on vertical root fractures from 1971 – January 2010 in order to further characterize their appearance on radiographs. The most frequent radiographic feature noted in the various articles was a combination of periapical/perilateral radiolucencies that they referred to as a halo sign. However, they concluded that evidence based data on the clinical and radiographic

signs leading to a diagnosis of vertical root fracture was lacking. CBCT research addressing the problem of horizontal and vertical root fractures continue to be carried out as clinicians search for a better way to diagnose these confusing entities. Bornstein et al [25] observed 44 permanent teeth in 38 patients that sustained trauma resulting in horizontal root fractured teeth. It compared periapical and occlusal films with limited volume CBCT to evaluate the location and angulation of the fracture line. The study found that horizontal root fractures could be easily seen in all 44 teeth with the CBCT. A case study by Orhan and colleagues [26] discussed an instance where CBCT was able to determine whether root resorption was involved with a horizontally fractured front tooth. They used three dimensional imaging and found that no periradicular pathosis or resorption was present. CBCT was instrumental in diagnosing the tooth as a spontaneously healed root fracture and the patient was able to retain his tooth without further treatment. Research by Hassan and Metska et al [27] focused on the comparison of vertical root fracture (VRF) detection on CBCTs and periapical radiographs. They were specifically assessing the effect of root canal material on the ability of the modalities to detect these types of fractures. They found the overall accuracy of CBCT scans to be superior to periapical radiographs. However, they did note that the detection of VRFs was limited by the contrast to noise ratio as well as the voxel size which was 0.25mm in their study. It was also discovered that the presence of root canal material did not affect the overall accuracy of CBCTs but it did reduce its specificity. The authors postulated that the beam hardening or streak artifacts observed with root canal materials may have made the observers less confident in diagnosing the vertical root fractures. Various thicknesses of vertical root fractures were evaluated in a study by Ozer et al [23] that used a limited volume CBCT and a voxel size of 0.125mm to observe fractures down to 0.2mm. It was concluded that CBCT

was statistically superior to digital radiography for all thicknesses of VRFs noted in the study.

Three dimensional imaging has many additional benefits including characterization of lesions for pathological purposes. CBCT is a potentially useful tool in the identification of margins for surgical biopsies as well as in differential diagnoses. However, a CBCT is unable to give a clinician a definitive diagnosis the way that a histological biopsy can. Concerns over previous papers that suggested that CBCTs can be used instead of histopathology to differentiate radicular cysts from granulomas led Rosenberg et al [28] to publish a study to evaluate the truth behind these claims. This study included 45 patients and had two radiologist and two pathologists independently examine the samples. It observed the consistency of the radiology reports and found a weak inter-rater reliability ($\kappa=0.14$) while the inter-rater reliability of the pathologists was quite strong ($\kappa=0.79$). The study compared the two radiologist's findings with the gold standard and found that their accuracy was 51% for the first radiologist and 61% for the second. Therefore, it was concluded that histopathology is still the gold standard for differentiating a radicular cyst from a granuloma. CBCT has improved many areas of endodontics but for this particular diagnostic task a biopsy is still necessary.

Identification of root canals and root canal morphology is another area where CBCT has been shown to be superior to 2D imaging. A paper by Weine et al [29] reported the prevalence of MB2 canals in maxillary first molars. They found that 51.5% of maxillary first molars exhibit some type of MB2 canal. They further explain that it is often difficult to detect these canals ahead of time with intraoral radiographs and can be considered a possible cause in unexplained failure of treatment. Degerness et al [30] studied the dimensions, anatomy and

morphology of the mesiobuccal root canal system in maxillary molars by sectioning and describing 150 teeth. Their study resulted in reporting a higher incidence of canals in the mesiobuccal root of the first maxillary molars than in the previous study. They found that 20% of their sample had one canal, 79.8% had two canals and 1.1% had three canals. They concluded that a thorough understanding of the complicated root canal system in maxillary molars would improve endodontic therapy. Kottoor and colleagues [31] presented a case report of unusual anatomy in the maxillary first molar with seven root canals that were diagnosed with surgical operating microscopes and confirmed with CBCT. The authors felt that the unusual anatomy was proven with three dimensional imaging and led to the successful case management. The accuracy of CBCT and other modalities in identifying root canal morphology have been compared to the modified canal staining and clearing technique by Neelakanton and coworkers [32]. They analyzed 95 teeth to identify the number of canals found with each method. CBCT was able to correctly identify the canals 99.71% of the time. The inter-rater agreement between CBCT and the modified canal staining and clearing technique was 99% for the five observers (three endodontists and two radiologists) and only 82% for digital radiographs. In fact, observers missed two or more canals with digital radiographs in 23.8% of teeth. Further validation of CBCT as a tool in exploring the root canal anatomy was observed in the study by Michetti et al [33]. This study compared CBCT with histological sections viewed under an optical microscope. They found on average a strong to very strong correlation between the CBCT and the histological sections (r area = 0.928 and r diameter = 0.890). The authors concluded that CBCT was a reliable and noninvasive way to view the root canal anatomy.

The presence of periapical lesions can determine the treatment outcome of a tooth. Cone beam CT has proven to be beneficial in diagnosing periapical lesions that intraoral periapical radiographs failed to show. A study by Sjögren et al [34] found that the success rate for teeth that have vital or nonvital pulps but no periapical lesion is 96%. However, cases that have a necrotic pulp and a periapical lesion have a success rate of 86% and that drops to 62% for root-filled teeth with periapical radiolucencies. The absence of periapical lesions on intraoral radiographs does not mean that the apices are free of lesions. CBCT has been shown to diagnose these lesions better because there is not a superimposition of cortical bone over the lesion[35]. Stavropoulos and Wenzel [36] studied the accuracy of CBCT, digital intraoral and conventional films in detecting periapical lesions in pig jaws. They were able to detect artificially created bone defects statistically more often with CBCT than with the other two modalities. They postulated that the low sensitivity of the intraoral modalities was due to the fact that the artificially created defects were limited to the cancellous bone. This agrees with previous studies [1, 2]. Nakata et al [37] presented a case report of a patient with poorly localized pain in the right maxillary molar region. Panoramic and intraoral radiographs were unable to determine the cause of the patient's pain. A small volume CBCT was able to reveal a 4 x 4mm lesion on the distobuccal root of a previously root canal treated maxillary first molar. The author further explained the necessity of knowing the correct pathological conditions, anatomical structures and positional relationships in order to give the best quality of endodontic treatment. Paula-Silva and colleagues [38] evaluated periapical lesions with periapical radiographs and CBCT and compared them to histopathological findings as the gold standard. They found that apical periodontitis was discovered in 71% of roots with periapical radiographs, 84% with CBCT and 93% with histology. They found an overall

accuracy of 92% with CBCT when considering sensitivity, specificity, positive predictive values and negative predictive values. It is possible that root-filled teeth once thought to have healed by intraoral radiographic standards in fact still have periapical lesions when viewed with CBCT. This technology may change our view of what constitutes a 'healed' tooth and the length of time in which teeth are evaluated post treatment[35, 39].

The detection and management of internal and external root resorption can be a challenging task and one in which CBCT is well suited. The knowledge gained from three dimensional imaging can help in diagnosing the size of the defect as well as its proximity to the root canals and ultimately the prognosis of the tooth. Two studies by S. Patel et al [6, 40] pay particular attention to the use of CBCT for this purpose. In 2007 the author discussed two cases where CBCT helped with diagnosing the true extent and management of external cervical resorption. It was noted that angled periapical radiographs using the parallax technique can be helpful in trying to determine the location of a lesion as well as whether it is internal root resorption or external root resorption but is unable to help determine the depth or extent of such lesions. On radiographs internal root resorption is noted as a smooth, well-defined radiolucency that may be spindle shaped and contiguous with the root canal. The fact that the lesion does not change positions when viewed on two angled radiographs is also characteristic of internal root resorption. External root resorption will not appear to be as well-defined and the unaltered outline of the root canal may be observed through the defect. These lesions will appear to change positions when viewed on the two angled periapical radiographs. The author felt that CBCT not only showed the full extent of the lesions but also allowed the clinician to be more confident in their treatment approach as well as give them a more realistic prognosis for each tooth in question. Two years later their second study was

reported and evaluated both internal and external root resorption cases and compared them to a control group examining the ability of CBCT to accurately detect lesions. More importantly it was the first study to examine the impact that CBCT made in determining the correct treatment plan for the patient. CBCT was found to have perfect accuracy in detecting and diagnosing the different resorptive lesions when compared to periapical radiographs. The observer's ability to choose the correct management of the lesion was 60% for intraoral radiographs and 80% for CBCT when compared to a consensus committee. The study had a small sample size but dealt with a difficult diagnostic task. Clinical studies of this nature must also depend on a silver standard in order to preserve the tooth in question. However, this report marked the beginning for studies that wish to move beyond the question of accuracy and try to determine the actual benefit of this technology to the patient. Scarfe et al[3] has stated that "the absence of prospective randomized clinical trials underlines the need for further research on the treatment outcomes related to CBCT applications in endodontic practice."

Selection Criteria

The American Association of Endodontics and the American Academy of Oral and Maxillofacial Radiology have recently released a joint position paper [41] discussing the use of CBCT in endodontics. The findings of both organizations are reasonably applied across the globe and will be summarized herein.

It was suggested that small field of view units are better suited to endodontics because their inherent small voxel sizes result in higher resolution images (down to 0.076mm) and

less radiation dosages than the larger field of view options. An important consideration is patient selection criteria. CBCTs should not be used for screening purposes and not every patient needs a three dimensional image. Cases should be chosen on an individual basis depending on the patient's history, clinical examination and inability to obtain adequate diagnostic information from two dimensional images. As stated previously it is important that the diagnostic benefit to the patient exceed the risk of radiation. CBCT should be limited to difficult endodontic cases such as:

- Identification of accessory canals, complex morphology, root canal system anomalies including determination of root curvature, such as in the case of maxillary molars.
- Cases of contradictory or nonspecific signs and symptoms
- Poorly localized symptoms associated with a previously treated tooth
- Anatomic superimposition unresolved with two dimensional imaging
- Diagnosis of non-endodontic pathology
- Assessment of intra or post-operative complications
- Diagnosis of dento-alveolar trauma
- Localization of root resorption
- Pre-surgical planning for apical surgeries as well as for dental implants.

Remarkable advances are taking place in 3D imaging technology of the craniofacial structures. The literature appears to support the widespread use of CBCT for multiple endodontic applications and CBCT has improved the clinician's ability to diagnose and treat endodontically related problems. Care must be taken in the judicious use of CBCT for endodontic applications considering the additional risks of using, or not using, this 3D

imaging technology. CBCT should be limited to those applications where the clinical and scientific literature has demonstrated increased efficacy over 2D imaging.

End copyright material from the *Australian Dental Journal*

Study Aims:

1. Determine the potential diagnostic benefit in detecting periapical lesions associated with incompletely healed root canals with the addition of three dimensional imaging.

Clinicians who take a three dimensional volume almost always have already taken a two dimensional radiograph. Therefore, it is more clinically relevant to compare modality A with modality A+B.

The specific null hypothesis that will be tested is that there is no difference between the two modalities in lesion detection.

2. Determine the effect of a limited volume CBCT in treatment planning. Specifically this study will compare the differences between treatment planning with a two dimensional image versus a two dimensional image with the addition of a three dimensional volume to see whether there is a change in treatment planning when using these two imaging modalities. The percentage of time that a change takes place in the treatment plan given the new information is of particular interest. It will be thought-provoking to observe whether the additional information leads to more treatment or less treatment for the patient. There is limited research in this area and it is important to see how the use of three dimensional

imaging really impacts the final treatment for patients. There is no reason to use a modality if it does not translate into an improvement in the care of the patient.

The null hypothesis that will be tested is that there is no difference between the two modalities in treatment planning.

3. Determine whether three dimensional visualization increases clinicians confidence in their treatment plan when compared to two dimensional radiographs. In order for a clinician to be able to suggest a type of treatment they must be confident in what they can visualize and believe that their proposed treatment plan will benefit the patient. When a clinician is unsure of their treatment plan, they are not able to educate the patient on why a particular treatment is recommended and this can decrease patient acceptance of the proposed treatment. There are few studies in this area as well but it is important to discover whether the limited volume CBCT can increase the clinician's confidence and therefore improve patient care.

The null hypothesis that will be tested is that there is no difference in the clinician's treatment planning confidence.

Material and Methods:

The study consisted of a diagnostic comparison of two imaging modalities: periapical radiographs alone (modality A) and periapical radiographs with the addition of a cone beam CT (modality A+B). Institutional Review Board approval (IRB #10-1238) was obtained

from the University of North Carolina for the study. The sample consisted of 19 individuals with 20 teeth who presented to the graduate endodontic clinic with root canal treated teeth that had periapical lesions and associated symptomatology between August 2010 and May 2011. These patients were sent to radiology to obtain a cone beam CT in order to better characterize their radiographic presentations. Each patient signed consent and agreed to the study before the images were taken. The periapical radiographs were taken with either Gendex photostimulable phosphor plates or Visualix eHD charged-coupled device (CCD) sensor (Gendex Dental Systems, 1910 North Penn Road Hatfield, PA 19440) or Schick CDR Elite CCD (Schick Technologies, Inc. 30-30 47th Avenue, Suite 500, Long Island City, NY 11101). The three dimensional volumes were obtained with the Kodak 9000 CBCT (KODAK Dental Systems, Carestream Health Rochester NY, USA/Distributed exclusively in the USA by PracticeWorks, Atlanta, GA, USA) with a field of view of 50 x 38mm and a 0.076mm voxel size. An additional 20 cases without suspected periapical lesions were obtained from a records review of Kodak 9000 volumes for a total original sample size of 40 teeth. The clinicians had access to all of the volumes and were able to use them immediately for the benefit of the patients. Each of the volumes obtained from the records review had already been interpreted and used for treatment purposes. The cases were randomized. The periapical radiographs that were used to make the original patient diagnosis were exported from the electronic patient record at UNC School of Dentistry as jpegs. These were de-identified and resized for uniformity to 367 x 485 pixels and imported into Qualtrics (uncodum.qualtrics.com) viewing software as jpegs. Each cone beam CT volume was exported from Kodak 9000 to a server and imported into InVivo 5.1 by Anatomage (Anatomage Anatomy Imaging Software – San Jose, CA) for viewing. The volumes were

anonymized and re-oriented to facilitate viewing of the tooth in question. They were saved as a full .inv file and saved on a Lenovo W510 computer with a calibrated Lenovo think vision 17" monitor. The monitor resolution was set at 1024 x 768. The forty periapical radiographs and volumes were viewed by observers in a room with low light conditions on the same monitor.

Four endodontic residents were recruited as observers - One third year, two second years and one first year resident. A six- month washout period was observed between obtaining the last sample patient and the viewing of the radiographs in order to decrease the resident's bias if they had previously viewed the images. They were each given calibrated information on the viewing of the periapical radiographs in Qualtrics and the volumes in InVivo. The periapical radiographs were the ones used clinically to make the original diagnosis and the three dimensional volume could be manipulated in any fashion that would be used clinically. Three different sessions were given two weeks apart. The periapical radiographs were viewed alone in the first session. The second session consisted of viewing the periapical radiographs with the addition of the three dimensional volumes. The last session was a sampling of ten periapical radiographs alone and ten periapical radiographs with volumes in order to test intra-observer variability. The first question was then compared to the ground truth or silver standard which consisted of a panel of three experts – two radiology faculty members and one endodontic faculty member at UNC with more than ten years of experience.

A modified Delphi method was used in order to come to an agreement with the sample and control population. The expert panel viewed the periapical radiographs with the volumes on the same monitor and with the same atmosphere as the resident observers. They

observed the cases the first time without the knowledge of their peer's answers. Any cases where the panel members disagreed resulted in a second reading with the knowledge of their colleagues answer choices. The third viewing consisted of the expert panel members meeting and coming to a final agreement on the remaining cases. A periapical lesion aka apical rarefying osteitis was defined by the panel of experts as a loss of lamina dura with a tear drop or ovoid shaped radiolucency extending beyond the periodontal ligament space and into the basal bone.

The observers were presented with three questions with four to five answer options for each of the forty cases. The first question is based on a five point Likert scale and the observers were calibrated in order to utilize the full spectrum of available answers. The observer's answers were then compared to the ground truth and a Receiver Operating Characteristic (ROC) was generated with the area under the curve (Az) compared for significance using Univariate analysis of variance. Question two had four answer options which represented four different categories of treatment from no treatment to extraction. Due to multiple factors involved in treatment planning this question was assessed as to a change in treatment plan based on the addition of three-dimensional information (yes/no) and the directionality of that change. The third question was on a five point scale and was also assessed for a change in the clinician's confidence (yes/no) and the directionality of that change.

The questions and answer options were as follows:

1. Is there a periapical lesion present at the apices of tooth # X?

1= A lesion is definitely not present

2= A lesion is probably not present

3= Unsure

4= A lesion is probably present

5= A lesion is definitely present

2. What is your proposed treatment plan for tooth #X based on the image(s) that you have?

1=No treatment –observe

2=Nonsurgical retreatment

3=Surgical retreatment

4=Extraction

3. What is your confidence level in your proposed treatment plan for tooth #X?

1=Definitely not confident

2=Not confident

3=Somewhat confident

4=Confident

5=Very confident

Results

The panel of experts found a total of 23 positive cases and 17 negative cases. For the first question as to whether the lesion was present or not, answer choice 1 and 2 was assigned as a negative case or lesion absent. Answer choice 3, 4 and 5 was assigned as a positive case or lesion present. The “unsure” option was chosen to represent a positive case based on the assumptions of the ROC software. The ROC analysis was performed by Eng J. ROC analysis: web-based calculator for ROC curves. Baltimore: Johns Hopkins University (<http://www.rad.jhmi.edu/jeng/javarad/roc/JROCFITi.html>) powered by JROCFIT 1.0.2 and JLABROC4 1.0.1 by John Eng, MD. These are translations of ROCFIT and LABROC4 which are programs developed by Charles Metz and colleagues at the University of Chicago.

The area under the curve (Az) for each observer was calculated and is shown in table 2. There is a consistent increase in the Az for each observer with the addition of the cone beam CT. A Univariate analysis of variance was conducted (table 3) and showed that there was a statistically significant increase in the diagnoses of periapical lesions ($p=.006$) with the addition of three dimensional imaging. No statistically significant difference was noted between observers ($p=0.135$) and each observer’s ability to detect lesions increased significantly. Table 4 shows the summary statistics of each observer by modality. There was an increase amongst all of the observers in the correct detection of lesions and this is shown by the increase in cases correct when compared to the ground truth.

Observer one was able to increase the number of correct cases from 30 to 36 out of the forty cases and the accuracy went from 75% to 90% with the use of the additional information provided by the limited field of view volume. Sensitivity increased from 78.3%

to 87%, specificity increased from 70.6% to 94.1% and the Az score also increased from 0.8 (good) to 0.936 (very good). Observer one decreased the number of false positives by four cases and the number of false negatives by two cases. Observer two and three both increased their number of correct cases from 27 to 30 and their accuracy from 67.5% to 75% with the additional information provided by the scan. However, observer two had a slight decrease in sensitivity from 82.6% to 78.3% while the specificity increased from 47.1% to 70.6%. This change reflected the fact that while one more false negative occurred with cone beam CT there was a decrease of four false positive cases. This caused the Az score to increase significantly from 0.76 to 0.913 as more cases without lesions were accurately diagnosed. Observer three was able to accurately detect disease in both modalities. The observer's sensitivity increased from 91.3 % to 95.7% and the specificity increased from 35.3% to 47.1%. This observer had a high number of false positives but was able to decrease that number slightly with the help of additional information. This is reflected in the Az scores increase from 0.81 to 0.881. Observer four increased the number of correct cases from 26 to 35 out of the forty cases with the use of three-dimensional imaging. The accuracy increased from 65% to 87.5%, sensitivity increased from 82.6% to 95.7% and specificity increased from 41.2% to 76.5%. The additional information from cone beam CT helped this observer to be able to decrease the number of false positives by 6 cases and the number of false negatives by 3 cases. The Az score for lesion detection with the periapical radiographs alone was 0.647 which is modestly better than chance (Az score of 0.5) and increased to an Az score of 0.905 which is considered to be a very good Az score with the help of additional imaging.

The overall treatment plan changed with the addition of three dimensional imaging in approximately 36% of the cases. Table 5 demonstrates the changes in treatment plan and directionality for each modality. The treatment plan was changed for the positive cases or teeth with lesions in 33% of the cases with the addition of CBCT. The treatment plan changed for negative cases or teeth without lesions in 40% of the control population. A Fisher's exact test was used to view the statistical significance of treatment plan directionality for the sample and the control group and a chi-square was performed on the entire population to detect statistical significance. The control group demonstrated a statistically significant ($p < 0.0001$) decrease in treatment with the addition of the CBCT volume. The sample population showed a trend toward more treatment with the additional imaging. However, this was not statistically significant ($p = 0.44$). There was not a statistically significant change in the directionality of treatment planning when all cases were considered ($p = 0.17$). Tables 6 and 7 reveal the changes in treatment plans for both the control and sample population based on observers.

The clinician's confidence in the treatment plan between modalities changed in approximately 66% of all cases with a decrease in confidence in 35% and an increase in confidence in 31% of treatment plans. Table 8 reflects these findings and shows the clinician's change in their treatment plan for positive, negative and all cases. The results are broken down by observers for all cases in table 9. There is a slight increase in the clinician's confidence in their treatment plans between modalities for observers 1 and 2. However, a decrease in confidence is noted for observers 3 and 4.

No statistically significant difference was noted between observers for the detection of periapical lesions with the Univariate analysis of variance. However, for inter-observer

agreement kappa was calculated for question one -lesion detection (table 10) and question two -treatment planning (table 11). The kappa for inter-rater agreement was $k=0.44$ showing moderate agreement among observers for lesion detection. It is interesting to note that observer one and two had substantial agreement as did observer three and four. However, the two pairs of observers had only moderate agreement among themselves. The kappa for inter-rater agreement was $k=0.38$ showing fair agreement among observers for the treatment planning question. Once again observer one and two had substantial agreement with each other as did observer two and four. However, observer three and four had only slight agreement. This is most likely due to the fact that observer three had a much lower threshold for treating patients and each case resulted in some type of treatment. The sample size was too small to produce a kappa for the intra-observer agreement. Therefore, the raw percentages were obtained to determine the intra-observer agreement and are shown in table 12. The observers agreed with themselves between 70 – 85% of the time in lesion detection, between 65-85% of the time in treatment planning and 75-100% in their confidence in the treatment plans.

Discussion

In order to make this study as clinically relevant as possible it made sense to use digital periapical radiographs as the first modality and digital periapical radiographs plus a small volume CBCT as the second modality. The rationale is that most clinicians will take a periapical radiograph first and then include a cone beam CT for additional information. These modalities should be evaluated together to make the diagnosis and treatment plan. It is

interesting to note what role if any the addition of three-dimensional imaging has on the diagnosis, treatment planning and confidence of the clinician. In this study there was a statistically significant increase in the number of correct lesions detected with cone beam CT. Therefore, the null hypothesis that there is no difference between the two imaging modalities in lesion detection is rejected. These results are consistent with several other published studies[22, 36]. Sensitivity, specificity and accuracy also increased for most observers with the addition of cone beam CT. Sensitivity for observer 2 decreased slightly with the addition of three-dimensional imaging. However, the specificity, accuracy and cases correct all increased.

There was a change in treatment plans made with two dimensional imaging alone and those made with the addition of three dimensional imaging. Many factors are involved in treatment planning an individual that has a root canal treated tooth with continued symptoms. There are often signs and symptoms that are reported by the patient which may not be visible by radiographic means alone. Endodontist rely not only on radiographic changes but also on palpation, percussion, intra-oral clinical findings etc. The patient will also help in the decision making process for the final treatment plan of any tooth in their mouth. While it was important to establish whether there was a change from a purely radiographic perspective, it is beyond the scope of this study to state whether the proposed treatment is the “correct” treatment for the patient. Therefore, it was only noted if there was a change in the treatment plan and the directionality of that change. Four treatment options were given for each case and are similar to those used in a study by Dechouniotis et al [42] in which certain categories of treatment were used such as “No Therapy, Wait and See, Nonsurgical Retreatment,

Surgical Retreatment and Extraction”. Our current study chose to collapse these five categories into four by combining the – No Treatment – and Wait and See answer choices.

There was an average change of approximately one third of the treatment plans when additional information from three-dimensional radiographs was given to the endodontic residents. The control and sample populations were also studied independently and it was found that there was a statistically significant decrease in treatment that was proposed for the control group with the addition of three-dimensional imaging and therefore we reject the null hypothesis that there is no difference between the two modalities in treatment planning. It is postulated that this decrease in treatment is due to the fact that suspected lesions were shown to be absent in this population and therefore the previously proposed treatment plan based on two-dimensional imaging alone was changed to either no treatment or less treatment for the patient. This theory finds merit in the fact that a decrease in false positives which resulted in an increase in specificity was found for all observers in the diagnosis of periapical lesions noted in the first aim of the study. Likewise, there was a trend to increase treatment among the sample group. One theory is that the lesion was not detected on the periapical radiograph but was noted with the addition of the limited volume and therefore caused treatment to be planned where no previous treatment had been planned. This would agree with the generalized increase in sensitivity or decrease in false negatives that were observed in the first part of the study. Therefore, it appears that the results of aim one and two of this study support each other in their findings.

While the clinician’s correctly diagnosed more lesions and appeared to render less treatment to the control group and more to the sample group with the addition of CBCT, they ironically had less confidence in their treatment plans (table 8). However, this was not

statistically significant and therefore we must accept the null hypothesis that there is no difference in the clinician's confidence between treatment plans with adding three-dimensional imaging. When confidence is broken down by observer, (table 9) it can be theorized that education and experience with radiographic interpretation using cone beam CT may have affected the outcome of this study. Each endodontic resident that was used as an observer had at least some introduction to cone beam CT. A basic radiology interpretation class is given to all residents at UNC Chapel Hill and each endodontic resident had at least worked with a few patient cases taken on the Kodak 9000. Observer one is a third year resident and observer two is a second year resident who has performed quite a few cases with the addition of a limited field of view CBCT. On the contrary observer three is a second year resident and observer four is a first year resident who has not used the cone beam CT as much as the first two observers. One theory is that the amount of education and ability to correctly interpret what one can see will affect the confidence of the individual. This theory that education makes a difference in the interpretation of radiographs appears to agree with one study by McCaul et al [43] that looked at the effect of specialization and experience with decision making and treatment planning in endodontics. Overall, observer one and two were slightly more confident in their treatment plans with the addition of three-dimensional imaging while observer three and four were less confident in their treatment plans that were made with additional imaging. It can be hard to interpret a case correctly when one is not sure of what they are seeing. There are many things that can cause confusion with three-dimensional imaging such as beam hardening from the previous endodontic filling and noise that is inherent in a cone beam CT scan. It would be interesting to perform a study similar to this one, then put the observers through a more complete interpretation course looking at

periapical lesions and then complete this type of a study once more to see if there is an increase in the confidence of their treatment plans when they are better able to interpret what it is that they are seeing. More studies are needed in this area and it may be prudent to consult with a local oral and maxillofacial radiologist if the clinician is experiencing difficulty in interpreting the CBCT scan.

A study by Rushton et al. [44] looked at the effect of coronal tooth structure in the diagnosis of apical pathologies. The study findings showed that the status of the coronal tooth structure had an impact on the diagnostic accuracy of inexperienced observers and the author felt that radiology training was needed earlier in a student's dental career. The ability for observers to view the coronal tooth structure in the radiographs in this study may be viewed as a bias toward lesion detection. However, the use of the periapical radiographs in both modalities decreases this bias and leaves this argument unsubstantiated. It is also important to note that radiologists rarely comment on the coronal aspect of teeth that have been endodontically treated and have metallic restorations due to the effect of beam hardening. Therefore, the author felt that there was no need to mask the coronal aspect of the teeth in either the periapical radiographs or the three-dimensional volumes.

In this study a combination of PSP and CCD radiographs were used for the periapical radiographs. The images were generated from either the graduate endodontic clinic or the radiology clinic and each clinic used the radiographic system that was available to them. Literature was reviewed to determine if there was a statistically significant difference based on the imaging systems for the task of observing periapical lesions. A study performed by Wallace et al[45] looked at the diagnostic efficacy of different imaging systems for the detection of simulated periapical lesions. Their study found that there was not a statistically

significant difference between the digital imaging modalities. Therefore, a combination of PSP plates and CCDs could be used as modality one in the present study. It is also important to note that modality two also incorporated these same radiographs with the addition of cone beam CT and removes any bias that the reader may feel is attached to one digital intra oral modality over the other.

A bias in the study may exist due to the fact that the study took place in an academic setting and the observers may have previously worked with the patient cases or had access to them. Therefore, a six month washout period was used between obtaining the last sample and the viewing of the experiment in order to minimize this bias. Another potential source of bias may exist because only the most challenging endodontic cases are the ones usually sent to obtain additional imaging. This could have resulted in the observers “detecting” more lesions because additional imaging was present. In order to decrease this bias a “control” sample without suspected periapical pathosis was obtained through a records review process and the final control population was decided by the panel of experts. Other weaknesses of the study include the small sample size and number of observers as well as the inability to change the contrast and brightness of the two dimensional radiographs. Due to time constraints it was not possible to view these images in the electronic health record and therefore manipulate them in VixWin.

The current study revealed that diagnostic accuracy was increased with the use of three-dimensional imaging. It was also discovered that there was a change in the diagnostic thinking of the clinicians in at least one third of the cases. There does appear to be a change in the therapeutic efficacy between periapical radiographs and CBCT which was revealed by a statistically significant decrease in the proposed treatment plan for the control group. This

may have led to an avoidance of unwarranted dental treatment for this group of patients. Research to further study the effects of cone beam CT on treatment planning and clinician's confidence is needed in order to better understand the true benefit of this modality to the patient, clinician and eventually to society as a whole. Higher order research is strongly recommended in order to accurately assess the cost benefit analysis to society of this relatively new imaging device.

Conclusion

There was a statistically significant increase in the correct detection and diagnosis of periapical lesions with the addition of three-dimensional imagining. The use of the CBCT resulted in changes in treatment plans in approximately one third of all cases and a statistically significant decrease in the treatment that was proposed for the control group. However, there was a paradoxical decrease in the confidence of the clinician's treatment plans with the addition of cone beam CT. Further research is needed in order to determine if this decrease in confidence is based on the clinician's education and knowledge of radiographic interpretation with cone beam CT.

Figures

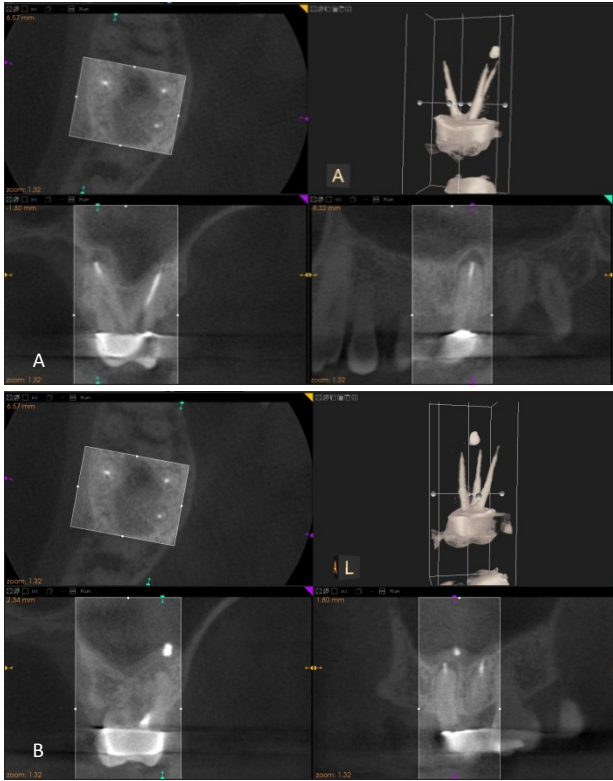


Figure1: Tooth #14 demonstrates a root canal treated tooth that had continued symptoms and was found to have an overfilled canal on the palatal root with apical rarefying osteitis (A). The mesial and buccal roots exhibiting overfilled canals with rarefying osteitis on the mesial buccal root and a widened periodontal ligament space on the distal buccal root (B). Note the root canal material located in the left maxillary sinus.

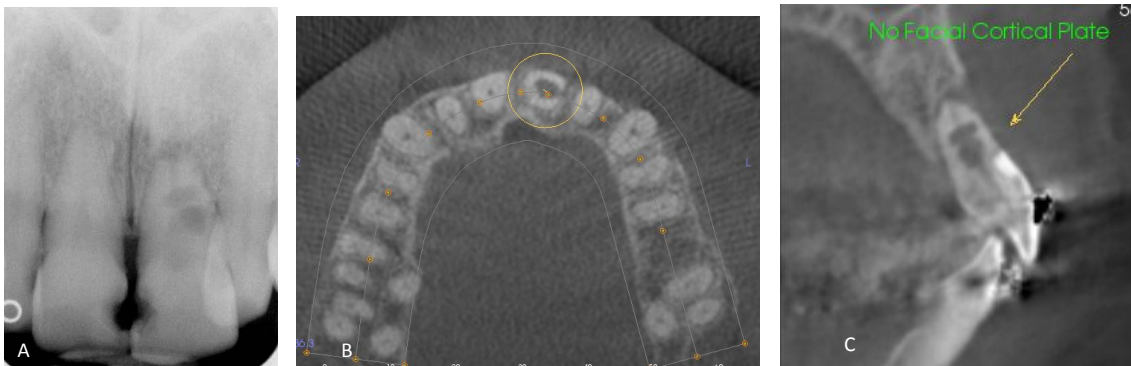


Figure 2: Periapical radiograph of tooth #9 with internal root resorption (A). The extent and location of the resorption is noted with the CBCT (B). The absence of facial cortical bone is recognized in the sagittal view of the CBCT (C) and helped to determine the treatment for this case.

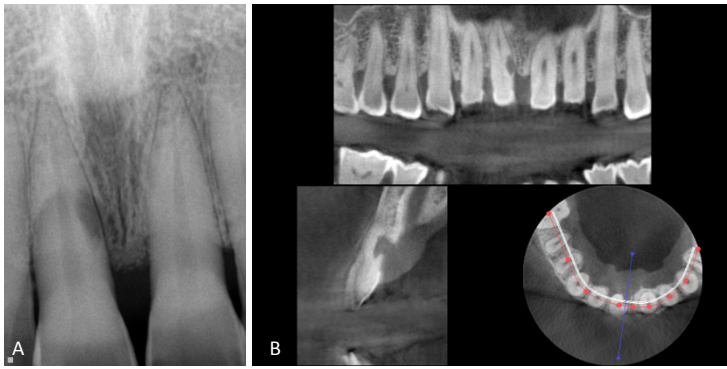


Figure 3: Periapical radiograph showing external root resorption(A). The CBCT of the tooth in question showed the exact location and extent of the lesion and guided the treatment plan (B).

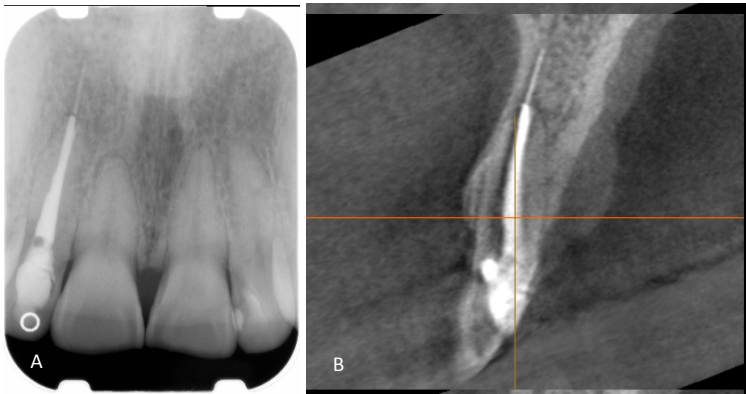

Figure 4: Periapical radiograph showing a broken file at the apices of tooth #7 (A). The CBCT helped in the diagnostic pre-planning for apical surgery by showing the exact location and measurements of the file (B).

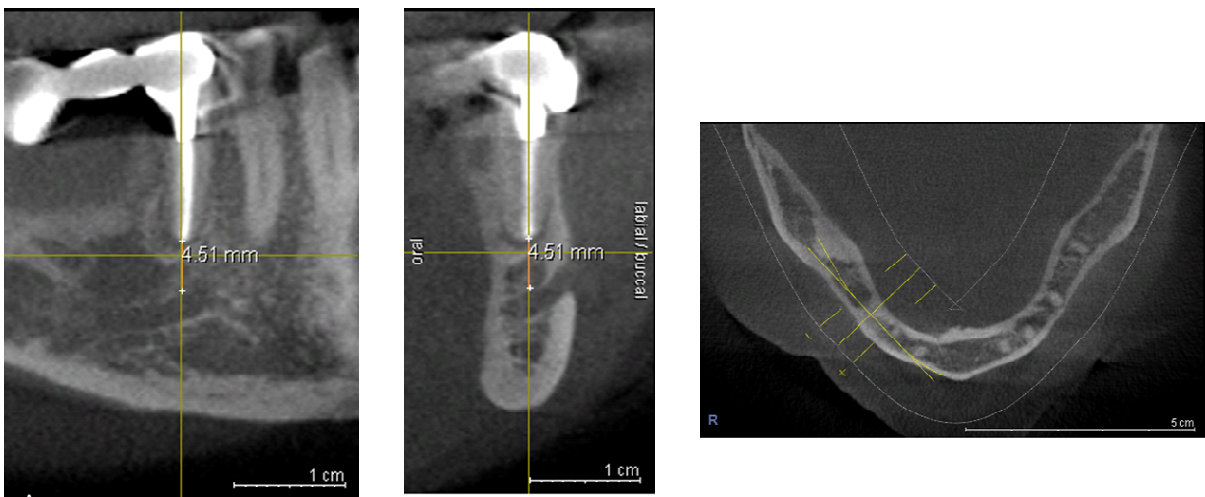


Figure 5: Example of a case where three dimensional imaging was important for the pre-planning of

an apicoectomy. CBCT aided in determining the relationship between the apices and the inferior alveolar nerve.

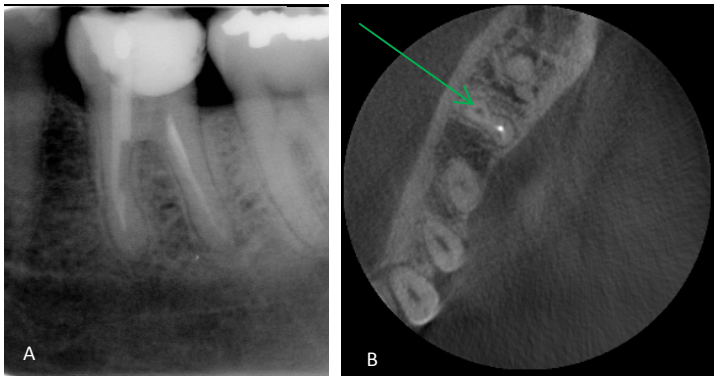

Figure 6: Periapical radiograph of a previously root canal treated tooth (#19) with continued symptoms (A). The CBCT revealed an unfilled mesiobuccal canal (B).

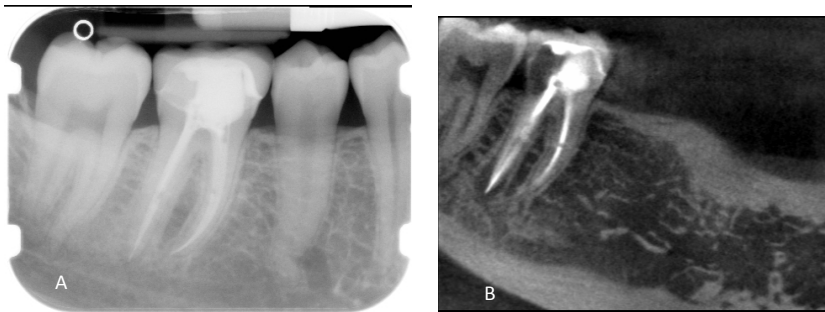


Figure 7: The periapical radiograph of a patient with a previously endodontically treated tooth who continued to have symptoms (A). The CBCT was able to reveal the presence of rarefying osteitis and an overfilled canal which could not be detected by the two dimensional radiograph (B).

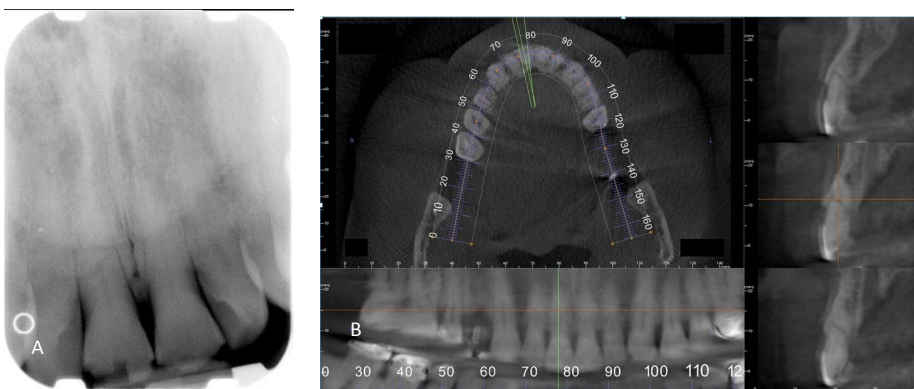


Figure 8: A periapical radiograph of the maxillary anterior teeth. Tooth #8 was treatment planned for an incisal composite from this radiograph (A). The three dimensional scan was able to show the fracture of tooth #8 without being hindered by the supra-imposition of soft tissues and lead to a more correct treatment plan (B).

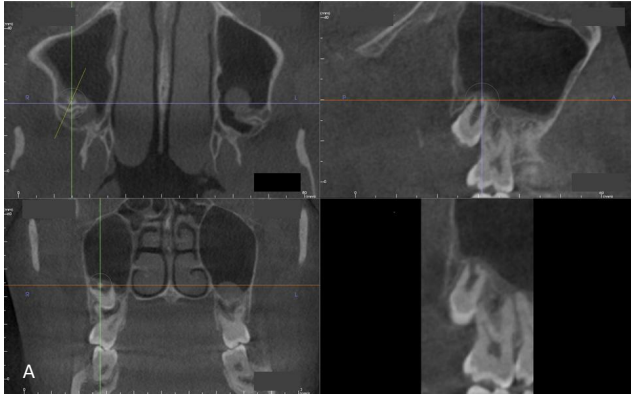


Figure 9: The unusual morphology of tooth the third molar can be observed more accurately in the three dimensional radiograph and help to identify the dilacerated root (A)

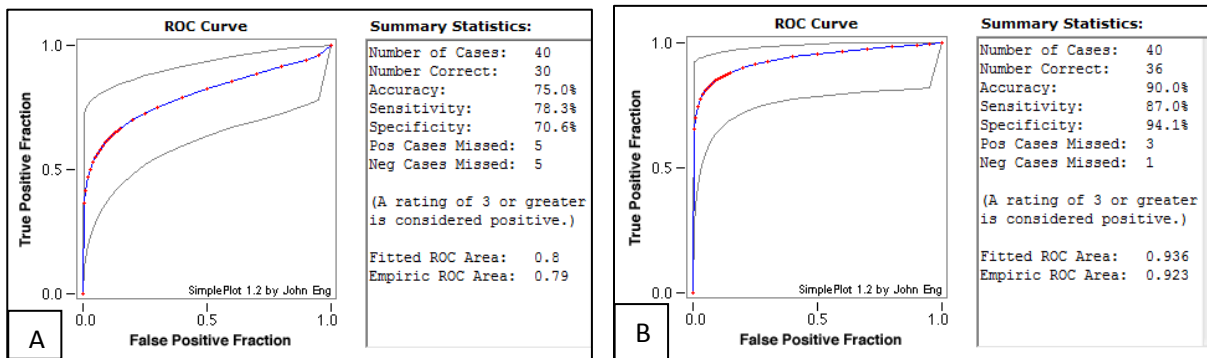


Figure 10: The receiver operating characteristics (ROC) and summary statistics for observer one using periapicals alone to diagnose periapical lesions. (A). The ROC and summary statistics for observer one when periapical radiographs and three-dimensional imaging was used in the diagnosis of periapical lesions (B).

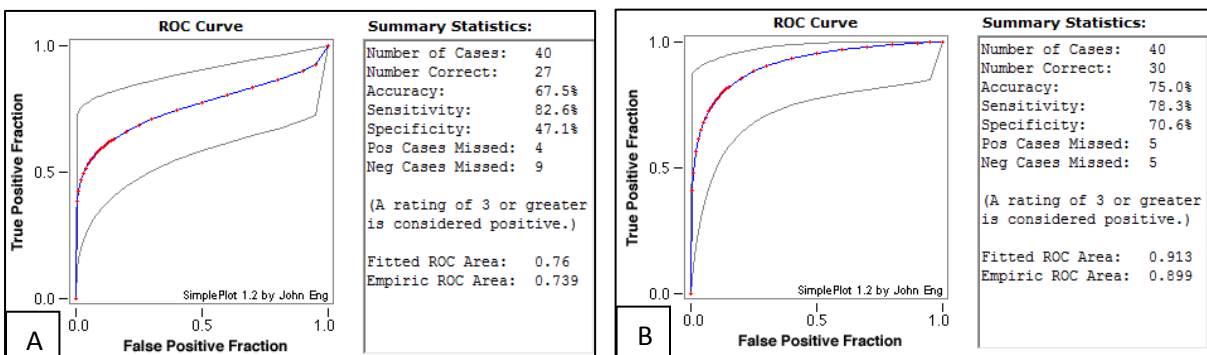


Figure 11: The receiver operating characteristics (ROC) and summary statistics for observer two using periapicals alone to diagnose periapical lesions. (A). The ROC and summary statistics for observer two when periapical radiographs and three-dimensional imaging was used in the diagnosis of periapical lesions (B).

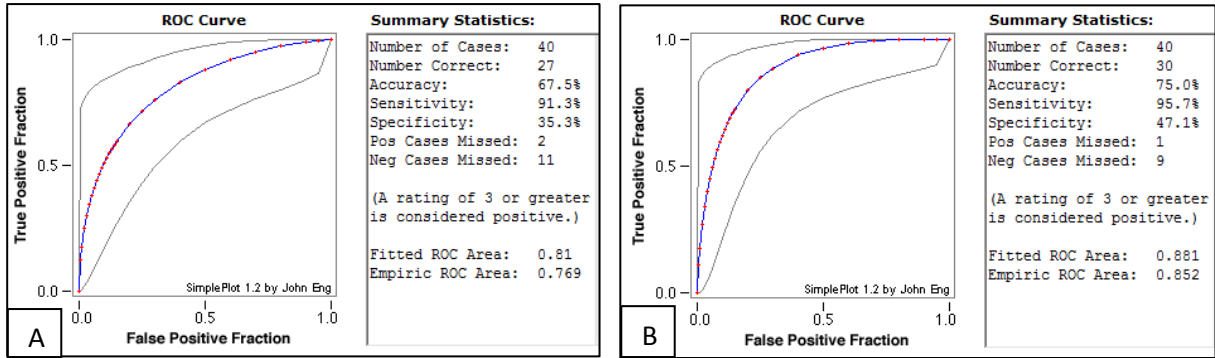


Figure 12: The receiver operating characteristics (ROC) and summary statistics for observer three using periapicals alone to diagnose periapical lesions. (A). The ROC and summary statistics for observer three when periapical radiographs and three-dimensional imaging was used in the diagnosis of periapical lesions (B).

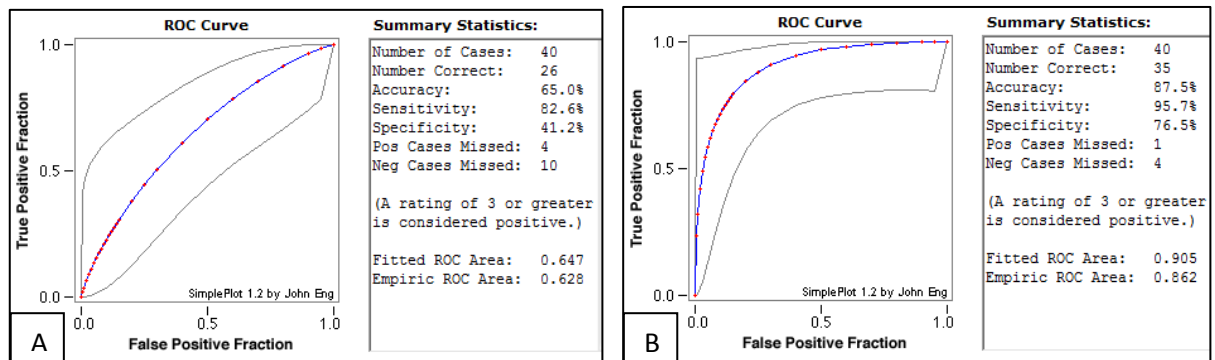


Figure 13: The receiver operating characteristics (ROC) and summary statistics for observer four using periapicals alone to diagnose periapical lesions. (A). The ROC and summary statistics for observer four when periapical radiographs and three-dimensional imaging was used in the diagnosis of periapical lesions (B).

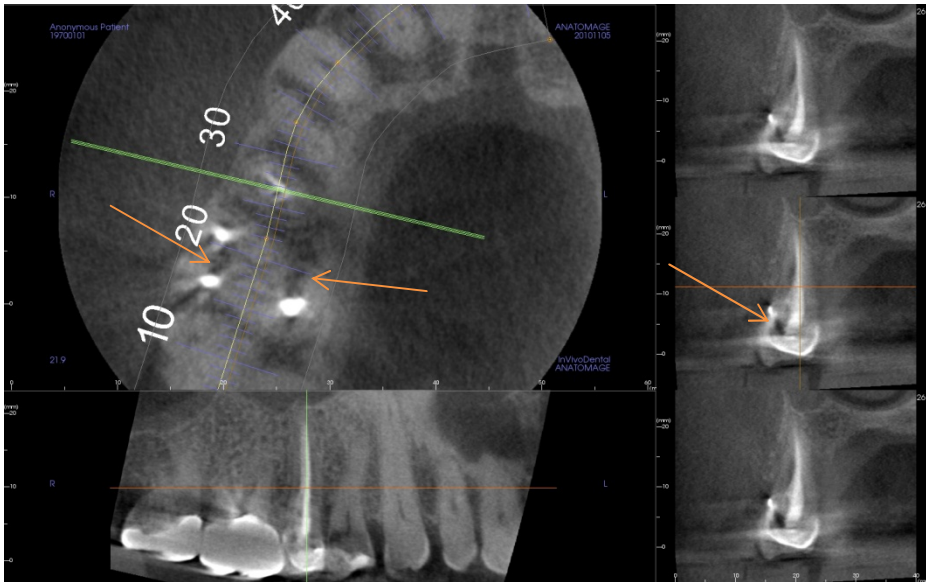


Figure 14: Example of beam hardening observed in a scan. Radiolucent lines radiating from the metallic restorations and endodontic filling material can be mistaken for pathologies.

Tables

Table 1

Limited FOV CBCTs available in the United States as of June 2011	Voxels in mm	Field of View	Exposure	Effective Dose in μSv	Digital Panoramic Equivalent	No. of days of annual per capita background radiation
3D Accutomo FPD 170	0.08, 0.125, 0.160, 0.250	4 x 4 cm	Continuous	² 43	3.1	6.4
Kodak 9000 (C) 3D	0.076	5 x 3.7 cm	Pulsed	*5.3 - 38.3 depending on region	0.38 - 2.7	0.79 - 5.7
Promax 3D	0.1, 0.2	8 x 8 cm	Continuous	² 28 - 122 depending on settings	2 - 8.7	4.17 - 18.2
PaX-Uni 3D (OS)	0.12 x 0.2	5 x 5cm	Not Published	² 44	3.14	6.5
Veraviewepocs 3D	0.125-0.2	4 x 4 cm, 4 x 8 cm	Continuous	sFOV ³ = 30 - 40 depending on FOV	2.1 - 5.2	4.5 - 6.0
PreXion 3D (Standard exposure)	0.2	3.2 inches diameter (8.1 x 7.5cm)	Continuous	*189	13.5	28.2
Scanora 3D	0.13-0.35	6 x 10cm scan diameters	Pulsed	*76	5.4	11.3
Comparison with Somatom Sensation32 row/64 slice MultiDetector CT	0.6	Body width x 12 cm	Continuous	*860	61.4	128.3
Comparison with Somatom 32 row/64 slice MultiDetector CT w/ CARE dose 4 D	0.6	Body width x 12 cm	Continuous	*534	38.1	80

*Ludlow et al

²Pauwels et al

³Hirsch et al

Effective dose calculated with ICRP 2007 tissue weights

Median of published effective dose for digital dental panoramic radiography = 14 μSv

Annual per Capita = 2.4 mSv (2,4000 μSv) per annum or approx. 6.7 μSv per day

Table 2

Imaging Modalities				
Observer	Periapical Radiographs		Periapical Radiographs AND CBCT	
	A _z	SD	A _z	SD
Observer 1	0.800	0.072	0.9364	0.041
Observer 2	0.7596	0.0789	0.9127	0.0456
Observer 3	0.8102	0.0751	0.881	0.0602
Observer 4	0.6469	0.0919	0.9054	0.0527
Mean	0.7542	0.0748	0.9088	0.0228

SD, standard deviation (Area)

Table 3

Tests of Between-Subjects Effects

Dependent Variable: Az

Source	Type III Sum of Squares	df	Mean Square	F	Sig.
Corrected Model	.055 ^a	2	.027	12.245	.012
Intercept	.237	1	.237	105.425	.000
Observers	.007	1	.007	3.168	.135
Modality	.048	1	.048	21.321	.006
Error	.011	5	.002		
Total	5.598	8			
Corrected Total	.066	7			

a. R Squared = .830 (Adjusted R Squared = .763)

Table 4

Detection of lesions by observers based on Imaging Modality								
Summary statistics by modality	Observer1		Observer 2		Observer 3		Observer 4	
	Periapical Radiographs	Periapical Radiographs and CBCT	Periapical Radiographs	Periapical Radiographs and CBCT	Periapical Radiographs	Periapical Radiographs and CBCT	Periapical Radiographs	Periapical Radiographs and CBCT
Sensitivity	78.3	87.0	82.6	78.3	91.3	95.7	82.6	95.7
Specificity	70.6	94.1	47.1	70.6	35.3	47.1	41.2	76.5
Accuracy	75.0	90.0	67.5	75.0	67.5	75.0	65.0	87.5
Cases correct *	30	36	27	30	27	30	26	35

* Cases correct out of 40 when compared to the ground truth. Sensitivity, specificity and accuracy in percentage

Table 5

Changes in treatment plans from all observers between modalities						
Directionality of change in treatment plan	Positive cases		Negative cases		All cases	
	Frequency	Percentage	Frequency	Percentage	Frequency	Percentage
Decrease in treatment	8	9	25	37	33	21
Same treatment	62	67	41	60	103	64
Increase in treatment	22	24	2	3	24	15
Total change	30	33	27	40	57	36

Total change determined by amount of treatment changes/cases. Cumulative number for all observers for positive cases = 92, for negative cases = 68 and for total cases = 160.

Table 6

Change in treatment plan for the control teeth per observer			
Observers	Decrease in treatment	No change in treatment	Increase in treatment
Observer 1	5	12	0
Observer 2	6	11	0
Observer 3	7	10	0
Observer 4	7	8	2
Total controls	25	41	2

Table 7

Change in treatment plan for the sample teeth per observer			
Observers	Decrease in treatment	No change in treatment	Increase in treatment
Observer 1	2	14	7
Observer 2	5	15	3
Observer 3	1	20	2
Observer 4	0	13	10
Total change	8	62	22

Table 8

Change in clinician's confidence in their treatment plan between modalities						
Directionality of change in treatment plan	Positive cases		Negative cases		All cases	
	Frequency	Percentage	Frequency	Percentage	Frequency	Percentage
Decrease in confidence	28	30	28	41	56	35
Same confidence	40	44	14	21	54	34
Increase in confidence	24	26	26	38	50	31
Total change	52	56	54	79	106	66

Total change determined by amount of treatment changes/cases. Cumulative number for all observers for positive cases = 92, for negative cases = 68 and for total cases = 160.

Table 9

Change in clinician's confidence for each observer with the addition of CBCT			
Observers	Decrease in confidence	No change in confidence	Increase in confidence
Observer 1	13	11	16
Observer 2	8	11	21
Observer 3	21	17	2
Observer 4	14	15	11
Total change	56	54	50

Table 10

Inter-observer Agreement for Periapical Lesion Detection					
Question One	Observer Pairs		(exact) P of McNemar's test	Kappa	Median of Kappa
Periapical Lesion Detection	1	2	0.25	0.71	0.44
	1	3	0.07	0.24	
	1	4	0.38	0.51	
	2	3	0.45	0.22	
	2	4	1.00	0.38	
	3	4	0.25	0.67	

Table 11

Inter-observer Agreement for Treatment Plan					
Question Two	Observer Pairs		(exact) P of McNemar's test	Kappa	Median of Kappa
Treatment Plan	1	2	1.00	0.70	0.38
	1	3	0.03	0.35	
	1	4	0.69	0.41	
	2	3	0.02	0.30	
	2	4	1.00	0.70	
	3	4	0.02	0.07	

Table 12

Intra-observer Agreement for Each Question			
Observers	Periapical lesion detection	Treatment Plan	Clinician's Confidence
Observer 1	80	85	80
Observer 2	85	85	75
Observer 3	70	70	100
Observer 4	70	65	100

Percentages for periapical lesion detection are based on lesion detection yes/no, treatment planning was based on any change, and clinician's confidence was based on whether the observer was confident/not confident

References

1. Bender, I., Seltzer, S, *Roentgenographic and Direct Observation of Experimental Lesions in Bone: I*. Journal of Endodontics, 2003. **29**(11): p. 702-706.
2. Bender, I. and S. Seltzer, *Roentgenographic and Direct Observation of Experimental Lesions in Bone: II*. Journal of Endodontics, 2003. **29**(11): p. 707-712.
3. Scarfe, W.C., M.D. Levin, D. Gane, and A.G. Farman, *Use of cone beam computed tomography in endodontics*. International Journal of Dentistry, 2009. **2009**.
4. Ludlow, J., *Dosimetry of the Kodak 9000 3D Small FOV CBCT and Panoramic Unit*. Arthroscopy: The Journal of Arthroscopic and Related Surgery, 2009. **107**(4): p. e29-e29.
5. Fryback, D.G. and J.R. Thornbury, *The efficacy of diagnostic imaging*. Medical decision making, 1991. **11**(2): p. 88.
6. Patel, S., A. Dawood, R. Wilson, K. Horner, and F. Mannocci, *The detection and management of root resorption lesions using intraoral radiography and cone beam computed tomography—an in vivo investigation*. International endodontic journal, 2009. **42**(9): p. 831-838.
7. Cramer CK, K.G., Epstein JB, Sheps SB. , *The delphi process in dental research*. J Evid Based Dent Pract., Dec 2008. **8**(4): p. 211-20.
8. McNeil, B.J., E. Keeler, and S.J. Adelstein, *Primer on certain elements of medical decision making*. New England Journal of Medicine, 1975. **293**(5): p. 211-215.
9. Tyndall, D. and H. Kohltfarber, *Application of cone beam volumetric tomography in endodontics*. Australian Dental Journal, 2012. **57**: p. 72-81.
10. Tyndall, D.A. and S. Rathore, *Cone-beam CT diagnostic applications: caries, periodontal bone assessment, and endodontic applications*. Dental Clinics of North America, 2008. **52**(4): p. 825-841.
11. Huumonen, S., T. Kvist, K. Gröndahl, and A. Molander, *Diagnostic value of computed tomography in re treatment of root fillings in maxillary molars*. International endodontic journal, 2006. **39**(10): p. 827-833.
12. Mozzo, P., C. Procacci, A. Tacconi, P. Tinazzi Martini, and I. Bergamo Andreis, *A new volumetric CT machine for dental imaging based on the cone-beam technique: preliminary results*. European Radiology, 1998. **8**(9): p. 1558-1564.
13. Ludlow, J.B., L.E. Davies-Ludlow, and S.C. White, *Patient risk related to common dental radiographic examinations: the impact of 2007 International Commission on Radiological Protection recommendations regarding dose calculation*. The Journal of the American Dental Association, 2008. **139**(9): p. 1237.

14. Kobayashi, K., Shimoda, S, Nakagawa, Y, Yamamoto, A, *Accuracy in Measurement of Distances Using Limited Cone-Beam Computerized Tomography*. The International Journal of Oral and Maxillofacial Implants, 2004. **19**(2): p. 228-231.
15. Lascala, C., Panella, J and Marques,MM, *Analysis of the accuracy of linear measurements obtained by cone beam computed tomography (CBCT-NewTom)*. Dentomaxillofacial Radiology, 2004. **33**: p. 291-294.
16. Pinsky, H., S. Dyda, R. Pinsky, K. Misch, and D. Sarment, *Accuracy of three-dimensional measurements using cone-beam CT*. Dentomaxillofacial Radiology, 2006. **35**(6): p. 410.
17. Vandenberghe, B., R. Jacobs, and J. Yang, *Detection of periodontal bone loss using digital intraoral and cone beam computed tomography images: an in vitro assessment of bony and/or infrabony defects*. Dentomaxillofacial Radiology, 2008. **37**(5): p. 252.
18. Sanfelice, C.M., et al., *Effects of Four Instruments on Coronal Pre-enlargement by Using Cone Beam Computed Tomography*. Journal of Endodontics, 2010. **36**(5): p. 858-861.
19. Cotton, T.P., T.M. Geisler, D.T. Holden, S.A. Schwartz, and W.G. Schindler, *Endodontic applications of cone-beam volumetric tomography*. Journal of Endodontics, 2007. **33**(9): p. 1121-1132.
20. Tsurumachi, T. and K. Honda, *A new cone beam computerized tomography system for use in endodontic surgery*. International endodontic journal, 2007. **40**(3): p. 224-232.
21. Low, K.M.T., K. Dula, W. Bürgin, and T. von Arx, *Comparison of periapical radiography and limited cone-beam tomography in posterior maxillary teeth referred for apical surgery*. Journal of Endodontics, 2008. **34**(5): p. 557-562.
22. Lofthag-Hansen, S., S. Huuonen, K. Grondahl, and H.G. Grondahl, *Limited cone-beam CT and intraoral radiography for the diagnosis of periapical pathology*. Oral Surgery, Oral Medicine, Oral Pathology, Oral Radiology, and Endodontology, 2007. **103**(1): p. 114-119.
23. Özer, Y., *Detection of vertical root fractures of different thicknesses in endodontically enlarged teeth by cone beam computed tomography versus digital radiography*. Journal of Endodontics, 2010. **36**(7): p. 1245-1249.
24. Tsesis, I., E. Rosen, A. Tamse, S. Taschieri, and A. Kfir, *Diagnosis of Vertical Root Fractures in Endodontically Treated Teeth Based on Clinical and Radiographic Indices: A Systematic Review*. Journal of Endodontics, 2010. **36**(9): p. 1455-1458.
25. Bornstein, M.M., A.B. Wölner Hanssen, P. Sendi, and T. Von Arx, *Comparison of intraoral radiography and limited cone beam computed tomography for the assessment of root fractured permanent teeth*. Dental Traumatology, 2009. **25**(6): p. 571-577.
26. Orhan, K., U. Aksoy, and A. Kalender, *Cone-Beam Computed Tomographic Evaluation of Spontaneously Healed Root Fracture*. Journal of Endodontics, 2010. **36**(9): p. 1584-1587.

27. Hassan, B., M.E. Metska, A.R. Ozok, P. van der Stelt, and P.R. Wesselink, *Detection of vertical root fractures in endodontically treated teeth by a cone beam computed tomography scan*. Journal of Endodontics, 2009. **35**(5): p. 719-722.
28. Rosenberg, P.A., et al., *Evaluation of pathologists (histopathology) and radiologists (cone beam computed tomography) differentiating radicular cysts from granulomas*. Journal of Endodontics, 2010. **36**(3): p. 423-428.
29. Weine, F.S., H.J. Healey, H. Gerstein, and L. Evanson, *Canal configuration in the mesiobuccal root of the maxillary first molar and its endodontic significance*. Oral Surgery, Oral Medicine, Oral Pathology, 1969. **28**(3): p. 419-425.
30. Degerness, R.A. and W.R. Bowles, *Dimension, anatomy and morphology of the mesiobuccal root canal system in maxillary molars*. Journal of Endodontics, 2010. **36**(6): p. 985-989.
31. Kottoor, J., N. Velmurugan, R. Sudha, and S. Hemamalathi, *Maxillary first molar with seven root canals diagnosed with cone-beam computed tomography scanning: a case report*. Journal of Endodontics, 2010. **36**(5): p. 915-921.
32. Neelakantan, P., C. Subbarao, and C.V. Subbarao, *Comparative evaluation of modified canal staining and clearing technique, cone-beam computed tomography, peripheral quantitative computed tomography, spiral computed tomography, and plain and contrast medium-enhanced digital radiography in studying root canal morphology*. Journal of Endodontics, 2010. **36**(9): p. 1547-1551.
33. Michetti, J., D. Maret, J.P. Mallet, and F. Diemer, *Validation of Cone Beam Computed Tomography as a Tool to Explore Root Canal Anatomy*. Journal of Endodontics, 2010. **36**(7): p. 1187-1190.
34. Sjögren, U., B. Hägglund, G. Sundqvist, and K. Wing, *Factors affecting the long-term results of endodontic treatment*. Journal of Endodontics, 1990. **16**(10): p. 498-504.
35. Patel, S., *New dimensions in endodontic imaging: Part 2. Cone beam computed tomography*. International endodontic journal, 2009. **42**(6): p. 463-475.
36. Stavropoulos, A. and A. Wenzel, *Accuracy of cone beam dental CT, intraoral digital and conventional film radiography for the detection of periapical lesions. An ex vivo study in pig jaws*. Clinical Oral Investigations, 2007. **11**(1): p. 101-106.
37. Nakata, K., et al., *Effectiveness of dental computed tomography in diagnostic imaging of periradicular lesion of each root of a multirooted tooth: a case report*. Journal of Endodontics, 2006. **32**(6): p. 583-587.
38. Paula-Silva, F.W.G., M.K. Wu, M.R. Leonardo, L.A. Bezerra da Silva, and P.R. Wesselink, *Accuracy of periapical radiography and cone-beam computed tomography scans in diagnosing apical periodontitis using histopathological findings as a gold standard*. Journal of Endodontics, 2009. **35**(7): p. 1009-1012.

39. Patel, S., A. Dawood, T.P. Ford, and E. Whaites, *The potential applications of cone beam computed tomography in the management of endodontic problems*. International endodontic journal, 2007. **40**(10): p. 818-830.
40. Patel, S. and A. Dawood, *The use of cone beam computed tomography in the management of external cervical resorption lesions*. International endodontic journal, 2007. **40**(9): p. 730-737.
41. *Use of cone-beam computed tomography in endodontics Joint Position Statement of the American Association of Endodontists and the American Academy of Oral and Maxillofacial Radiology*. Oral surgery, oral medicine, oral pathology, oral radiology and endodontics, 2011. **111**(2): p. 234-237.
42. Dechouniotis, G., X.M. Petridis, and M.K. Georgopoulou, *Influence of Specialty Training and Experience on Endodontic Decision Making*. Journal of Endodontics, 2010. **36**(7): p. 1130-1134.
43. McCaul, L., S. McHugh, and W. Saunders, *The influence of specialty training and experience on decision making in endodontic diagnosis and treatment planning*. International endodontic journal, 2001. **34**(8): p. 594-606.
44. Rushton, V., A. Qualtrough, Y. Al-Masserah, and M. Rushton, *The influence of coronal tooth tissue in the diagnosis of apical pathosis*. International endodontic journal, 2009. **42**(7): p. 603-608.
45. Wallace, J.A., M.K. Nair, M.F. Colaco, and S.F. Kapa, *A comparative evaluation of the diagnostic efficacy of film and digital sensors for detection of simulated periapical lesions*. Oral Surgery, Oral Medicine, Oral Pathology, Oral Radiology & Endodontics, 2001. **92**(1): p. 93-97.