

# **CONE BEAM CT IN OCCLUSAL CARIES RESEARCH**

Sonali Anil Rathore

A thesis submitted to the faculty of the University of North Carolina at Chapel Hill in partial fulfillment of the requirements for the degree of Master of Science in the department of Oral and Maxillofacial Radiology.

Chapel Hill 2009

Approved by:

Dr. Donald Tyndall

Dr. J. Timothy Wright

Dr. Eric T. Everett

## **ABSTRACT**

Sonali Anil Rathore: Cone Beam CT in Occlusal Caries Research

(Under the direction of Dr. Donald Tyndall)

The diagnosis of occlusal caries remains a challenge due to lack of a single sensitive and reproducible diagnostic tool. Cone beam computed tomography (CT) is volumetric imaging method which allows structures to be visualized in 3D as well as in discrete cross-sections. This research project was an *in-vitro* study to evaluate occlusal caries using conebeam CT and to compare microCT with histology in caries assessment. The project was divided into, two specific aims.

In the first aim, we compared the Cone beam CT with intraoral digital radiography in the detection of occlusal caries. For this a sample of sixty teeth were imaged first with intraoral digital radiographs and then with cone beam CT. Histology of these teeth was done, to serve as ground truth. Six observers looked at all the images and their responses were evaluated by ROC (Receiver Operating Characteristic) analysis.  $A_z$  (Area under the curve), was analyzed using ANOVA. We concluded that there were no differences in accuracy between the two modalities.

For the second aim, we compared micro-CT with histology for detection of occlusal caries. Accuracy was determined using Sensitivity and Specificity of the micro-CT. Precision

was determined using Inter and Intraobserver Kappa Statistics. We found that micro-CT compared well with histology, but due to some limitations in our portable micro-CT unit, it cannot completely replace it as the new 'gold standard'.

## **ACKNOWLEDGEMENTS**

I would like to thank my mentor, Dr. Donald Tyndall whose constant support, guidance and wisdom has helped me through different stages of this project.

Dr. Timothy Wright, for giving vision and direction to this project.

Dr. Eric Everett, for his insight and invaluable advice with the design and implementation of the research.

UNC School of Dentistry Radiology faculty, Dr. John Ludlow, Dr. Andre Mol and Dr. Enrique Platin, for their encouragement and advice.

Radiology residents and staff, Drs. Abeer Alhadidi, Wisam Al-Rawi, Angela Broome, Jeffery Price, Khin Thaw, Gina Palconet, Ms. Madge Webster, Ms. Sharon Green, Ms. Venesia Terry, for their support.

Finally, I would like to thank Mr. Wallace Ambrose in Dental Research for all his technical help.

## **DEDICATIONS**

I dedicate this project to my Mom and Dad for their unconditional love and support.

I am also very thankful to my husband Anil, for his love, patience and encouragement.

## TABLE OF CONTENTS

LIST OF FIGURES.....	viii
LIST OF TABLES.....	ix
ABBREVIATIONS.....	x
Chapter	
I. DENTAL CARIES.....	1
Changing nature of caries: .....	1
Current Trends in Caries Diagnosis and their limitations .....	2
II. CONE BEAM CT .....	6
Introduction: .....	6
Specific Aim 1:.....	7
Micro CT: .....	8
Specific Aim 2:.....	8
III. HIGH RESOLUTION CONE BEAM CT IMAGING OF OCCLUSAL CARIES.....	10
ABSTRACT .....	10
Introduction .....	12
Materials and methods:.....	14
Statistics .....	16
Results .....	16
Discussion: .....	17

IV.	COMPARISON OF MICRO-CT TO HISTOLOGY IN DENTAL CARIES DIAGNOSIS .....	21
	Abstract.....	21
	Introduction: .....	22
	Materials and methods:.....	24
	Statistics .....	26
	Results:.....	26
	Discussion: .....	26
V.	SUMMARY .....	29
	Cone beam CT and occlusal caries.....	29
	Micro-CT and occlusal caries .....	29
	REFERENCES.....	46

## LIST OF FIGURES

1. Sirona Cone beam CT unit.....	31
2. Close-up views of Sirona CBCT system (a) and conventional radiographs (b) of one of the test tooth. ....	32
3. ROC curves for bitewing and cone beam.....	33
4. Skyscan 1074HR micro-CT unit .....	34
5. A set of Hydroxyapatite rods .....	35
6. A test tooth viewed using the data-viewer software.. ....	36
7. Histology section of one of the sample teeth .....	37
8. Interobserver and Intraobserver Kappa statistics for Skyscan micro-CT .....	38



## LIST OF TABLES

1. Caries detection accuracy as measured by $A_z$ of the ROC analysis.....	39
2. ANOVA for area under the curve.....	40
3. Sensitivity, specificity and the p values for 6 observers and 2 modalities .....	41
4. Average Weighted Kappa values representing interobserver and intraobserver reliability .....	42
5. Likert scale for observation sessions.....	43
6. Abstracts on Comparison of micro-CT and Histology in Caries detection.....	44

## ABBREVIATIONS

ANOVA	Analysis of Variance
A <sub>z</sub>	Area Under receiver operating curve
CBCT	Cone Beam Computed Tomography
CT	Computed Tomography
DIFOTI	Digital Imaging Fiber-Optic Trans-Illumination
ECM	Electronic Caries Monitor
FMX	Full Mouth Radiographs
FOTI	Fiber-Optic Trans-Illumination
HA	Hydroxyapatite
kVp	Kilovoltage peak
LF	Laser Fluorescence
mAs	Milli-amperage
Micro-CT	Micro-Computed Tomography
MPR	Multi Planar Reformatting
QLF	Quantitative Light-Induced Fluorescence
ROC	Receiver Operating Characteristic
SD	Standard deviation
Sens	Sensitivity
Spec	Specificity

TACT	Tuned Aperture Computed Tomography
3D	Three dimensional
μm	Micrometer

## **CHAPTER 1**

### **DENTAL CARIES**

#### **CHANGING NATURE OF CARIES:**

Dental caries is the localized destruction of susceptible dental hard tissues by acidic by-products from bacterial fermentation of dietary carbohydrates. During the past few decades, changes have been observed not only in the prevalence of dental caries, but also in the distribution and pattern of the disease in the population.(1) (2) (3) Specifically, it has been observed that the relative distribution of dental caries on tooth surfaces has changed, and the rate of lesion progression through the teeth is relatively slow for most people. The caries decline in permanent teeth has been greater on interproximal and smooth surfaces than on fissured or occlusal surfaces.(4) Coronal caries in children's permanent teeth is predominately a disease of the pits and fissures.(5) (6) In some population groups, caries prevalence and severity in primary teeth might have stabilized or increased slightly. (7) Despite the widespread decline in caries prevalence and severity in permanent teeth in high-income countries over the past few decades, disparities remain and many children and adults still develop caries. U.S. findings by the Centers for Disease Control and Prevention (CDC) released in August 2005 reveal high ongoing prevalence of dental caries in children,

with 27% of preschoolers, 42% of school-age children, and 91% of dentate adults having caries experience.(7) (8)

The use of fluoride in public water supplies, in toothpaste, and in professional dental products, improved oral hygiene, and increased access to dental care have played major roles in this dramatic improvement. Nevertheless, dental caries remains a significant problem. While the outer enamel shell of a tooth's clinical crown has become more caries-resistant, the pits and fissures still allow ingress to damaging micro-organisms. Alarming carious destruction is often observed upon opening seemingly innocuous pits and fissures, as the anatomical constrictions of pits prevent adequate access to the tip of a dental explorer. (9)

Modern management of dental caries has three major components: prevention, control, and treatment, and is based on appropriate diagnosis of the disease and detection of pathological changes, i.e. lesion formation in its earliest stages.(10) Traditional paradigms for restoring carious lesions are being replaced by newer strategies that emphasize disease prevention and conservation of tooth structure. The search continues for the identification of practical models for predicting caries risk at the individual level.

## CURRENT TRENDS IN CARIES DIAGNOSIS AND THEIR LIMITATIONS

### I. Visual/Tactile methods:

Caries in occlusal and smooth surfaces has traditionally been assessed by visual inspection combined with probing.

The use of an explorer in detecting occlusal caries appears to add little information and may be detrimental.(11) A recent study confirmed the findings of light-microscopic studies that using a sharp dental probe for occlusal caries detection causes enamel defects.(12) In vitro visual examination of macroscopically intact occlusal surfaces in an effort to detect caries generally has limited sensitivity (i.e., the ability to accurately determine the presence of true disease), below 30%.(13) However, in a whole population, where larger lesions and sound teeth are included, the sensitivity of visual diagnostic methods is much higher.(14)

## II. Quantitative Light-Induced Fluorescence:

Quantitative Light-Induced Fluorescence (QLF) is a method of measuring induced tooth fluorescence after using light generally at or near 488 nm range to quantify tooth demineralization and lesion severity. For smooth surfaces, the mean sensitivity and specificity of QLF is 0.76 ( $\pm 0.02$  standard deviation [SD]) and 0.85 ( $\pm 0.09$  SD). For occlusal surfaces, the values are 0.61 ( $\pm 0.14$  SD) and 0.59 ( $\pm 0.18$  SD).(15) There are some concerns about the system related to the confounding effects that stains, plaque, fluorosis or other enamel opacities such as hypomineralization can have on lesion depth.(16)

## III. DIAGNOdent:

It is a commercial development of LF (the chair side battery powered quantitative diode-laser-fluorescence device.) This unit emits light at 655-NM wavelength from a fiber optic bundle onto the occlusal surface of the tooth. A second fiber optic bundle receives the

reflected fluorescent light beam, and changes caused by demineralization are assigned a numeric value, which is displayed on the monitor. The system is calibrated to a provided standard and to reference (sound) enamel. However this instrument is very sensitive to presence of stains, deposits, and calculus; all of which can lead to erroneous readings. Similarly, any changes in the physical structure of the enamel, including disturbed tooth development or mineralization, produced erroneous readings.(17) A systematic review done using DIAGOdent showed that for detection of dentinal caries, sensitivity values ranged widely (0.19 to 1.0), although most tended to be high.(18) (19) Specificity values exhibited a similar pattern, ranging from 0.52 to 1.0.(20) Most in-vivo studies using DIAGNOdent, find that it cannot differentiate caries from hypomineralisation, and conclude that its probably best used as an adjunct to a clinical examination.(21) (22) (23)

#### IV. Electrical Conductance Measurement (ECM):

The electrical conductivity of a tooth changes with demineralization. In carious pits and fissures the measurements show increased conductivity. ECM measurements have higher sensitivity but lower specificity than clinical visual methods and are currently limited to occlusal sites.(24) (25)

#### **Imaging Methods:**

##### I. Conventional Radiographs

In a clinical setting, conventional radiographs (bitewing radiographs) are the most trustworthy methods for detection of carious teeth. However, these are two dimensional

reproductions of a three dimensional object. Also, many studies have reported the limitation of conventional radiographs in detecting initial caries which may be explained by the overlapping of the pits and fissure by cusp walls in a two dimensional radiograph.(26) (27) (28)

## II. Digital Radiographs:

Digital systems seem to be as accurate as the currently available dental films for detection of caries. They have high sensitivity rate (.60 - .80) for detection of occlusal lesions into dentine with false positive fractions of 5-10%.(29) (30) Their advantage over conventional film is that they provide a wider dynamic range and require less patient exposure. Unlike conventional film that may take between three and five minutes to process, a digital radiographic image generally can be viewed quickly on the computer screen.

In conclusion, it can be said that a test which is highly sensitive and specific is desired. Sensitivity and specificity are one approach to quantifying the diagnostic ability of the test. Sensitivity is the probability of a positive test among patients with disease and Specificity is the probability of a negative test among patients without the disease.

It may not be always possible to have a test with high sensitivity and specificity, thus a method which results in higher specificity values is preferable as there is less risk of unnecessary treatments.



## **CHAPTER 2**

### **CONE BEAM CT**

#### **INTRODUCTION:**

Computed tomography can be divided into 2 categories based on acquisition x-ray beam geometry; namely: fan beam and cone beam. In fan-beam scanners, an x-ray source and solid-state detector are mounted on a rotating gantry. The data is acquired using a narrow fan shaped X-ray beam and the patient is imaged slice by slice in the axial plane. The final interpretation of the images is achieved by stacking the slices to obtain multiple 2D representations. In the cone beam technique, a single 360° scan is taken in which the x-ray source and a reciprocating area detector synchronously move around the patient's head, which is stabilized with a head holder. At certain degree intervals, single projection images, known as "basis" images, are acquired. This series of basis projection images is referred to as the projection data.(31)

Cone-beam computed tomography or (CBCT) systems have been designed for imaging hard tissues of the maxillofacial region. CBCT provides a volumetric x-ray scan of patient head that can be visualized in a variety of ways such as multi-planar reformatted (MPR) slices, cross-sectional slices, synthetic panoramic, 3D shaded surface and volumetric rendering. They offer several advantages over the regular CT systems such as rapid scan

times, image accuracy and dose reduction. A recent review has shown that effective dose (ICRP 2007) from a standard dental protocol scan with the 64-slice multidetector CT (MDCT) unit is 860  $\mu\text{Sv}$  which is 1.5 to 12.3 times greater than comparable medium- field of view dental CBCT scans(69 to 560 $\mu\text{Sv}$ ). (32)

#### SPECIFIC AIM 1:

**To compare accuracy of Sirona Cone beam CT with intra-oral radiography in the diagnosis of occlusal caries.**

**Hypothesis:** There will be no differences in accuracy between cone beam CT and intraoral radiography for occlusal caries detection.

**Rationale:** An ideal diagnostic test would enable the clinician to accurately assess the presence or absence of a lesion, to quantify its size and depth, and to determine its activity. While the physics underlying the radiographic image formation process is well suited for imaging the hard tissues, the sampling level of traditional intraoral imaging is not sufficient to fulfill these requirements. In order to acquire three-dimensional information, the level of sampling needs to increase.

The development of cone beam computed tomography has been revolutionary in the sense that complete (360°) sampling is now possible without increasing the patient dose to unacceptable levels. CBCT provides high diagnostic quality images, with 3D representation of the maxillofacial skeleton. This could presumptively, improve delineation of the anatomy with the lesions, thus improving the diagnostic process.

## MICRO CT:

Micro-CT is a miniature design of the Cone-beam CT, which is mostly used in laboratory studies. Two main technical differences between both make it possible to obtain a much better resolution. In Cone beam computed tomography, the X-ray source and detector rotate around the patient. However, for the study of materials, it is possible to rotate the object while the X-ray source and detector are stationary. The second difference is the size of the X-ray source which is 5-10  $\mu\text{m}$  in micro-focus computer tomography compared with a millimeter in medical applications. This microfocus X-ray source enlarges the images geometrically and thus assures high-resolution cross-sectional images. Thus micro-CT is a non-destructive technique, which allows high spatial resolution of inner structures to be recorded .(33) Depending on the X-ray source and the scanner design, the linear resolution for micro-CT is about 2-100  $\mu\text{m}$ . Micro- CT has been studied in dentistry, specifically for evaluation of mineral content and changes in dental hard tissue.

## SPECIFIC AIM 2:

**To compare Micro-CT with histology in detection of Occlusal Caries**

**Hypothesis: There will be no difference in Micro-CT and histology in Occlusal caries detection.**

**Rationale:** Histology has traditionally been the 'gold standard' in caries diagnosis studies. However it has several disadvantages, such as cumbersome sample preparation with demands on both time and personnel. There could be distortions in registering

adjacent slices which could lead to loss of key information pertaining to tissue distribution.

Also, it is a destructive process as once the sample is sectioned, other assays are not possible. On the contrary, Micro-CT allows nondestructive imaging of the internal tooth structure, with information being visualized either as discrete sections or as 3D volume renderings. Thus, it can provide a viable alternative to histology and allow longitudinal studies on the same sample.

## CHAPTER 3

### HIGH RESOLUTION CONE BEAM CT IMAGING OF OCCLUSAL CARIES

#### ABSTRACT

**Background:** During the past few decades, changes have been observed not only in the prevalence of dental caries, but also in the distribution and pattern of the disease in the population. Most conventional radiographic imaging of teeth underestimates the presence of caries. Cone-beam CT is a new technology which can provide volumetric data of the object, from which cross-sectional images can be obtained for different diagnostic purposes. It is assumed that these features would improve the accuracy in diagnosing dental diseases, including dental caries.

**Objective:** To compare the accuracy of Cone beam CT with intraoral radiographs for detection of occlusal caries.

**Materials and methods:** A set of sixty extracted teeth were mounted on a mandible, surrounded by a plexiglass box. These teeth were imaged using a Sirona Cone beam CT unit and intraoral radiographs (Planmeca). Six observers used both modalities and a 5 point Confidence scale to evaluate presence of occlusal caries in all the sixty surfaces. The actual presence or absence of caries was established with histology. Receiver operating characteristic analysis and weighted kappa statistics were used. Differences in  $A_z$  values

between observers and modalities were analyzed using analysis of variance (ANOVA).

Differences in sensitivity and specificity were analyzed using the Wilcoxon test.

Interobserver and intraobserver reliability was assessed by Weighted Kappa scores.

**Results:** The diagnostic accuracy of the two radiographic systems was assessed from the area under the ROC curve (Az). The mean value and standard deviation of Az was  $0.719 \pm 0.038$  for the Cone beam and  $0.649 \pm 0.062$  for the intraoral radiographs. Results of ANOVA demonstrated that there was no significant difference between the modalities and the observers. The Interobserver Kappa for pairs of observers ranged from fair-substantial for bitewings (0.244-0.543) and cone beam (0.152-0.401). Four out of six observers reported higher sensitivity but lower specificity with cone beam. The Wilcoxon Exact p-Value showed no difference in sensitivity (0.175) or specificity (0.573) between the two modalities.

**Discussion:** Cone beam CT is a new radiographic modality for dental imaging and to establish its accuracy, it must be compared with well-established systems already in use. The results of this in-vitro study showed that accuracy of cone beam CT was diagnostically comparable with intra-orals in detection of occlusal caries. Based on these results it is fair to suggest that if a cone beam CT examination has been performed for other diagnostic tasks it may be reasonable to examine the teeth for any carious lesions. Any referral made for a cone beam examination should be judiciously advocated and based on a case by case selection.

## INTRODUCTION

Dental caries is an infectious disease resulting in destruction of tooth structure by acid-forming bacteria found in dental plaque, an intra-oral bio-film, in the presence of sugar. Over the last decades, a remarkable decline in caries prevalence has been noticed in the world population, primarily due to increase in scientific knowledge on the etiology, initiation, progression and prevention of disease coupled with wide scope of preventive measures and fluoride therapy. However, even in populations with decreased caries prevalence, the proportion of occlusal caries has increased and the difficulty of accurately detecting incipient pit and fissure lesions has been continuously discussed reinforcing the interest for studying this type of carious lesion.(26) These changes have important implications for diagnosis and management of incipient lesions, predicting caries risk, and conducting effective disease prevention and management programs for individuals and populations.

The most common methods among US dentists for the clinical diagnosis of occlusal caries are visual/tactile and visual inspection aided by radiographs. A recent review done by the University of North Carolina/Research Triangle Institute by Bader et al. found that visuo-tactile methods have low sensitivity and moderate to high specificity in detecting occlusal lesions.(34) In a clinical setting, conventional radiographs (bitewing radiographs) are the most trustworthy methods for detection of carious teeth. However, these are two dimensional reproductions of a three dimensional object. The introduction of direct digital radiography (DR) has not helped to solve the problem. Most studies report similar performance between digital and conventional imaging modalities.(29) (35)

A new technology called Tuned Aperture Computed Tomography (TACT) images makes it possible to view three-dimensional objects in tomosynthetic radiographs. However, several studies have shown that there is no improvement in the diagnosis of primary caries using TACT.(36)(37; 38) Studies have shown that some non-radiographic methods such as QLF, ECM, DIAGNOdent, DIFOTI or FOTI should be used as an adjunct to clinical decision making and serve primarily as a support tool for making preventive treatment plan decisions in conjunction with caries risk assessment .(16) (17)

Although clinical diagnostic methods are highly specific, the low sensitivity achieved, particularly for non-cavitated occlusal surfaces in vivo, means that the use of diagnostic aids with superior performance is indicated and that new methods for caries diagnosis are required.(39)

The development of cone beam computed tomography has been revolutionary in the sense that complete (360°) sampling is now possible without increasing the patient dose to unacceptable levels. CBCT is capable of providing sub-millimeter resolution in images of high diagnostic quality, with short scanning times (10–70 seconds) and radiation dosages reportedly up to 15 times lower than those of conventional CT scans. Increasing availability of this technology provides the dental clinician with an imaging modality capable of providing a 3-dimensional representation of the maxillofacial skeleton with minimal distortion.

Our specific aim for this study was to compare the accuracy of Sirona Cone beam CT system with intraoral radiographs in the diagnosis of occlusal caries. We hypothesized that



there will be no difference in the accuracy of occlusal caries detection between intraoral radiographs and cone beam CT.

## MATERIALS AND METHODS:

### ***Sample size selection:***

This was an *in-vitro* study with a sample of 60 extracted teeth (consisting of both premolars and molars). This number was based on a literature review of articles based on a similar hypothesis. The sample was selected as half carious and the other half as control (sound), as determined by visual examination. These teeth were collected from different departments such as Periodontology, Prosthodontics and Oral & Maxillofacial Surgery at the School of Dentistry.

### ***Image acquisition:***

A human dried mandible with a set of teeth placed in wax was used to simulate the patient's mouth. Each of the sixty teeth was mounted individually in an extraction socket, created specifically for the experimental tooth. The mandible was surrounded by a plexiglass box to simulate soft tissues. These teeth were imaged using Galileos (Sirona Bensheim, Germany) cone beam unit (Fig 1). 60 separate scans were taken and these images were then reconstructed to different cross-sectional, axial and tangential views. The exposure parameters for the Cone beam CT were set at 85 Kvp and 21 mAs, with a total exposure time of 2-4 seconds.

The teeth were then imaged using the Planmeca (Helsinki, Finland) intraoral imaging system. The exposure parameters for this system were set at 70 Kvp and 3.2 seconds as the exposure time. After all the imaging was performed the teeth were sectioned using an Isomet low speed saw to establish 'ground truth'. They were sectioned to 250 $\mu$  thin sections and viewed under a stereomicroscope (Fig 7). Of the 60 teeth, 27 teeth had occlusal caries and the other 33 were controls.

***Observation sessions:***

Six observers viewed all the images from both the modalities. These observers were two radiologists, two radiology residents and two general dentists. They were asked to record the presence or absence of occlusal caries on a 5 point confidence scale which ranged from 1 = caries definitely absent to 5 = caries definitely present (Table 5). The observers were given a short training session in using Sidexis software and also provided with an instruction brochure on how to observe the images. The intraoral images were viewed using Vixwin 2000 (version 1.11, Gendex) and the cone beam images were viewed using Galaxis software (Sirona, Germany). To standardize the viewing conditions all the images from both modalities were viewed using one computer (Lenovo, Think vision, IBM, USA) in the Radiology clinic under dimmed lighting.

The observers had the flexibility to scroll through the entire volume of dataset for each of the 60 teeth. The observers were asked to repeat their observations after two weeks to look for intraobserver reliability. For this purpose a set of twenty teeth were randomly selected from the entire sample. Fig. 2 shows occlusal caries in the close-up view using Sirona and also the intraoral radiograph.

## STATISTICS

Receiver operating characteristic (ROC) curves were constructed for each observer and each modality. Diagnostic accuracy ( $A_z$ ) was expressed as the area under the curve (AUC). The difference in the AUC for the two modalities was assessed using analysis of variance (ANOVA), controlling for observer. The data was dichotomized with scores of 1, 2, and 3 representing a negative finding (caries absent), and scores of 4 and 5 representing a positive finding (caries present). Using this dichotomization, the sensitivity and specificity of the two modalities was compared with the exact Wilcoxon rank-sum test. Interobserver and Intraobserver reliability was assessed by weighted Kappa scores. All statistics was done using SAS (version 9.2, Cary, NC)

## RESULTS

The diagnostic accuracy of the two radiographic systems was assessed using the ROC  $A_z$  (Fig.3). The mean value (standard deviation) of the  $A_z$  for Cone beam CT and intraoral radiographs were 0.72 (0.04) and 0.65 (0.06), respectively (Table 1). The difference between the modalities, controlling for observers, was borderline insignificant ( $p=0.07$ ) at the 0.05 level (Table 2).

The difference in sensitivity (Wilcoxon:  $p=0.18$ ) and specificity (Wilcoxon:  $p=0.57$ ) between the two modalities was not statistically significant at the 0.05 level (Table 3). The interobserver kappa for pairs of observers ranged from fair to moderate (0.24 - 0.54) for bitewings and slight to fair (0.15 - 0.40) for Cone beam. The intraobserver kappa ranged from moderate to substantial for both (0.52-0.81) bitewings and (0.50-0.85) Cone beam.

Four of six observers reported higher sensitivity with cone beam. The mean and SD across observers for both modalities were calculated (Table 4).

#### DISCUSSION:

The use of cone beam CT in dentistry for three dimensional imaging is becoming increasingly popular. Its potential to visualize minute changes in both the teeth and the surrounding structures is making it the modality of choice for an increasing number of diagnostic and treatment planning tasks. However, as CBCT is a new radiographic modality, its accuracy had to be compared with an existing well-established system. The aim of the present study was to compare the accuracy of cone beam CT with intraoral radiographs in detecting occlusal caries.

Our present study concluded that there was no statistically significant difference between Sirona cone beam CT (in the close-up or magnified mode) and conventional radiography for occlusal caries detection. In the recent years, a number of studies have been done to establish the accuracy of cone beam CT in caries detection. Local-CT a technique studied by van-Daatselaar and then by Kalathingai et al compared local computed tomography and conventional radiography for proximal caries detection. While van-Daatselaar found that the technique could be promising in the future, Kalathingai et al found no difference between the two modalities.(40)(41) Accuracy studies of cone-beam CT looking at occlusal/proximal caries have had varied results. Akdeniz et al compared the Accuitomo (3DX) CBCT, Digora-fmx and Insight film for measuring depth of proximal caries

lesions. The authors found that the Accuitomo images provided more accurate lesion depth estimates with less variation when compared with measurements performed on the sections of the tooth than did the intraoral images and therefore suggested that CBCT appears to be a promising tool for monitoring small caries lesions. Tsuchida et al. also assessed the accuracy of the 3D Accuitomo in evaluating incipient proximal caries and found that 3D Accuitomo could not enhance the accuracy in detecting the carious lesions. (42)

More recently, Haiter-Neto et al. compared the caries diagnostic accuracy of two cone beam CT systems (CBCT) with two intraoral receptors, one digital and one film. They concluded that the NewTom 3G CBCT had a lower diagnostic accuracy for detection of caries lesions than intraoral modalities and the 3DX Accuitomo CBCT. The Accuitomo CBCT had a higher sensitivity than the intraoral systems for detection of lesions in dentin, but the overall true score was not higher. It is difficult to directly compare the results of previous studies with ours, due to differences in experimental design, number of surfaces involved and also the observer's background knowledge.

We used ROC analysis to evaluate the diagnostic performance of the two modalities. The analysis is made by comparing significant differences between the areas under the ROC curves that represent the competing modalities.(43) An advantage of using ROC analysis is that it reflects the diagnostic performance more comprehensively than sensitivity and specificity, which are determined by only one cut-off point.(44) It also provides the most meaningful approach to compare the diagnostic performance of two or more different

imaging modalities because it distinguishes between the inherent capacities of the observers to under- and over-read when interpreting imaging and is used in many studies.(45)(46)

In our study, the  $A_z$  for cone beam was 0.72 and for the intraoral radiographs  $A_z$  was 0.65. To interpret these results an area of 1 represents a perfect test and anything 0.5 and below is a poor test. Applying this to our results both tests represent fair test. Thus, neither test could be considered very accurate. The interobserver kappa for pairs of observers ranged from fair to moderate (0.24 - 0.54) for bitewings and slight to fair (0.15 - 0.40) for Cone beam. In reporting Kappa statistic, a perfect agreement would equate to kappa of 1, and chance agreement would equate to 0. (47) The motive for including multiple observers in caries diagnostic studies is to ensure better representativeness.(48) Thus we chose a broad range of graduate students, general dentists and Radiologists with several years of experience. Also, as this was an in-vitro study, we cannot make direct comparisons with an in vivo clinical situation. There are inherent differences in scanning tissues in air vs. in vivo where there is water in the soft tissues and bone. Some studies emphasize submerging the object in water to better simulate in vivo conditions. Also, the presence of restorations and or patient movement can further compromise the caries diagnostic process.

In conclusion, this study showed that there was no difference in the diagnostic accuracy of the cone beam CT when compared with intraoral radiographs in diagnosis of occlusal caries. Some may argue that CBCT could still be considered superior due to its

simplicity and the fact that it is an extraoral imaging modality. In a recent editorial by Farman, the principle of ALARA (As Low As Reasonably Achievable) is still fundamental for diagnostic radiology and CBCT procedures should be reserved for selected cases.(49). Diagnostic benefit and dose detriment tradeoffs are important considerations in choices of radiographic procedures. The effective dose of Sirona cone beam is 70  $\mu\text{Sv}$  ICRP 2000 as compared with 5.0  $\mu\text{Sv}$  for a four-image posterior bitewings with PSP or F-speed film with rectangular collimation or 34.9  $\mu\text{Sv}$  for a full-mouth radiographs (FMX) with photo-stimulable phosphor (PSP) storage or F-speed film with rectangular collimation.(50; 51) From results of our study we can conclude that a cone beam CT exam for the sole purpose of looking at occlusal caries is not justified.

## CHAPTER 4

### COMPARISON OF MICRO-CT TO HISTOLOGY IN DENTAL CARIES

#### DIAGNOSIS

##### ABSTRACT

**Background.** Histologic sectioning of extracted teeth has been conventionally used as the gold standard to which new diagnostic modalities are compared. Sectioning is destructive, with demands on both time and personnel. In Cariology research, there is an increased demand for a nondestructive technique which will not only simplify the investigative procedure but also allow for the preservation of sample for longitudinal use. Micro-computerized tomography (micro-CT) provides 3-dimensional information of the sample which can also be visualized in discrete sections.

**Objective.** To compare Micro-CT with histology for occlusal caries detection.

**Materials and methods.** Sixty extracted teeth (molars and premolars) were scanned using Skyscan 1074HR (Skyscan, Kontich, Belgium) with a 20.4  $\mu\text{m}$  resolution. Of these only 45 teeth were used as the final sample and the rest were eliminated due to severe ring artifacts. A dynamic range was established for the micro-CT using a set of hydroxyapatite rods. The scan and reconstruction settings were optimized. The images were reconstructed by Nrecon software and viewed with the data viewer. The teeth were then sectioned using



a diamond saw into 250 µm thin sections and viewed under a stereomicroscope. Three observers graded the presence or absence of caries, and the results were compared with histology of the sectioned teeth.

**Results.** Sensitivity and specificity for micro-CT were established using histology as the gold standard. Sensitivity was 0.88 and specificity 0.81. Interobserver agreement was calculated using kappa and was reported as moderate to substantial (0.47- 0.65) and the intraobserver agreement was substantial (0.62-0.73).

**Discussion.** The initial data suggest that micro-CT can detect occlusal lesions in good agreement with histology. This may provide a viable alternative to histology in caries diagnosis. Recent studies suggest similar findings. The use of microtomographic technique in dentistry is relatively new and still has the need for further validation studies to be considered as a true gold standard.

## INTRODUCTION:

Conventionally, 'gold standards' used in the evaluation of different caries diagnosis techniques are based on histological sectioning. To test the accuracy of caries diagnosis, the outcome of the new diagnostic measure must be held against the true diagnosis that is obtained by a validation or reference method also called as a *gold standard*. Any robust gold standard must fulfill three criteria: reproducibility, repeatability, and replicability.(52)

(53)

The use of histology as the gold standard gives a true evaluation of the diagnostic accuracy of radiographs in the detection of dental caries, and clearly has much to commend it.(54) However, histology requires cumbersome sample preparation, and induces tissue loss and irreversible sample destruction. In addition, sectioning may not be appropriate if the specimens have to be used for other longitudinal experiments.(55) Sectioning also limits the representation of dynamics of the caries lesion to one single slice. In Cariology research, there is an increased demand for a non-destructive technique which will enable longitudinal studies and decrease demands on both time and personnel. Thus, a search for a new gold-standard with these characteristics seems to be essential.

Micro Computed Tomography (micro-CT) is a miniaturized form of CT scanning, which was developed in the beginning of the 1980s predominantly for laboratory purposes on small samples or material experiments, and used frequently in the studies of trabecular bone structure and mineral analysis. It uses a micro Focus X-ray apparatus as the X-ray source and assures high-resolution cross-sectional images by enlarging images geometrically. It allows nondestructive imaging of the internal tooth structure, with information being visualized either as discrete sections or as 3D volume renderings. It is emerging as a potential key tool in, in-vitro caries research as it allows three dimensional images recording of inner structures with high spatial resolution and without destruction of samples.

Our specific objective for this study was to compare Micro-CT to histology in occlusal caries diagnosis.

## MATERIALS AND METHODS:

### ***Sample for the study:***

Our sample consisted of sixty extracted teeth (both premolars and molars), collected from various departments at UNC School of Dentistry. These teeth were half carious and half sound (control), as determined by visual examination. Of the sixty teeth, fifteen teeth were eliminated from the sample, due to some severe ring artifacts, making them undiagnostic. This reduced the sample size to forty five teeth.

### ***Micro-CT instrument characterization:***

For our study, we used the Skyscan 1074HR Micro- CT (Skyscan, Aartselaar, Belgium) at a resolution of 20.5  $\mu\text{m}/\text{pixel}$  (Fig 4). The detector for this unit is a 768x576 pixels 8-bit X-ray camera in on-chip integration mode with lens coupled to scintillator. In micro-Computed Tomography, the object is rotated so as to obtain radiographic projections from different viewing angles. We selected a set of four Hydroxyapatite rods (CIRS, Inc., Norfolk, VA) as phantoms to optimize the scan settings (Fig 5). These rods ranged in different densities from 50mg/cc to 1000mg/cc. The sample of HA rods were then exposed to the Micro- CT to establish the cutoff point where the densities become visible. This would help determine a range in which tooth structures became visible and eventually help in caries detection. All the sixty teeth were scanned individually, at 1000 $\mu\text{A}$ , 40KVP and 600ms. The transmission X-ray images were acquired from 200 rotation views over 180° of rotation (0.9° rotation step). The instrument settings were optimized and not changed between the samples. The images were reconstructed by Nrecon software, version 1.4.4 (Skyscan, Kontich, Belgium).

The reconstruction was performed using an algorithm based on the filtered back-projection procedure for Feldkamp cone-beam reconstruction. The settings for reconstruction were determined on a dynamic range of 0.0500 to 0.69500. These were optimized to the HA phantoms and applied to all samples. The ring artifact reduction and smoothing filter were applied to all the reconstructed images. Data viewer (version 1.4.1, Skyscan, Kontich, Belgium) a free software, was downloaded from the Skyscan website, <http://www.skyscan.be/products/> to view these images (Fig.6).

***Observation sessions:***

The teeth were then sectioned using an Isomet low speed saw (Buehler, USA) into 250µm thin sections and viewed under a stereomicroscope (Fig 7). Of the total sample of 60 teeth, 15 teeth had to be discarded from the sample due to ring artifacts. Of the remaining 45 teeth, 20 teeth were carious and 25 had sound occlusal surfaces (controls). Three observers were asked to look at the Micro-CT images for the presence and absence of occlusal caries. Of these, two were Radiology residents and the third was a general dentist. Some of the teeth had proximal lesions, but these were not reported for this study. A short training session was provided to all the observers in using the data viewer for looking at the Micro-CT images. The observers looked at a sample of 15 teeth, after a two week interval to look for intraobserver agreement. The results were then compared with histology of the sectioned teeth.

## STATISTICS

We tested for accuracy and reproducibility of the micro-CT. Accuracy was tested using Sensitivity and Specificity and reproducibility was tested using Cohen's Kappa statistics. Sensitivity and Specificity for Micro-CT were established using histology as the 'gold standard'. Interobserver and intraobserver agreement was assessed using Kappa statistic. All statistics was performed using SAS (version 9.2) Cary, NC.

## RESULTS:

The average Sensitivity for Micro-CT was 0.88 and average Specificity was 0.81 respectively. Interobserver and intraobserver agreement was calculated for the three observers using Kappa statistics (Table 7). Interobserver agreement was reported as moderate to substantial (0.47- 0.65) and the intraobserver agreement was substantial (0.62-0.73).

## DISCUSSION:

Over the past years there have been attempts to improve the development of techniques for caries detection and quantification. The demand for a non-destructive method has encouraged the use of micro-CT in studies of enamel demineralization. In dentistry, micro-CT has been used to observe the structure of bone, measure enamel thickness in teeth and to study the morphogenesis of carious lesion.(56; 57) It has been used in Endodontics, to study the root canals and gutta percha.(58; 59) It has been

considered suitable for evaluation of subsurface lesions.(60) It has also been used in studies evaluating the internal structure and mineral concentration of the human teeth.(61; 62) A recent study by Tsuchida et al, evaluating the accuracy of 3DAccuitomo cone beam system with conventional films for detection of incipient proximal caries used Micro-CT as a gold standard.(63) Their rationale for its use was as the disease process of dental caries is caused by decalcification, microCT could be used as an adequate measure to estimate the extent of caries.(64)

In our study, we compared the Sky scan 1074 Micro-CT to histology for detection of occlusal caries. A review of the literature shows that several authors have compared Micro-CT with histology, as a potential new 'gold standard'. However, many of these studies are abstracts or presentations at conferences and not peer reviewed articles. A list of the abstracts, based on a similar hypothesis as ours is illustrated in (Table 6). The results of our pilot study suggest that Micro-CT can detect occlusal carious lesions in good agreement with histology. However, our study had some limitations that need to be addressed. Our Micro-CT unit had a size restriction of the sample being imaged, so some of the larger molars had to be sectioned at the cervical level. Our reconstructed images showed 'ring artifacts', which can occur due to imperfect detector element. Our sample size had to be reduced to 45 teeth, due to some teeth exhibiting very severe ring artifacts. We also chose an 'ideal' sample, which were extracted teeth that had no restorations. Presence of restorations can produce significant streak artifacts, which can further compromise the diagnostic process.

The use of Micro-CT in dentistry is relatively new and dates only two decades. While various studies have shown that Micro-CT can perform as well or better than histology, we concluded that future validation studies are needed to establish its permanence.

## **CHAPTER 5**

### **SUMMARY**

#### **CONE BEAM CT AND OCCLUSAL CARIES**

The results of our study showed that there was no difference in accuracy for detection of occlusal caries, between intra-oral radiographs and Sirona cone beam CT. A recent review done by Tyndall et al, (65) showed that Cone beam CT has been studied by different groups in caries detection. Some authors have shown higher sensitivity and lower specificity, of CBCT when compared to traditional imaging in caries detection. Whereas, other authors have shown no differences between CBCT and other modalities tested. It has to be taken into consideration that most of these studies are in-vitro. Based on the review of the literature, at this point in time, the use of cone beam CT, exclusively to look for caries does not seem justified.

#### **MICRO-CT AND OCCLUSAL CARIES**

Our study showed that Micro-CT compared well with histology for occlusal caries detection. However, our study had several limitations in the study design that need to be factored in when making a conclusion. With the Skyscan 1074 unit that was used in our study, we had a sample size restriction in the unit. We also had to remove some teeth from



the original sample, due to some issues with ring artifacts. So, even though the Skyscan 1074 Micro-CT showed promising results, it would not be able to replace histology completely. Other studies, used to test a similar hypothesis have shown very promising results.

The use of Micro-CT in dentistry is relatively new and needs future validation studies to be considered as the new 'gold standard'.

Figure 1. Sirona Cone beam CT unit

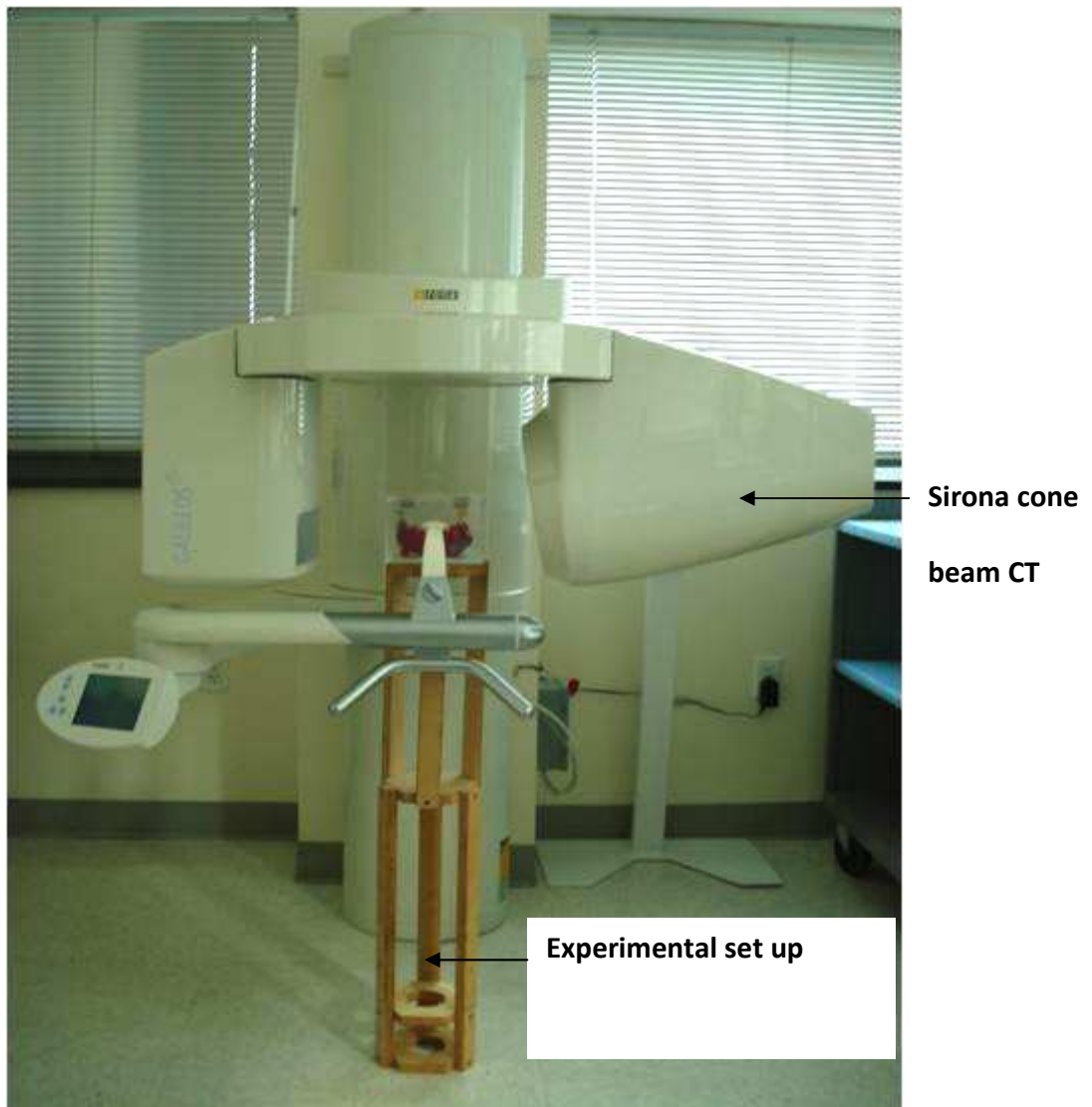


Figure 2(a) Close-up views of Sirona CBCT system of one of the test tooth.

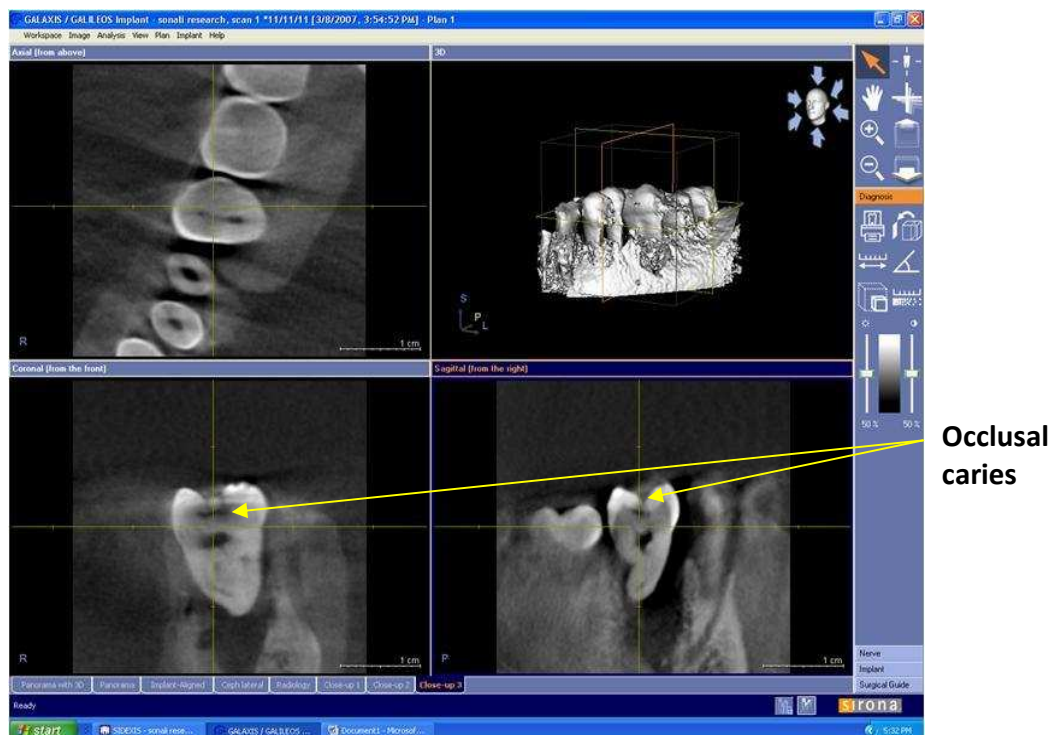

Figure 2(b) Intra-oral Radiograph for one of the test tooth

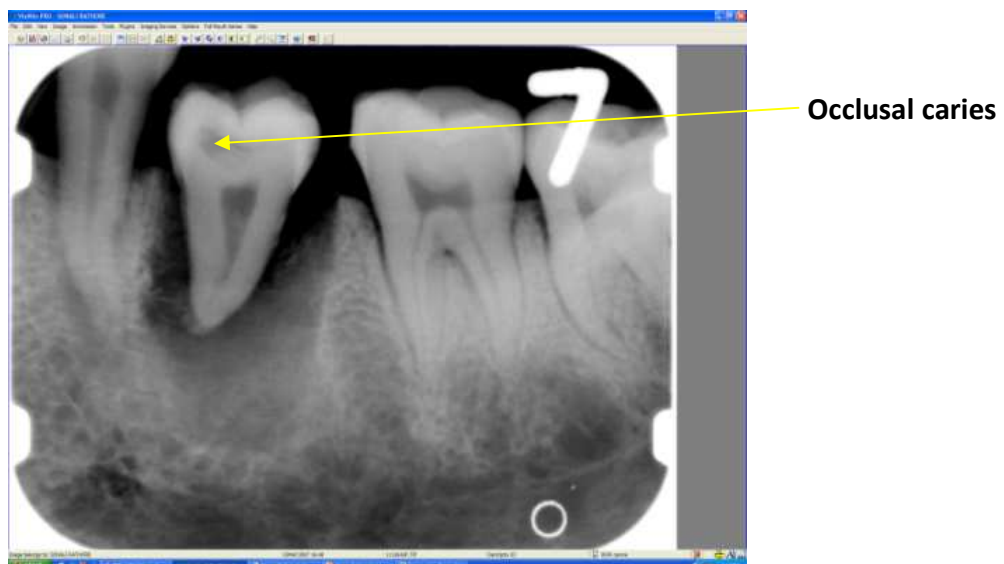

Figure 3. ROC curves for Bitewing and Cone beam. Pooled data across observers,  
AUC for CB=0.72 and AUC for BW =0.65

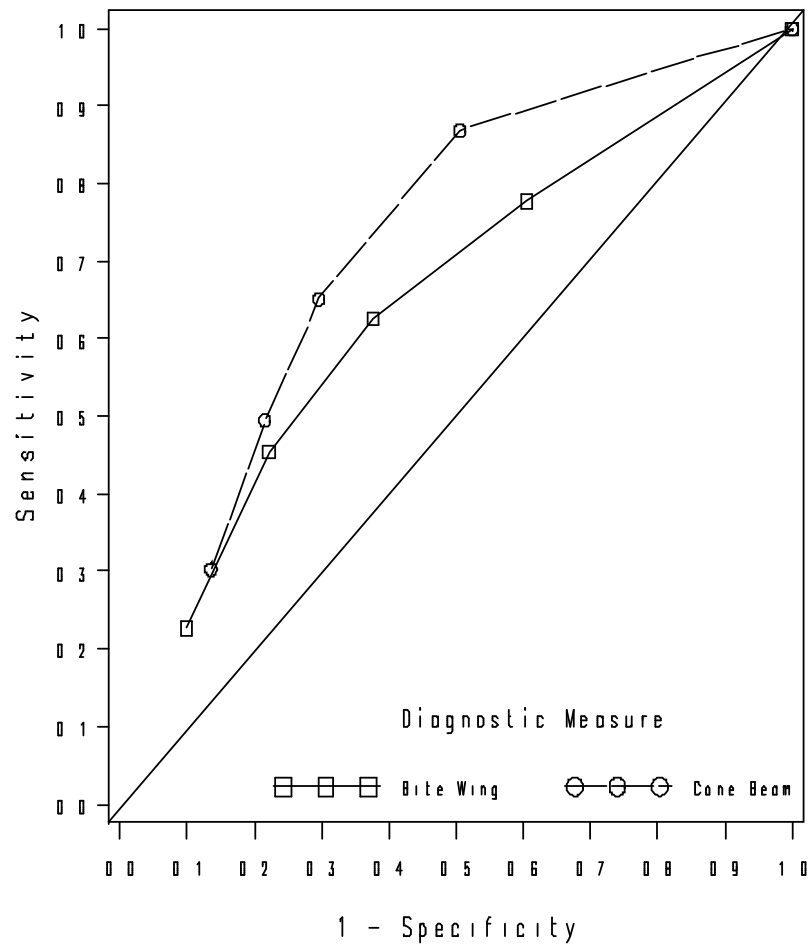



Figure 4: Skyscan 1074 Micro-CT unit attached to the primary workstation (Dell computer)



Skyscan 1074 Micro-CT

Figure 3. A set of Hydroxyapatite rods ( From left to right arranged in order of increasing density from 50 mg/cc to 1000 mg/cc. Scale= 3mm)




Figure 4. Screen capture showing a single view of a single slice taken 2.780mm from one end.

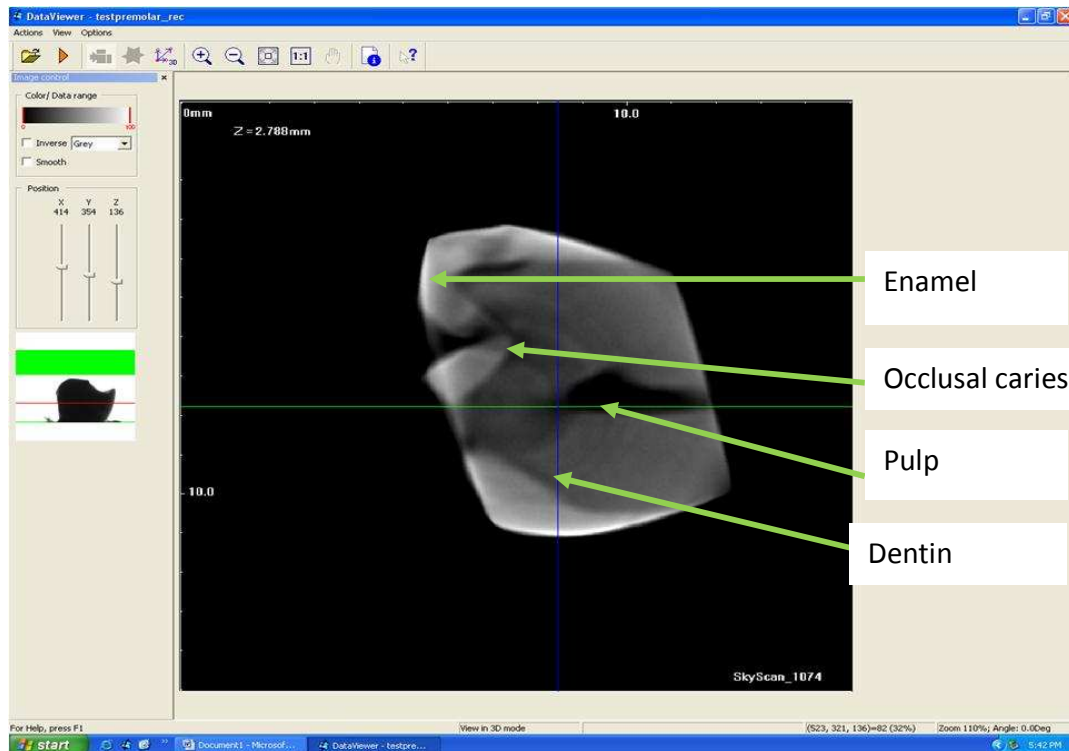


Figure 5. Histology of one of the sample tooth

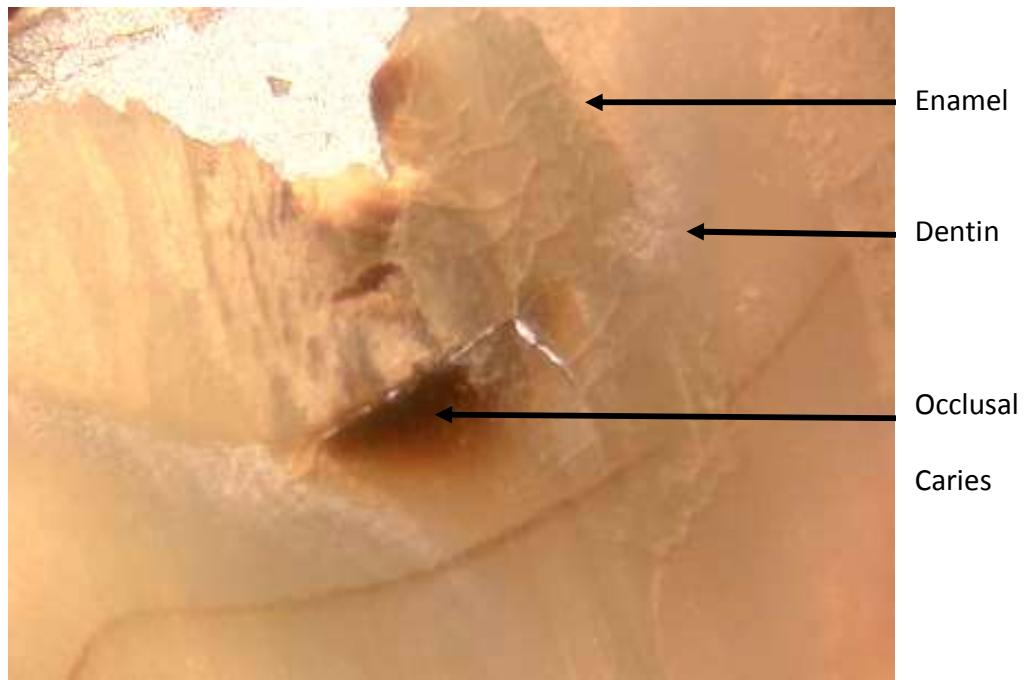
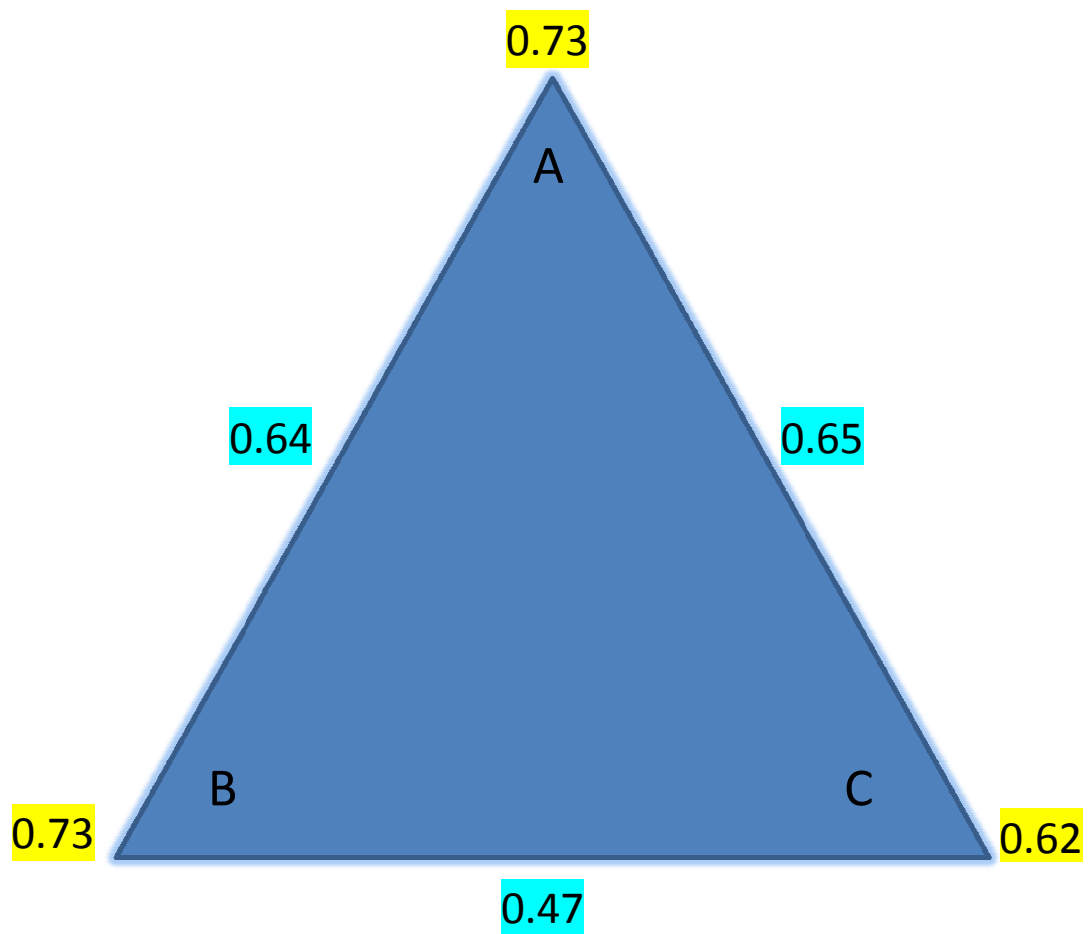




Figure 8: Interobserver and Intraobserver Kappa Statistics for Micro-CT



- Yellow- Intra-observer values
- Blue- Inter-observer values

Table 1. Caries detection accuracy as measured by  $A_z$  of the ROC analysis

Observer	BW $A_z$	CBA $_z$
1	<b>0.63</b>	<b>0.67</b>
2	<b>0.65</b>	<b>0.70</b>
3	<b>0.70</b>	<b>0.69</b>
4	<b>0.74</b>	<b>0.77</b>
5	<b>0.56</b>	<b>0.75</b>
6	<b>0.62</b>	<b>0.74</b>
Mean	0.65	0.72
SD	0.06	0.04

Table 2: ANOVA for area under the curve

Source	Sum of square	df	f-ratio	p-value
Observer	0.013	5	1.01	0.50
Modality	0.015	1	5.53	0.07
Error	0.014	5		

df= degrees of freedom

Table 3: Sensitivity, specificity and the p values for 6 observers and 2 modalities

Obs	BW Sens	CB Sens	BW Spec	CB Spec
1	<b>66.67</b>	<b>77.78</b>	<b>63.34</b>	<b>51.52</b>
2	<b>77.78</b>	<b>74.07</b>	<b>48.48</b>	<b>66.67</b>
3	<b>51.85</b>	<b>70.37</b>	<b>78.79</b>	<b>54.55</b>
4	<b>62.96</b>	<b>66.67</b>	<b>78.79</b>	<b>69.7</b>
5	<b>51.85</b>	<b>51.85</b>	<b>54.55</b>	<b>84.85</b>
6	<b>62.96</b>	<b>81.48</b>	<b>51.52</b>	<b>63.64</b>
<b>Mean</b>	62.35	70.37	62.58	65.16
<b>SD</b>	9.78	10.48	13.50	11.93
<b>p value<sup>1</sup></b>	<b>0.17</b>			<b>0.57</b>

<sup>1</sup> As calculated by Wilcoxon Exact rank sum test

Obs = observer, BW=bitewing, CB=conebeam, Sens= sensitivity, Spec=specificity

Table 4: Average Weighted Kappa values representing interobserver and intraobserver reliability

Modality	Interobserver Kappa	Intraobserver Kappa
	Mean .SD	Mean .SD
<b>Weighted BW</b>	0.40 0.09	0.68 0.10
<b>Weighted CB</b>	0.283. 0.06	0.65 0.12

Table 5: Likert scale for Observation sessions

Number	Presence or absence of Caries
1	Caries definitely absent
2	Caries probably absent
3	Unsure if caries is absent or present
4	Caries probably present
5	Caries definitely present

Table 6: Abstracts on Comparison of Micro-CT and Histology in Caries detection

<b>Abstract Title</b>	<b>Authors</b>	<b>Year</b>	<b>Journal/Meeting</b>	<b>Summary</b>
Application of Desktop Micro-CT Imaging as Gold Standard in Caries Diagnosis	Bottenberg et al.	2003	81 <sup>st</sup> session of the IADR	Skyscan 1072 Micro-CT images were compared to clinical and histological evaluations of 16 extracted teeth. Micro-CT analysis demonstrated good agreement with histological measurements ( $r=0.89$ , $p<0.001$ ), whilst the clinical evaluations were found to be much less correlated with the micro-CT analysis ( $r=0.39$ , $p<0.001$ ) and histological data ( $r=0.42$ , $p<0.001$ )
A comparison of Micro-CT and a novel histological technique validation for caries detection	Wang et al.	2005	J of Dental Health, vol55(4),pg 321	TOSCANER-31300 $\mu$ hd, Toshiba Micro-CT was compared to a novel histological technique for occlusal and proximal caries detection in posterior extracted teeth. Micro-CT could detect caries on occlusal surfaces in excellent agreement with histology (Kappa for Micro-CT and histology was 0.85 and 0.79) using 3 and 5 grade scales
Comparison of Micro-CT and Histological Technique Validation for Surface Lesions	Wang, Longbottom et al	2006	IADR(International Association for Dental research)	TOSCANER-31300 $\mu$ hd, Toshiba Micro-CT was compared to histology for proximal caries detection in 18 posterior extracted teeth. The Kappa value for Micro-CT and histological validation was 0.67 and 0.71 using D1 and 5 grade scales. Micro-CT could detect proximal surface lesions with good agreement with histology and was able to detect natural lesions at 100 $\mu$ m depth and beyond.

Comparison of Micro-CT and Histology as Gold standards in Radiographic Caries Diagnosis	Berkhout et al.	2008	EADMFR(European Academy of Dento MaxilloFacial Radiology)	SCANCO 40 Micro-CT images were compared with histological sections of 32 proximal carious lesions as gold standards in radiographic caries diagnosis. Preliminary results showed substantial agreement (Kappa=0.60) between Micro-CT images and histology
---	-----------------	------	---	---



## REFERENCES

1. Marthaler TM. Changes in dental caries 1953-2003. *Caries Res.* 2004 ;38(3):173-181.
2. Konig KG. Clinical Manifestations and treatment of Caries from 1953 to Global Changes in the 20th Century. *Caries Res.* 2004 ;38(3):168-172.
3. Petersen PE. The World Oral Health Report 2003: continuous improvement of oral health in the 21st century &#x2013; the approach of the WHO Global Oral Health Programme. *Community Dentistry And Oral Epidemiology.* 2003 ;31(s1):3-24.
4. Brown LJ, Robert H. Selwitz. The Impact of Recent Changes in the Epidemiology of Dental Caries on Guidelines for the Use of Dental Sealants. *Journal of Public Health Dentistry.* 1995 ;55(5):274-291.
5. Anderson M. Risk assessment and epidemiology of dental caries: review of the literature. *Pediatr Dent.* 2002 Oct ;24(5):377-385.
6. De Grauwe A, Aps JK, Martens LC. Early Childhood Caries (ECC): what's in a name? *Eur J Paediatr Dent.* 2004 Jun ;5(2):62-70.
7. Beltrán-Aguilar ED, Barker LK, Canto MT, Dye BA, Gooch BF, Griffin SO, Hyman J, Jaramillo F, Kingman A, Nowjack-Raymer R, Selwitz RH, Wu T. Surveillance for dental caries, dental sealants, tooth retention, edentulism, and enamel fluorosis--United States, 1988-1994 and 1999-2002. *MMWR Surveill Summ.* 2005 Aug 26;54(3):1-43.
8. Petersen PE, Yamamoto T. Improving the oral health of older people: the approach of the WHO Global Oral Health Programme. *Community Dent Oral Epidemiol.* 2005 Apr ;33(2):81-92.
9. Caufield PW, Griffen AL. DENTAL CARIES: An Infectious and Transmissible Disease. *Pediatric Clinics of North America.* 2000 Oct 1;47(5):1001-1019.
10. Bader JD, Shugars DA, Bonito AJ. Systematic reviews of selected dental caries diagnostic and management methods. *Journal of Dental Education.* 2001 ;65(10):960-968.
11. Horowitz A. A Report on the NIH Consensus Development Conference on Diagnosis and Management of Dental Caries Throughout Life. *Journal of Dental Research.* 2004 Jul 1;83(suppl\_1):C15-17.
12. Kuhnisch J, Dietz W, Stosser L, Hickel R, Heinrich-Weltzien R. Effects of dental probing on occlusal surfaces-A scanning electron microscopy evaluation. *Caries Res.* 2007 ;41(1):43-48.

13. Lussi A. Comparison of different methods for the diagnosis of fissure caries without cavitation. *Caries Res.* 1993 ;27(5):409-416.
14. Dorothy McComb BDS, Tam LE. Diagnosis of occlusal caries: Part I. Conventional methods. *J Can Dent Assoc.* 2001 ;67(8):454-7.
15. Pretty IA, Pender N, Edgar WM, Higham SM. The in vitro detection of early enamel de- and re-mineralization adjacent to bonded orthodontic cleats using quantitative light-induced fluorescence. *The European Journal of Orthodontics.* 2003 ;25(3):217-223.
16. Zandona AF, Zero DT. Diagnostic tools for early caries detection. *J Am Dent Assoc.* 2006 Dec 1;137(12):1675-1684.
17. Tam LE, McComb D. Diagnosis of occlusal caries: Part II. Recent diagnostic technologies. *Journal of the Canadian Dental Association.* 2001 ;67(8):459-464.
18. Shi XQ, Welander U, Angmar-Månsson B. Occlusal caries detection with KaVo DIAGNOdent and radiography: an in vitro comparison. *Caries Res.* 2000 ;34:151-158.
19. Lussi A, Imwinkelried S, Pitts NB, Longbottom C, Reich E. Performance and reproducibility of a laser fluorescence system for detection of occlusal caries in vitro. *Caries Res.* 1999 ;33:261-266.
20. Bader JD, Shugars DA. A systematic review of the performance of a laser fluorescence device for detecting caries. *The Journal of the American Dental Association.* 2004 ;135(10):1413-1426.
21. Sheehy EC, Brailsford SR, Kidd EAM, Beighton D, Zoitopoulos L. Comparison between visual examination and a laser fluorescence system for in vivo diagnosis of occlusal caries. *Caries Res.* 2001 ;35:421-426.
22. Lussi A, Megert B, Longbottom C, Reich E, Francescut P. Clinical performance of a laser fluorescence device for detection of occlusal caries lesions. *European Journal of Oral Sciences.* 2001 ;109(1):14-19.
23. Anttonen V, Seppä L, Hausen H. Clinical study of the use of the laser fluorescence device DIAGNOdent for detection of occlusal caries in children. *Caries Res.* 2003 ;37:17-23.
24. Longbottom C, Huysmans MC. Electrical measurements for use in caries clinical trials. In: *Journal of dental research. International and American Associations for Dental Research*; 2004. p. 76-79.

25. Ashley PF, Ellwood RP, Worthington HV, Davies RM. Predicting occlusal caries using the electronic caries monitor. *Caries Res.* 2000 ;34:201-203.
26. Souza-Zaroni WC, Ciccone JC, Souza-Gabriel AE, Ramos RP, Corona SAM, Palma-Dibb RG. Validity and reproducibility of different combinations of methods for occlusal caries detection: an in vitro comparison. *Caries Res.* 2006 ;40(3):194-201.
27. Ricketts DNJ, Kidd EAM, Smith BGN, Wilson RF. Clinical and radiographic diagnosis of occlusal caries. a study in vitro. *Journal of Oral Rehabilitation.* 1995 ;22(1):15-20.
28. Kidd EA, Ricketts DN, Pitts NB. Occlusal caries diagnosis: a changing challenge for clinicians and epidemiologists. *J Dent.* 1993 Dec ;21(6):323-331.
29. Wenzel A. Digital radiography and caries diagnosis. *Dentomaxillofac Radiol.* 1998 Jan 1;27(1):3-11.
30. Kositbowornchai S, Basiw M, Promwang Y, Moragorn H, Sooksuntisakoonchai N. Accuracy of diagnosing occlusal caries using enhanced digital images. *Dentomaxillofac Radiol.* 2004 Jul 1;33(4):236-240.
31. Scarfe WC, Farman AG, Sukovic P. Clinical Applications of Cone-Beam Computed Tomography in Dental Practice. *J Can Dent Assoc.* 2006 ;72(1):75-80.
32. Ludlow JB, Ivanovic M. Comparative dosimetry of dental CBCT devices and 64-slice CT for oral and maxillofacial radiology. *Oral Surgery, Oral Medicine, Oral Pathology, Oral Radiology, and Endodontology.* 2008 Jul ;106(1):106-114.
33. Stock SR. X-ray microtomography of materials. *International Materials Reviews.* 1999 ;44(4):141-164.
34. Ismail A. Visual and Visuo-tactile Detection of Dental Caries. *Journal of Dental Research.* 2004 Jul 1;83(suppl\_1):C56-66.
35. Wenzel A. Bitewing and Digital Bitewing Radiography for Detection of Caries Lesions. *Journal of Dental Research.* 2004 Jul 1;83(suppl\_1):C72-75.
36. Tyndall DA, Clifton TL, Webber RL, Ludlow JB, Horton RA. TACT Imaging of primary caries. *Oral Surgery, Oral Medicine, Oral Pathology, Oral Radiology, and Endodontology.* 1997 Aug ;84(2):214-225.
37. Shi XQ, Han P, Welander U, Angmar-Mansson B. Tuned-aperture computed tomography for detection of occlusal caries. *Dentomaxillofac Radiol.* 2001 Jan 1;30(1):45-49.

38. Abreu Junior M, Tyndall DA, Platin E, Ludlow JB, Phillips C. Two- and three-dimensional imaging modalities for the detection of caries. A comparison between film, digital radiography and tuned aperture computed tomography (TACT). *Dentomaxillofac Radiol.* 1999 May 1;28(3):152-157.
39. Pitts N. Clinical diagnosis of dental caries: a European perspective. *J Dent Educ.* 2001 Oct 1;65(10):972-978.
40. van Daatselaar A, Tyndall D, van der Stelt P. Detection of caries with local CT. *Dentomaxillofac Radiol.* 2003 Jul 1;32(4):235-241.
41. Kalathingal SM, Mol A, Tyndall DA, Caplan DJ, Hill C. In vitro assessment of cone beam local computed tomography for proximal caries detection. *Oral Surgery, Oral Medicine, Oral Pathology, Oral Radiology, and Endodontology.* 2007 Nov ;104(5):699-704.
42. Tsuchida R, Araki K, Okano T. Evaluation of a limited cone-beam volumetric imaging system: comparison with film radiography in detecting incipient proximal caries. *Oral Surgery, Oral Medicine, Oral Pathology, Oral Radiology, and Endodontology.* 2007 Sep ;104(3):412-416.
43. Kantor M, Zeichner S, Valachovic R, Reiskin A. Efficacy of dental radiographic practices: options for image receptors, examination selection, and patient selection. *J Am Dent Assoc.* 1989 Aug 1;119(2):259-268.
44. Kositbowornchai S, Basiw M, Promwang Y, Moragorn H, Sooksuntisakoonchai N. Accuracy of diagnosing occlusal caries using enhanced digital images. *Dentomaxillofac Radiol.* 2004 Jul 1;33(4):236-240.
45. Tyndall DA, Ludlow JB, Platin E, Nair M. A comparison of kodak etkaspeed plus film and the siemens sidexis digital imaging system for caries detection using receiver operating characteristic analysis. *Oral Surgery, Oral Medicine, Oral Pathology, Oral Radiology, and Endodontology.* 1998 Jan ;85(1):113-118.
46. Akkaya N, Kansu O, Kansu H, Cagirankaya L, Arslan U. Comparing the accuracy of panoramic and intraoral radiography in the diagnosis of proximal caries. *Dentomaxillofac Radiol.* 2006 May 1;35(3):170-174.
47. Viera AJ, Garrett JM. Understanding interobserver agreement: the kappa statistic. *Fam Med.* 2005 ;37(5):360-3.
48. Hintze H, Frydenberg M, Wenzel A. Influence of number of surfaces and observers on statistical power in a multiobserver ROC radiographic caries detection study. *Caries Res.* 2003 ;37(3):200-205.

49. Farman AG. ALARA still applies. *Oral Surgery, Oral Medicine, Oral Pathology, Oral Radiology, and Endodontology*. 2005 Oct ;100(4):395-397.
50. Ludlow J, Davies-Ludlow L, Brooks S, Howerton W. Dosimetry of 3 CBCT devices for oral and maxillofacial radiology: CB Mercuray, NewTom 3G and i-CAT. *Dentomaxillofac Radiol*. 2006 Jul 1;35(4):219-226.
51. Ludlow JB, Davies-Ludlow LE, White SC. Patient Risk Related to Common Dental Radiographic Examinations: The Impact of 2007 International Commission on Radiological Protection Recommendations Regarding Dose Calculation. *Journal of the American Dental Association*. 2008 ;139(9):1237-1243.
52. Wenzel A. Digital imaging for dental caries. *Dent. Clin. North Am*. 2000 Apr ;44(2):319-338, vi.
53. Wenzel A, Hintze H. The choice of gold standard for evaluating tests for caries diagnosis. *Dentomaxillofac Radiology*. 1999 ;28(3):132-136.
54. Wenzel A, Hintze H. Comparison of microscopy and radiography as gold standards in radiographic caries diagnosis. *Dentomaxillofac Radiol*. 1999 May 1;28(3):182-185.
55. Kawato T, Furuta M, Ogiso B, Yamashita Y, Kitami S, Iida T, Kuwabara A, Maeno M. Evaluating Occlusal Caries Using a Non-Destructive Micro-CT Examination. *Journal of Hard Tissue Biology*. 2009 ;18(1):35-39.
56. Plotino G, Grande NM, Pecci R, Bedini R, Pameijer CH, Somma F. Three-dimensional imaging using microcomputed tomography for studying tooth macromorphology. *J Am Dent Assoc*. 2006 Nov 1;137(11):1555-1561.
57. Hayakawa T, Mishima H, Yokota I, Sakae T, Kozawa Y, Nemoto K. Application of high resolution microfocus X-ray CT for the observation of human tooth. *Dent Mater J*. 2000 Mar ;19(1):87-95.
58. Rhodes JS, T. R. Pitt Ford, J. A. Lynch, P. J. Liepins, R. V. Curtis. Micro-computed tomography: a new tool for experimental endodontology. *International Endodontic Journal*. 1999 ;32(3):165-170.
59. Dowker SEP, Davis GR, Elliott JC. X-ray microtomography : Nondestructive three-dimensional imaging for in vitro endodontic studies. *Oral Surgery, Oral Medicine, Oral Pathology, Oral Radiology, and Endodontology*. 1997 Apr ;83(4):510-516.
60. Paschos E, Kleinschrodt T, Clementino-Luedemann T, Huth KC, Hickel R, Kunzelmann KH, Rudzki-Janson I. Effect of different bonding agents on prevention of enamel

demineralization around orthodontic brackets. American Journal of Orthodontics & Dentofacial Orthopedics. 2009 ;135(5):603-612.

61. CLEMENTINO-LUEDEMANN T, KUNZELMANN K. Mineral concentration of natural human teeth by a commercial micro-CT. Dental materials journal. 2006 ;25(1):113-119.
62. Wong FSL, Anderson P, Fan H, Davis GR. X-ray microtomographic study of mineral concentration distribution in deciduous enamel. Archives of Oral Biology. 2004 ;49(11):937-944.
63. Tsuchida R, Araki K, Okano T. Evaluation of a limited cone-beam volumetric imaging system: comparison with film radiography in detecting incipient proximal caries. Oral Surgery, Oral Medicine, Oral Pathology, Oral Radiology, and Endodontology. 2007 Sep ;104(3):412-416.
64. Hahn SK, Kim JW, Lee SH, Kim CC, Hahn SH, Jang KT. Microcomputed tomographic assessment of chemomechanical caries removal. Caries Res. 2004 ;38(1):75-78.
65. Tyndall DA, Rathore S. Cone-Beam CT Diagnostic Applications: Caries, Periodontal Bone Assessment, and Endodontic Applications. Dental Clinics of North America. 2008 ;52(4):825-841.