

LONG-TERM POST-TREATMENT STABILITY OF THE HERBST APPLIANCE

Mark H Kaley DDS

A thesis submitted to the faculty of the University of North Carolina at Chapel Hill in partial fulfillment of the requirements for the degree of Master of Science in the Department of Orthodontics in the School of Dentistry

Chapel Hill
2006

Approved by
Advisor: Dr. Ceib Phillips
Reader: Dr. J.F.C. Tulloch
Reader: Dr. John Christensen

ABSTRACT

MARK H. KALEY: Long-term post-treatment stability of the Herbst Appliance

(Under the direction of Dr. Ceib Phillips)

The Herbst appliance is an adjunctive treatment for the correction of Class II malocclusions. Previous studies have indicated that the correction following the end of treatment frequently relapses. The purpose of this study was to assess the cephalometric changes during and following a treatment protocol of 12 months of Herbst appliance treatment followed by fixed appliance treatment, and 12 months of retention. The changes from the end of treatment to the retention recall were, on average, very small. The only statistically significant changes (Mixed linear model; $P < 0.05$) observed were relapse in the ANB angle (-0.31° ; $sd=0.88$), overjet (0.49mm ; $sd=0.94$) and overbite (0.55mm ; $sd=0.98$). These changes were considered not clinically significant. The Class II correction effected by this treatment protocol appears stable one year out of treatment.

DEDICATION

To Dr. Phillips, Dr. Tulloch, and Dr. Christensen, whose hand-holding, suggestions, and guidance have made this paper possible,

To all of the faculty and staff of the Department of Orthodontics, who have given me the finest training I could have ever dreamed of,

To Debbie Price, whose patience and assistance have been invaluable,

To all of my fellow residents for their friendship and camaraderie over the past three years,

To Erol, Steve, Jason, Jannie, and Karen, whose laughter and fellowship have made the past 33 months (plus four years!) so much fun,

To my parents, Martha and Jim Kaley, whose love and support have inspired me to be the best person I can be,

To my wife, my best friend, and the love of my life, Lorin, who has stood by me and made me smile even in the most difficult times,

And to God, who has granted me innumerable blessings in my life,

This work is dedicated.

TABLE OF CONTENTS

	Page
LIST OF TABLES.....	vi
LIST OF FIGURES.....	vii
LIST OF ABBREVIATIONS.....	viii
SECTION	
I. LITERATURE REVIEW.....	1
A. History.....	1
B. Effects.....	2
C. Mechanism.....	5
D. Comparison to other treatments.....	8
E. Stability.....	10
F. Conclusion.....	17
G. References.....	19
II. JOURNAL ARTICLE.....	22
A. Introduction.....	22
B. Methods.....	23
C. Results.....	26
D. Discussion.....	30
E. Conclusion.....	36

F. Tables.....	37
G. Figures.....	39
H. Appendix A.....	45
I. References.....	47

LIST OF TABLES

Table	Page
1. Demographic characteristics of subjects prior to the start of treatment.....	37
2. Percentage of subjects in various stages of growth prior to the start of treatment.....	37
3. Descriptive Statistics for the Pre-treatment Cephalometric Measures.....	37
4. Descriptive Statistics for the changes in the anteroposterior position between successive time points.....	37
5. Descriptive Statistics for the changes in vertical position between successive time points.....	38
6. Descriptive Statistics for the changes in dental position between successive time points.....	38

LIST OF FIGURES

Figure	Page
1. 26-point cephalometric analysis model.....	39
2. Box plots of descriptive statistics at four time points for the measures B point to Nasion perpendicular and ANB angle.....	40
3. Box plots of changes in measurements between successive time point for the measures B point to Nasion perpendicular and ANB angle.....	40
4. Percentage of patients with changes greater than 2° or 2mm for the measures B point to Nasion perpendicular and ANB angle.....	41
5. Box plots of descriptive statistics at four time points for the measures mandibular plane angle and occlusal plane angle.....	41
6. Box plots of changes in measurements between successive time point for the measures mandibular plane angle and occlusal plane angle.....	42
7. Percentage of patients with changes greater than 2° for the measures mandibular plane angle and occlusal plane angle.....	42
8. Box plots of descriptive statistics at four time points for the measures overjet and overbite.....	43
9. Box plots of changes in measurements between successive time point for the measures overjet and overbite.....	43
10. Percentage of patients with changes greater than 2mm for the measures overjet and overbite.....	44

LIST OF ABBREVIATIONS

Description	Abbreviation
A point to Nasion to B point angle.....	ANB
Average.....	ave
B point to Nasion perpendicular.....	B pt to N perp
Bilateral sagittal split osteotomy.....	BSSO
Health Insurance Portability and Accountability Act.....	HIPAA
Lower incisor to mandibular plane angle.....	L1-MPA
Lower incisor to sella-nasion.....	L1-SN
Magnetic resonance imaging.....	MRI
Mandibular plane angle.....	MPA
Millimeter.....	mm
Palatal plane to Mandibular plane angle.....	PP-MPA
Pogonion to Nasion perpendicular.....	Pog to N perp
Sella-Nasion to Mandibular plane angle.....	SN-MPA
Sella-Nasion to Occlusal plane.....	SN-OP
Sella-Nasion to Palatal plane.....	SN-PP
Sella to Nasion to B point angle.....	SNB
Soft tissue B point to Nasion perpendicular.....	StB to N perp
Standard deviation.....	sd
Temporomandibular joint.....	TMJ
Treatment.....	Tx
Upper incisor to Sella-Nasion.....	U1-SN

SECTION I

Literature Review

A. History

In 1905, at the Fifth International Dental Congress in Berlin, Emil Herbst introduced a new appliance for the correction of Class II malocclusions (Pancherz, 1985). A German professor, Herbst described a device that consisted of gold alloy crowns cemented to the maxillary first molars and mandibular first premolars. A telescoping piston was soldered to the crowns and connected each maxillary molar to its corresponding mandibular premolar (Hanks, 2003). The pistons were constructed to protrude the mandible into a Class I jaw relationship. Herbst thought of the appliance as a temporary joint as the bones of the TMJ adapted to the new position of the mandible (Matasa, 1995). He would initially publish the drawings of his device, which he called an artificial hinge, in 1910 as part of his *Atlas und Grundriss der Zahnartlichen Orthopadie* (Atlas and Compendium of Dental Orthopedics) (Hanks, 2003). A series of articles in the *Zahnarztliche Rundschau* in 1934 followed detailing Herbst's clinical experiences with this "bite-jumping device" (Pancherz, 1985). Shortly thereafter, however, the treatment method virtually disappeared for more than forty years.

In 1979, Hans Pancherz renewed interest in this country in the Herbst bite jumping appliance through an article in the *American Journal of Orthodontics* (Pancherz, 1979). Since that time, the Herbst has become one of the most popular treatment choices of clinicians for the correction of Class II malocclusions due primarily to its lack of reliance on

patient compliance (O'Brien, 2003). Numerous studies have been conducted to determine the effects, mechanisms, and stability of the Herbst appliance.

B. Effects

Pancherz's 1979 study demonstrated apparently significant correction to the Class II pattern in dental, skeletal, and facial profile relationships. Conducted on ten Class II, Division 1 skeletally immature boys, the study examined lateral cephalometric radiographs, plaster casts, and TMJ radiographs taken before and immediately after six months of Herbst treatment. Pancherz collected ten boys with similar malocclusions and skeletal maturity to act as controls during the six month treatment time.

After six months of Herbst therapy, the group treated with the Herbst showed Class I to super-Class I molar relationships and an average decrease in overjet and overbite of 3.8mm and 2.5mm, respectively. No significant changes occurred in the control subjects. The ANB angle in the treatment group improved (towards Class I) an average of 2° due to both a reduction in the SNA angle (ave. 0.7°) and an increase of the SNB angle (ave. 1.2°). These changes were significantly greater than the control group. An improvement of the convex profile was seen in all treated subjects which was significantly greater than the minimal movement in the control subjects. Pancherz concludes that the Herbst appliance is suitable to treat Class II patients with a retrognathic mandible and retroclined lower incisors and who are just prior to the peak of growth (Pancherz, 1979).

Three years later, Pancherz investigated the vertical effects of the Herbst on the dentoalveolar complex. Collecting 42 Class II, Division 1 patients with a deep anterior overbite, Pancherz treated 22 with the Herbst and kept 20 as control subjects. At the

conclusion of six months of treatment, he examined lateral cephs and found that the treated subjects had a “significant” reduction of the overbite and a steepening of the angulation of the occlusal plane when compared with the controls. While he noted a limited effect on the vertical positions of the maxillary and mandibular jaws, Pancherz did see an increase in lower facial height that he believed clinicians should be aware of when embarking on Herbst treatment (Pancherz, 1982).

Still at the forefront of Herbst research, Pancherz attempted to further define his success with the appliance in a paper published in 1985. Apparently using the same subjects and controls as the 1982 study, he noted several dental and skeletal effects that helped determine the sources of Class II correction. Molar correction from Class II to Class I (ave. 6.7mm) came from a combination of dental (ave. 3.8mm) and skeletal (ave 2.9mm) movement. Maxillary molars moved distally an average of 2.8mm and mandibular molars moved mesially an average of 1.0mm. The Herbst appliance demonstrated a restraining effect on the maxilla, distalizing it an average of 0.4mm. Pancherz noted a three-fold increase in mandibular unit length when compared to controls that contributed to the average 2.5mm forward movement of the lower jaw. This study indicated that the Herbst appliance affects both dental and skeletal components in growing patients and could significantly modify the facial structure of patients (Pancherz, 1985).

The previous studies all looked at the Herbst as the sole treatment for Class II malocclusion. However, modern use of the Herbst typically includes a second phase of treatment involving fixed appliances (Dischinger, 1995). A 1998 investigation by Lai and McNamara evaluated the effects of the Herbst when used as part of a two-phase treatment plan. Using an acrylic-splint Herbst design, the researchers treated 20 boys and 20 girls first

with the Herbst appliance and then with fixed edgewise appliances. These subjects were then compared to norms found in the University of Michigan Elementary and Secondary School Growth Study that were matched for the subjects' gender, initial age, and duration of treatment. In this study, the mandibular unit length increase was still greater than the controls, but much smaller than Pancherz's earlier findings (ave. 1mm versus 3.2mm). In addition, the acceleration of mandibular growth seen during Herbst treatment was followed by a slowing of growth during edgewise treatment that was less than the controls. Significant anteroposterior dentoalveolar rebound was seen during the fixed appliance therapy as well. While the appliance design was different from Pancherz's works, a comparison of results of this study with previous papers suggests that the correction seen immediately after the Herbst is removed may not be as stable as once thought (Lai and McNamara, 1998).

Pancherz collaborated with Sabine Ruf in 1999 to investigate the effects of the Herbst on young adult Class II patients. While earlier studies showed the success in Class II correction when used in growing patients (Pancherz, 1979), this study focused on 14 subjects who had past the peak of their growth according to hand-wrist films. They were compared to a group treated with the Herbst who were in the acceleration phase of the pubertal growth spurt. The subjects were treated to an average of 8.5 months, or until the incisors were overcorrected to an edge-to-edge relationship. Lateral cephs taken before and after treatment showed that both groups had greater dental contribution to Class II correction than skeletal. The young adult group, however, had significantly less skeletal contribution than the adolescent group to molar correction (25% versus 41%) indicating that the growing group was receiving greater skeletal modification. Most striking was the fact that the average improvement of the facial profile in both groups did not significantly differ despite this

discrepancy in skeletal change. Ruf and Pancherz added to the arsenal of Herbst advocates by concluding that the Herbst could be used on borderline young adult patients as a possible alternative to surgery (Ruf and Pancherz, 1999).

Two years later, Manfredi, Cimino, Trani, and Pancherz further studied the skeletal effects of the appliance on patients that were compared to European cephalometric norms. 50 patients (25 boys, 25 girls) were treated with the Herbst appliance for 6-8 months and cephs taken before and after treatment were analyzed to determine changes in the skeleton. The researchers noted a change in both the ramus and body of the mandible in most subjects. As a whole, the mandible exhibited a strong forward repositioning (ANB increase of 2.44°) without an opening of the gonial angle. Results were more striking in boys than girls, with an increase in mandibular basal length as well as an increase in ramus height (girls simply saw an increase in ramus height). This study concluded that short-term Herbst treatment could be efficacious for skeletal correction of Class II malocclusions (Manfredi et al, 2001).

The previous studies demonstrated that the Herbst appliance was effective in correcting Class II malocclusions. Through a combination of changes in the dental and skeletal relationships in both jaws, the appliance affected positive changes to the facial profile to give patients a more Class I appearance. The question remained – how did the Herbst achieve this change?

C. Mechanism

In 1998, Ruf and Pancherz used MRI technology to look at the adaptation of the temporomandibular joint during Herbst treatment. Rather than “growing” a mandible, the pair hypothesized that the correction of Class II malocclusion came from some combination

of condylar and glenoid fossa remodeling in response to treatment. The researchers used 15 consecutive cases that were treated with the Herbst for an average of seven months and looked at MRI's and lateral cephs taken before treatment, at the start of treatment, 6-12 weeks into treatment, and post-treatment to determine what changes took place. Out of 30 condyles, 29 showed remodeling at the posterior-superior border in the 6-12 week radiographs. 22 of 30 fossas showed remodeling along the anterior surface of the postglenoid spine and the researchers found that this movement was apparently preceded by the condylar remodeling. On average, the positional relationship between the condyle and fossa was unaffected by treatment, meaning that the condyle remained in the same position in the fossa throughout the study period. Most striking was the fact that "effective condylar growth" (the sum of condylar remodeling, fossa remodeling, and change in the condyle-fossa relationship) was five times larger when compared to Bolton standards. This study indicated that the advancement of the mandible seen in Herbst therapy is largely due to significant structural changes in the TMJ (Ruf and Pancherz, 1998).

Ruf and Pancherz's study did not attempt to determine absolutely how these changes come about, but instead offer a brief review of the literature dealing with the biomechanics of bone remodeling compared with their own MRI findings. They suggest that the response of the condylar cartilage is a result of a change in the function of the superior head of the lateral pterygoid muscle (McNamara, 1973) and a change in the loading of the condyle (Kantomaa and Hall, 1988). Ruf and Pancherz's MRI results seem to have agreed with earlier histological studies showing an area of hyperplasia in the prechondroblastic-chondroblastic region of the posterior and posterior-superior border of the condyle (McNamara and Carlson, 1979). Similar to earlier studies, apposition of bone in the anterior region of the glenoid

fossa seemed centered around the posterior fibrous tissue of the articular disc (Woodside et al, 1987), suggesting that bone response is due to increased tensile forces on the periosteum of the post-glenoid spine (Ruf and Pancherz, 1998).

Two years later, John Voudouris and Mladen Kufinec proposed an alternative theory to bony changes in the TMJ that they called “growth relativity.” The researchers asserted that the changes were due to tension not from the muscular attachment to the condylar head, but of the retrodiskal tissues and capsule and an alteration of flow in the synovial fluid.

Analyzing the results from several studies, they suggested that the glenoid fossa responds as well from a transduction of these forces and remodels along with the condyle (Voudouris and Kufinec, 2000).

In 2003, Popowich et al conducted a new review of the literature to determine what earlier studies actually found. Their results put in doubt the accepted theory that the Herbst made significant changes to the bony structures of the TMJ. Systematically sifting through the previous 40 years of research, the Canadians found five articles (four using MRIs and one using tomograms) that fit their criteria. The MRI studies showed no evidence of osseous changes or an alteration of condylar position. The tomographic study showed minor changes in the position of the condyle. The researchers concluded that more studies should be conducted to determine what skeletal changes, if any, take place in response to Herbst treatment (Popowich et al, 2003).

Later that same year, a group of researchers led by John Voudouris published a two-part study using various experimental methods to investigate the results of Herbst treatment on non-human primates. The group used electromyographic electrodes in the muscles of mastication, Bjork-style implants, and fluorescence microscopy to determine the changes in

both skeletal and muscular aspects during Herbst treatment. Part one illustrated a significant amount of bone formation on the anterior fossa (an average of 1.2mm in 12 weeks) that was in an inferior-anterior direction, in contrast to an inferior-posterior direction in control subjects. Part two of the study found an increase in the growth of the condyle demonstrated with both the implant method and histological studies and a significant amount of new bone when compared to controls. The researchers concluded that the Herbst produced “consistent and reproducible” changes in the condyle and fossa (Voudouris et al, 2003).

D. Comparison to other treatments

The Herbst appliance is just one of many treatment protocols designed to correct Class II malocclusions. The effects of several other appliances have been studied and compared with the outcomes of the Herbst appliance.

In August of 1990, McNamara, Howe, and Dischinger compared the Class II corrective potential of the Herbst appliance with the Frankel appliance. 45 patients treated with an acrylic Herbst were compared to 41 patients treated with a primarily tissue-borne Frankel 2 using serial cephalometric radiographs. The subjects were compared to 21 untreated controls to assess effective changes. According to their results, both appliances had positive effects on growth, with significant increases in mandibular length and lower facial height when compared to the control subjects. The most significant difference between the treatment outcomes was a tendency for the Herbst group to have greater dentoalveolar movements (McNamara et al, 1990).

The pendulum, an appliance popular for the distalization of maxillary molars, was matched against the Herbst by Burkhardt, McNamara, and Baccetti in 2003. Cephalometric

radiographs taken before and after treatment were examined in a group of 90 patients (30 with acrylic Herbst, 30 with stainless steel Herbst, and 30 with pendulum). The results showed no statistically significant difference in mandibular growth between the groups, but both Herbst groups had slightly greater mandibular projection than the pendulum group. The stainless steel crown Herbst design exhibited more of an anterior movement on the mandibular dentition than the other groups (Burkhardt et al, 2003).

A large group led by Kevin O'Brien compared the Twin-block appliance with the Herbst in August of 2003. Seventeen hospital-based orthodontic specialists in the United Kingdom collected 215 patients that were randomly assigned to receive treatment with one of the two methods. The group found no significant differences in skeletal or dental changes between the two appliances. No difference in treatment time existed between the two subject groups either, but more appointments (an average of 3) were needed in the Herbst group due to repeated breakage of the appliance. However, even with this extra time, a lower failure-to-complete rate existed for the Herbst group (12.9%) when compared to the Twin-block group (33.6%). The study concluded with the thought that, due to greater cooperation rates, the Herbst appliance may be the appliance of choice for correction of Class II malocclusion (O'Brien et al, 2003).

While a debate still exists on the skeletal changes affected by the Herbst, most of the reviewed studies seem to indicate some measure of bone reformation along the condylar-fossa junction and certainly a noticeable correction to the existing Class II malocclusion. What is not clear through these studies is how stable this new bone is in the long term. Do the changes contributing to Class II correction remain constant when revisited at a later date?

E. Stability

Many earlier studies that investigated the effects and mechanisms of the Herbst appliance reported positive Class II correction immediately at the end of treatment. However, none of these looked at the long-term correction to determine how stable these changes were. A host of researchers have looked at this issue using various methods to find if this treatment of Class II that is popular with clinicians has a lasting effect on the dental and skeletal patterns.

In 1990, Pancherz and Fackel looked at the skeletofacial growth changes before and after seven months of Herbst appliance treatment. 17 male subjects were observed for an average of 31 months prior to and following the Herbst treatment and cephalometric radiographs were taken at the beginning of observation, after removal of the Herbst, and at the end of observation. Comparing the pre-treatment and Herbst removal cephs, the researchers noticed inhibited and redirected maxillary growth, increased mandibular growth, anterior mandibular growth halted, jaw relationship improved, and the profile straightened. However, upon analyzing the post-observation ceph, the pair noted that several of these treatment changes reverted, leading them to conclude that the Herbst had only a temporary effect on the skeletal growth pattern (Pancherz and Fackel, 1990).

Assuming that there was going to be relapse of Class II correction following Herbst therapy, Pancherz set about determining what contributed to that relapse. In 1991, he compared 15 cases that had relapsed to 14 stable cases to see the skeletal and dental components of relapse. Lateral cephs were taken before and immediately after treatment plus six months and 5-10 years after treatment. He noted that the skeletal growth pattern of both jaws remained favorable and most likely did not contribute to the relapse of the occlusion.

However, significant dental changes did take place after the completion of treatment that affected the occlusal outcome. A relapse in overjet and molar relationships could be attributed to a statistically significant mesial movement of the maxillary molars and incisors in the relapse group following treatment. Pancherz suggested that this movement was due to both a persistent lip-tongue dysfunction habit and an unstable cuspal interdigitation following treatment (Pancherz, 1991).

Later that same year, Hansen, Pancherz, and Hagg examined the possibility that the period of growth that subjects were treated in could contribute to long-term effects. 40 male subjects were treated with the Herbst for an average of 7 months and then recalled at the end of growth (average of 6.6 years). Lateral cephs were taken and the groups were divided according to the timing of their growth during the beginning of treatment (pre-peak, peak, post-peak). No differences in dental relationships were seen between the three groups at the recall point and intermaxillary growth was favorable in the post-treatment period for all groups (with an average of 4.3mm of mandibular growth over maxillary growth). Obviously, the amount of growth for those treated pre-peak was greater than the other two groups following treatment. The group concluded that the growth period in which Herbst treatment was rendered did not have any conclusive effects on the stability of the results. However, they recommended that patients be treated in the permanent dentition at or just after peak growth to enhance occlusal stability and reduce retention time (Hansen et al, 1991).

Hansen returned to the stability question the next year and looked at 108 subjects who were treated with the Herbst. Cephalometric radiographs were taken before and after treatment as well as 12 months, and 5-10 years after treatment. At the 12 month mark, the occlusion had settled into a Class I relationship due to movement of the maxillary and

mandibular dentition, 90% of which seemed to be completed within six months after treatment. After 5-10 years of retention, the intermaxillary jaw relationship was improved from the beginning, but not normalized while the dental relationship was normalized. Again, the growth period had apparently no effect on the stability of correction. Hansen concluded that the Herbst appliance had no long-term adverse effects on the skeletal system (Hansen, 1992).

Hansen and Pancherz published another collaborative effort in August of 1992, comparing the long-term results of Herbst therapy against Bolton standards matched to their sample. 32 subjects (16 boys, 16 girls) were treated with the Herbst for an average of seven months and were recalled six months post-treatment and at the end of growth (an average of 6.7 years). The researchers saw in the long-term a normalized dental relationship and an almost normalized skeletal relationship. This indicated that the long-term results for the Herbst were more stable and effective in relation to the occlusion as opposed to the skeletal changes (Hansen and Pancherz, 1992).

The next summer, Pancherz and Anehus-Pancherz studied the stability of the Herbst's "headgear effect" on the maxilla and maxillary dentition. 45 Class II patients were gathered who had received seven months of Herbst treatment and cephs were taken at six months post-treatment and at the end of growth (an average of 6.4 years) to compare to the cephs taken immediately before and after treatment. In most of the subjects, the researchers noticed an intrusion and distalization of maxillary molars and an opening of the maxillary occlusal plane angle immediately after treatment. Within six months, however, most of these treatment changes had reverted. At the end of growth, these changes continued to revert and the maxilla demonstrated an anterior movement and downward tipping. The researchers felt

that, while the Herbst had a significant headgear effect on the maxillary dentition and skeletal structures, its changes may revert if not retained properly (Pancherz and Anehus-Pancherz, 1993).

Changes in the facial profile were next investigated by Pancherz and Anehus-Pancherz in 1994 using 69 subjects and looking at the same sequence of cephalometric radiographs. In the 20 patients that experienced relapse, their hard-tissue convexity was reduced from pre-treatment values, but their soft-tissue convexity remained stable when including the nose into the profile analysis. The 49 stable patients demonstrated a reduction of facial convexity in both hard and soft-tissue profiles. The pair stated that the Herbst does improve hard and soft-tissue facial profiles, but due to a large variation in growth patterns, the stability of the changes is unpredictable (Pancherz and Anehus-Pancherz, 1994).

Several articles were published in the mid- to late-1990's and into the early years of the twenty-first century that investigated the long-term stability of Herbst-induced changes to the occlusion. Hansen, Iemammueisuk, and Pancherz looked at various aspects of the occlusion in a 1995 study that used the same time periods of recall used for the above studies (six months and at the end of growth). In 53 patients that were treated to overcorrection of most occlusal relationships (overjet, overbite, sagittal molar relationship), the researchers noticed what they deemed a stability of overjet (4.5mm or less) in 83%. 79% still had a stable normal or overcorrected molar relationship and 68% had a stable canine relationship. This study demonstrated a fairly constant change to the occlusion after the end of the growth period (Hansen et al, 1995).

Hansen and Pancherz collaborated with Koutsonas to determine the Herbst's long-term effects in the mandibular incisor segment. In 15 boys and 9 girls, the researchers saw the

lower incisors proclined an average of 10.8° and the incisal edge moved anteriorly 3.2mm at the end of treatment. Within six months, the incisor angulation had relapsed an average of 7.9° and the incisal edge moved posteriorly an average of 2.5mm. However, the available space had not changed significantly from the end of treatment. At least five years after treatment, the researchers saw a stabilization in the angulation of the incisors, but a retroclination in relation to SN. Available space in the mandibular incisor segment had decreased an average of 0.8mm and the irregularity index had increased an average of 2mm. Through this information, the researchers concluded that the proclination of the lower incisors during Herbst therapy did not result in later incisor crowding and that in fact this phenomenon was due, in the long-term, to normal craniofacial growth changes (Hansen et al, 1997).

Schweitzer and Pancherz investigated the relationship between the upper incisors and lower lip in Class II, division 2 patients in 2001. 19 patients (11 boys, 9 girls) “successfully treated” with the Herbst and fixed appliances were recalled at one year post-treatment to have cephs taken. From the end of treatment, several dental changes had taken place indicating some measure of relapse. The upper incisors and lower incisors retroclined 0.6° and 2.3° respectively and the original deep overbite that had been greatly reduced deepened an average of 1.2mm. However, even with these changes, the improvement in the relationship of the upper incisor to lower lip remained stable. The researchers suggested that further post-retention studies should be conducted to fully assess long-term effects on this relationship (Schweitzer and Pancherz, 2001).

Three studies looked at the long-term effects of Herbst treatment on the TMJ. Ruf and Pancherz in 1998 used a clinical examination, a questionnaire, and MRIs to determine if

Herbst therapy had any long-term adverse effects on the TMJ. 20 subjects (10 boys, 10 girls) who had completed treatment at least four years previously were recalled and subjected to the three methods of investigation. Five subjects were found to have “moderate to severe” signs of TMJ disorders “ranging from partial to total disk displacement or deviation in the form of the condyle.” Three subjects showed mild TMJ disorders with small condylar displacement or subclinical soft tissue lesion. However, the incidence of signs and symptoms was in the normal range found in the literature and the frequency of disk displacement was not more than that of the asymptomatic population. The researchers concluded that the Herbst appliance has no long-term adverse effects on the TMJ (Ruf and Pancherz, 1998).

Croft, Buschang, English, and Meyer used cephalometric and tomographic radiographs to investigate the long-term effects on the TMJ in patients treated with the Herbst during the mixed dentition. 40 patients (16 boys, 24 girls) who were treated in the mixed dentition and retained with a prefabricated positioner were matched for age, sex, and mandibular plane angle with a sample of untreated Class II controls at an average of 17 months after treatment. TMJ tomograms illustrated a tendency for the condyle to sit slightly forward in the fossa (an average of 0.2mm) at the end of treatment and then fall back within the 17 month post-treatment period. The researchers noted a statistically significant change in the joint space following treatment. They concluded that Herbst therapy in the mixed dentition when combined with retention gives significant changes in the TMJ region that contribute to Class II correction (Croft et al, 1999).

Pancherz and Fischer found evidence that disputed this assertion when looking at lateral head films taken on 35 Class II, division 1 patients at post-treatment periods of 7.5 months and 3 years. After an average of 7.5 months of treatment, the condylar growth was

redirected posteriorly about two times that of 12 untreated Class II, division 1 controls. The glenoid fossa was displaced in an anterior and inferior direction and the “effective” TMJ changes were a similar pattern, but more pronounced. At 7.5 months after treatment, however, all treatment changes had reverted. After 3 years, any changes to the TMJ were due to normal physiological growth. The researchers summarized that any change produced by the Herbst appliance on the TMJ was temporary and relapsed within a year’s time (Pancherz and Fischer, 2003).

Ruf and Pancherz looked at the stability of changes to the vertical jaw relationships as represented by the mandibular plane angle. 80 Herbst patients (47 boys, 33 girls) were recalled six months and 4.5 to 5 years post-treatment for lateral cephalometric radiographs. Analysis of the cephs revealed that the mandibular plane angle was unaffected by treatment (on average). As time progressed, the researchers noted a continued decrease in mandibular plane angle, with males experiencing a larger decrease than females. The pair noticed a large variation in individual response, but no significant difference between normal, hypo-, and hyperdivergent patients (Ruf and Pancherz, 1996).

More recently, a group led by Berger compared stability of treatment with the Herbst appliance and bilateral sagittal split osteotomy surgery. 15 Herbst patients were recalled an average of 35.8 months after completion of treatment for a final cephalometric radiograph and compared to patients receiving a BSSO, with a final ceph taken an average of 34.9 months after treatment. Since the Herbst treatment was performed on patients who were still growing, it was not surprising that the researchers saw a continuation in the favorable growth of the mandible following the cessation of treatment. What was significant, however, was that the Herbst-induced changes seemed to be as stable as those brought about by surgery,

and, in the case of vertical changes, even more stable. The researchers concluded that early treatment of Class II with a functional appliance could potentially help the patient avoid future surgery (Berger et al, 2005).

F. Conclusion

Through a review of the literature, it is clear that more research must be done to determine what effect, if any, Herbst treatment has on the dental and skeletal correction of Class II malocclusion and if that effect is stable. Are we actually seeing an effect from treatment that would not have otherwise occurred? Or are we being, in the words of Lysle Johnston, “grossly misleading to credit functional appliances with having caused the good growth that commonly accompanies their use” (Johnston, 1998)? If we are seeing a direct result of treatment, how long does this result last? A collection of well-researched and reputable studies have given a conflicting set of answers.

It is the purpose of this study not to question if or how changes in the Class II dental and skeletal pattern have come about through the use of the Herbst appliance, but to determine if these changes show stability after treatment. While the bulk of Pancherz’s articles show good results in the short term, but significant relapse in the long term, many of his subjects were treated with the Herbst for less than 8 months. In addition, many of the papers reviewed employ an inconsistent or non-existent use of fixed appliance treatment to settle the occlusion following Herbst therapy and few use a consistent method of retention. With both cuspal interdigitation and retention mentioned by several studies as factors important to the stability of Herbst changes, one would believe that these variables should be present and standardized.

The Dischinger protocol to Herbst treatment calls for an overcorrection of the malocclusion with tomograms at the conclusion of the therapy to ensure that the condyle is seated in the fossa. A period of full fixed appliances (braces) follows to align the dentition and a standardized retention completes the treatment to hold the changes in place (Dischinger, 1995). The goal of the present study is to determine the stability of the Class II correction elicited by a treatment protocol of at least 12 months of Herbst treatment followed by fixed appliances and a standardized retention.

G. REFERENCES

1. Pancherz H. The Herbst Appliance – Its biologic effects and clinical use. *Am J Orthod* 1985; 87: 1-20.
2. Hanks S. A New Herbst Appliance. *J Clin Orthod* 2003; 37: 376-379.
3. Matasa C. The Evolution of some “Functionals”. *The Orthodontic Materials Insider* 1995; 8: 7-8.
4. O’Brien K, Wright J, Conboy F, Sanjie Y, Mandall N, Chadwick S, Connolly I, Cook P, Birnie D, Hammond M, Harradine N, Lewis D, McDade C, Mitchell L, Murray A, O’Neill J, Read M, Robinson S, Roberts-Harry D, Sandler J, Shaw I. Effectiveness of treatment for Class II malocclusion with the Herbst or Twin-block appliances: A randomized, controlled trial. *Am J Orthod Dentofacial Orthop* 2003; 124: 128-137.
5. Pancherz H. Treatment of Class II malocclusions by jumping the bite with the Herbst appliance. *Am J Orthod* 1979; 76: 423-442.
6. Pancherz H. Vertical dentofacial changes during Herbst appliance treatment. A cephalometric investigation. *Swed Dent J Suppl* 1982; 15: 189-196.
7. Dischinger T. Edgewise Herbst Appliance. *J Clin Orthod* 1995; 29: 738-742.
8. Lai M, McNamara JA Jr. An evolution of two-phase treatment with the Herbst appliance and preadjusted edgewise therapy. *Semin Orthod* 1998; 4: 46-58.
9. Ruf S, Pancherz H. Dentofacial effects and facial profile changes in young adults treated with the Herbst appliance. *Angle Orthod* 1999; 69: 239-246.
10. Manfredi C, Cimino R, Trani A, Pancherz H. Skeletal changes of Herbst appliance therapy investigated with more conventional cephalometrics and European norms. *Angle Orthod* 2001; 71: 170-176.
11. Ruf S, Pancherz H. Temporomandibular joint growth adaptation in Herbst treatment: a prospective magnetic resonance imaging and cephalometric roentgenographic study. *Euro J Orthod* 1998; 20: 375-388.
12. McNamara JA Jr. Neuromuscular and skeletal adaptations to altered function in the orofacial region. *Am J Orthod* 1973; 64: 578-606.
13. Kantomaa T, Hall BK. Mechanisms of adaptation in the mandibular condyle of the mouse. *Acta Anatomica* 1988; 132: 114-119.
14. McNamara JA Jr, Carlson DS. Quantitative analysis of temporomandibular joint adaptations to protrusive function. *Am J Orthod* 1979; 76: 593-611.

15. Woodside DG, Metaxas A, Altuna G. The influence of functional appliance therapy on glenoid fossa remodeling. *Am J Orthod Dentofacial Orthop* 1987; 92: 181-198.
16. Voudouris J, Kuftinec M. Improved clinical use of Twin-block and Herbst as a result of radiating viscoelastic tissue forces on the condyle and fossa in treatment and long-term retention: Growth relativity. *Am J Orthod Dentofacial Orthop* 2000; 117: 247-266.
17. Popowich K, Nebbe B, Major P. Effect of Herbst treatment on temporomandibular joint morphology: A systematic literature review. *Am J Orthod Dentofacial Orthop* 2003; 123: 388-394.
18. Voudouris J, Woodside D, Altuna G, Kuftinec M, Angelopoulos G, Bourque P. Condyle-fossa modifications and muscle interactions during Herbst treatment, Part 1. New technological methods. *Am J Orthod Dentofacial Orthop* 2003; 123: 604-613.
19. Voudouris J, Woodside D, Altuna G, Angelopoulos G, Borque P, Lacouture CY. Condyle-fossa modifications and muscle interactions during Herbst treatment, Part 2. Results and conclusions. *Am J Orthod Dentofacial Orthop* 2003; 124: 13-29.
20. McNamara JA Jr, Howe RP, Dischinger TG. A comparison of the Herbst and Frankel appliances in the treatment of Class II malocclusion. *Am J Orthod Dentofacial Orthop* 1990; 98: 134-144.
21. Burkhardt D, McNamara JA Jr, Baccetti T. Maxillary molar distalization or mandibular enhancement: A cephalometric comparison of comprehensive orthodontic treatment including the pendulum and the Herbst appliance. *Am J Orthod Dentofacial Orthop* 2003; 123: 108-116.
22. Pancherz H, Fackel U. The skeletofacial growth pattern pre- and post-dentofacial orthopaedics. A long-term study of Class II malocclusions treated with the Herbst appliance. *Eur J Orthod* 1990; 12: 209-218.
23. Pancherz H. The nature of Class II relapse after Herbst appliance treatment: a cephalometric long-term investigation. *Am J Orthod Dentofacial Orthop* 1991; 100: 220-233.
24. Hansen K, Pancherz H, Hagg U. Long-term effects of the Herbst appliance in relation to the treatment growth period: a cephalometric study. *Eur J Orthod* 1991; 13: 471-481.
25. Hansen K. Post-treatment effect of the Herbst appliance. A radiographic, clinical and biometric investigation. *Swed Dent J Suppl* 1992; 88: 1-49.
26. Hansen K, Pancherz H. Long-term effects of Herbst treatment in relation to normal growth development: a cephalometric study. *Eur J Orthod* 1992; 14: 285-295.

27. Pancherz H, Anehus-Pancherz M. The headgear effect of the Herbst appliance: a cephalometric long-term study. *Am J Orthod Dentofacial Orthop* 1993; 103: 510-520.
28. Pancherz H, Anehus-Pancherz M. Facial profile changes during and after Herbst appliance treatment. *Eur J Orthod* 1994; 16: 275-286.
29. Hansen K, Iemamneisuk P, Pancherz H. Long-term effects of the Herbst appliance on the dental arches and arch relationships: a biometric study. *Br J Orthod* 1995; 22: 123-134.
30. Hansen K, Koutsonas TG, Pancherz H. Long-term effects of Herbst treatment on the mandibular incisor segment: a cephalometric and biometric investigation. *Am J Orthod Dentofacial Orthop* 1997; 112: 92-103.
31. Schweitzer M, Pancherz H. The incisor-lip relationship in Herbst/multibracket appliance treatment of Class II, Division 2 malocclusions. *Angle Orthod* 2001; 71: 358-363.
32. Croft RS, Buschang PH, English JD, Meyer R. A cephalometric and tomographic evaluation of Herbst treatment in the mixed dentition. *Am J Orthod Dentofacial Orthop* 1999; 116: 435-443.
33. Pancherz H, Fischer S. Amount and Direction of Temporomandibular Joint Growth Changes in Herbst Treatment: A Cephalometric Long-term Investigation. *Angle Orthod* 2003; 73: 493-501.
34. Ruf S, Pancherz H. The effect of Herbst appliance treatment on the mandibular plane angle: a cephalometric roentgenographic study. *Am J Orthod Dentofacial Orthop* 1996; 110: 225-229.
35. Berger JL, Pangrazio-Kulbersh V, George C, Kaczynski R. Long-term comparison of treatment outcome and stability of Class II patients treated with functional appliances versus bilateral sagittal split ramus osteotomy. *Am J Orthod Dentofacial Orthop* 2005; 127: 451-464.
36. Johnston L. Growth and the Class II patient: rendering unto Caesar. *Semin Orthod* 1998; 4: 59-62.

SECTION II
JOURNAL ARTICLE

A. Introduction

The Herbst appliance for the treatment of mandibular deficiency was first introduced by Emil Herbst at the International Dental Congress in Berlin in 1905 (Pancherz, 1985). Interest in the appliance waned in the 1940's until the treatment approach was reintroduced by Pancherz in 1979. Reports have identified the effect of the Herbst appliance as most likely a combination of dentoalveolar movement, together with a remodeling of the glenoid fossa and mandibular condyle (Pancherz, 1985, Pancherz, 2003). Although Pancherz (1979) and Burkhardt et al (2003) have suggested that the Herbst appliance is a successful treatment approach for mandibular deficiency in growing patients, the changes observed during treatment have, on average, not been retained long term, perhaps suggesting that stimulation of growth had not occurred (Pancherz and Anehus-Pancherz, 1993). Advocates of the Herbst appliance in the United States have suggested that the effect on the mandible would perhaps be more sustainable if the treatment period was extended from an average of six months (Pancherz, 1979) to twelve months or longer. The purpose of this retrospective study was to assess the post-treatment changes (at least 12 months of retention) for patients with Class II malocclusion who had had a twelve month period of therapy with the Herbst appliance as part of their orthodontic treatment. The hypothesis is that no relapse in vertical or anteroposterior directions occurs following orthodontic treatment including the Herbst appliance.

B. Methods

The sample was drawn from the records of patients being treated by a single practitioner in a community based orthodontic practice. The Herbst appliance has been the primary corrective therapy for Class II patients in this practice since 1998. The treatment regimen includes twelve months of Herbst appliance, followed by fixed appliances. In most cases, no elastics are used during the fixed appliance treatment. A removable maxillary Hawley appliance and a removable mandibular Moore appliance are generally used for retention. A Moore retainer has acrylic approximating the lingual surfaces of all teeth, facial acrylic approximating the anterior teeth from canine to canine and a wire to support the anterior acrylic crossing the occlusion distal to the canines. Posterior vertical rests are typically placed in the lingual groove of the lower first molars. Patients are routinely recalled at one year after the removal of fixed appliances. The radiographic protocol in the practice includes a series of four lateral skull radiographs taken before treatment, at the end of Herbst treatment, the end of fixed appliance treatment, and at recall.

The subjects were identified from a log of Class II patients beginning treatment after January 19th, 1999 and completing treatment before June 29th, 2004. This time frame was selected for two reasons: all radiographs since January 1999 were taken on the same machine with a magnification of 1:1.1 and the one year retention visit was due prior to the start of this study. The inclusion criteria for this study were as follows: Class II malocclusion treated by at least 12 months of Herbst appliance therapy and fixed appliances and at least 12 months of retention. 5 Class II patients treated during this interval were not eligible because a Herbst appliance had not been used for treatment or had not been used for 12 months, or no fixed appliance treatment had occurred, or no retention cephalogram was

available. Of the 85 eligible patients, only one was not included because the pre-treatment cephalogram had no visible ruler.

For research purposes, all identifying information was removed by the practice staff and the patient was assigned a random identification number. Protected health information was not recorded. A waiver of research consent and a waiver of HIPAA authorization were granted by the Biomedical Institutional Review Board at the University of North Carolina. The patient demographics are found in Tables 1 and 2.

Skeletal and dental measurements (Table 3) were obtained from lateral cephalometric radiographs taken before the start of treatment, immediate post-Herbst treatment, immediate post-fixed appliance treatment, and at recall. The skeletal age of all patients at the outset of treatment was determined by the practitioner from a hand-wrist radiograph using the method of Fishman (1982).

The cephalometric radiographs, taken in natural head position, were traced and digitized by a single person using a 26-point model designed for this study (Figure 1). An x-y coordinate axis was established for analysis, using a horizontal line through sella and nasion rotated down 6° anteriorly as the x-axis, and a vertical line through sella perpendicular to it as the y-axis. The method error was calculated from ten triplicate independently traced and digitized randomly selected cephalograms. Method error ranged from 0.45 to 1.35 for the angular measures and 0.33 to 2.41 for the linear measures. The intraclass correlation ranged from 0.90 for palatal plane angle to 0.99 for mandibular plane angle indicating excellent consistency in the measurement process.

The primary focus of interest was the change in skeletal and dental relationships between the end of fixed appliance treatment and the follow-up after at least one year of

retention. Indicator variables were used to produce a mean deviation coding scheme to assess the incremental change from each visit to the subsequent visit. (Details of the mixed linear model approach are provided in APPENDIX A). The covariates, time in Herbst treatment and gender and the pairwise interaction, were not significant explanatory variables for any of the cephalometric measures and were dropped from the model. The final model included only visit and hand-wrist stage.

C. Results

The subjects were predominantly female between the ages of 12 and 14 years and in the pre-peak growth stage of hand-wrist film analysis (Tables 1 and 2). The severity of the Class II malocclusion at the start of treatment varied (Table 3). In general, the skeletal anteroposterior severity was moderate with a mild skeletal deep bite and a moderate to severe dental Class II division 1 malocclusion.

Analysis of horizontal change

During Herbst therapy (between time points 1 and 2), the ANB angle improved in all patients towards a Class I pattern. The average reduction in ANB was 3.38° with over 80% of patients experiencing at least a 2° reduction. The SNB angle also improved towards Class I in all but one patient. Most of the anteroposterior linear measures indicated an advancement of the mandible during Herbst treatment: an average movement of 2 mm for B point and pogonion relative to the Nasion perpendicular and an increase of 5mm for mandibular unit length (Table 4). Only 5% of patients had a worsening of the anteroposterior dimension by 2mm or more.

The horizontal skeletal advancement that occurred during Herbst treatment relapsed slightly during fixed appliance treatment (between time points 2 and 3): ANB and SNB showed a small, approximately 1° , average relapse while the linear position relapsed between 1.5 and 2.6mm, on average (Table 4). A relapse in B point positioning of between 2 and 4 mm was seen in 24% of subjects and 10% had greater than 4mm of relapse.

At recall (between time points 3 and 4), the average change observed between the end of fixed appliance treatment and the one year follow-up record was quite small for all

measures (Table 4). The average change in ANB was only -0.30° . Few patients had a relapse of ANB (2%) or SNB (4%) of greater than 2° . The variability in the linear measures was larger: between 2-4mm of relapse in pogonion positioning in 10% of subjects while 4% had greater than 4mm of relapse. Box plot graphs of the ANB angle and B-point position changes are representative of the anteroposterior effect of the treatment protocol and show both the measures at each time point and changes during treatment (Figures 2 and 3). The graphs of the distribution of patients for these measures demonstrate the percentage of patients that had a change of more the 2° or 2mm (Figure 4).

Analysis of vertical change

During Herbst therapy (between time points 1 and 2), the average increase of the mandibular plane angle was only 0.19° and occurred with 14% of patients experiencing an increase of at least a 2° (Table 5). While the palatal plane angle was, on average, quite stable, 21% of patients did show an increase of more than 2° . The occlusal plane was also affected by the Herbst, with an average increase of 5.53° . The angle changed less than 2° in only 7 patients.

During the treatment with fixed appliances (between time points 2 and 3), the mandibular plane angle continued to increase by an average of 0.4° (Table 5). The angle increased more than 2° in 13% patients. The angle formed by the mandibular plane and palatal plane opened an average of 0.55° , with at least a 2° opening occurring in 21% of subjects. The occlusal plane angle seemed to rebound almost entirely during fixed treatment from the movement created during Herbst treatment by an average of -5.01° . A relapse of more than 4° occurred in 67% of patients.

After 12 months of retention (between time points 3 and 4), the average change for all of the vertical measurements was very small (Table 5). None of the average changes during retention were statistically significant. Again, box plots illustrating the individual measurements and changes between time points for mandibular plane angle and occlusal plane angle show the average vertical effects of this treatment protocol (Figures 5 and 6). The distribution of patients with greater than a 2° change is shown in Figure 7.

Analysis of dental change

During Herbst treatment (between time points 1 and 2), the mandibular incisors became more upright by an average 3.88° with the angle closing more than 2° in 60% of subjects (Table 6). The overjet in all subjects reduced by an average of 7.5mm with only 2 subjects experiencing a reduction of less than 2mm. Overbite reduced by an average of 5.13mm.

Through the fixed appliance therapy (between time points 2 and 3), an average relapse of 3.53° occurred in the position of the lower incisors (Table 6). The incisors became more upright by greater than 2° in 12% of subjects. The maxillary incisors flared in over 80% of patients by more than 2°. The average fixed treatment movement of the upper incisors was a flaring of 5.39°. A significant rebound of overjet occurred during braces by an average of 4.06mm. 76% of patients experienced a relapse in overjet of more than 2mm. There was an average deepening of the overbite of 1.96mm. 39% of subjects had an increase of between 2 and 4mm and 4% had an increase of over 4mm.

An average flaring of the lower incisors of 0.76° occurred during retention (between time points 3 and 4), with 22% of subjects having a flaring of between 2 and 4° and 15% having a flaring of more than 4° (Table 6). On average there was an uprighting of the

maxillary incisors of 0.43° . The teeth uprighted more than 4° in 10% of patients. Changes in overjet exhibited a much tighter range (-1.7mm to 2.9mm) and had a slight average increase of 0.50mm. A change within -2mm to 2mm occurred in 90% of subjects. Similarly, 90% of patients had a change in overbite from -2mm to 2mm, with a total range of -1.9mm to 2.6mm. Box plots of the measurements and changes in overjet and overbite illustrate the dental effects of this treatment protocol (Figures 8 and 9). The distribution of patients with changes to these measures that are greater than 2mm are found in Figure 10.

D. Discussion

The results of this investigation suggest that the small average post-treatment changes following Herbst appliance therapy with subsequent fixed appliances following the treatment protocol used in this study does generally result in a stable correction. The observed stability, on average, is in contrast to earlier studies (Pancherz and Fackel, 1990 and Pancherz et al, 2003) which reported only a temporary correction but used a different treatment protocol involving a shorter time in the Herbst appliance (7 -7.5 months), no fixed appliance treatment, and varied or no retention methods. Of course, after one year of retention some patients in this study did experience changes especially in overjet, overbite, and ANB. The percent with >2mm relapse was 1% for ANB and 9% for both overjet and overbite. The percent with greater than 4mm relapse was 1% for ANB and 0% for both overjet and overbite. The generally small amount of change during retention, although statistically significant for a few of the measures, does suggest that this protocol, by and large, offers a stable correction of Class II malocclusion.

The horizontal changes seen during Herbst treatment and after the removal of the Herbst appliance are, in general, similar to those reported in previous studies (Pancherz, 1979, Lai and McNamara, 1998, Schweitzer and Pancherz, 2001). On average, all measurements improved towards a Class I relationship during the time that the Herbst was being worn. As reported in previous studies, both a restraining force on the maxilla (Pancherz, 1985) and a forward positioning of the mandible (Manfredi et al, 2001) were seen. Mandibular unit length changes could have resulted from remodeling of the condyle (Ruf and Pancherz, 1998) or simply an increase in growth as the patient enters their period of peak growth (Johnston, 1998). 80 of 84 subjects had a clinical overcorrection past an ideal Class I

relationship as noted by the forward position of the mandible in relation to the maxilla and the dental relationships. This overcorrection is part of the treatment protocol to be “corrected” during the fixed appliance treatment.

The protocol used typically allows the anteroposterior overcorrection to relapse on its own, but, according to the practitioner, roughly one-third of patients require Class III vector elastics to eliminate the overcorrection. This variable was not included in the collection of information for this study. During the second phase of treatment, though at a slower rate, the mandible continued to grow in length in over three-quarters of patients, which would be expected since nearly 77% of patients were either in pre-peak growth or peak growth at the beginning of treatment according to initial hand-wrist radiographs.

At the recall time point (one year after all treatment was complete), on average there was almost no relapse in any of the variables selected to represent horizontal changes. The only statistically significant change was the change in ANB angle. However, the relapse noted was, on average, only a third of a degree, suggesting that this change was perhaps not clinically significant. The horizontal changes due to this Herbst treatment protocol seem to remain stable during a 12 month retention period.

The vertical changes effected by this treatment protocol were, on average, very stable. The palatal plane angle opened a statistically significant amount during Herbst treatment. This movement is a reflection of the high-pull headgear effect that the appliance has on the upper arch (Pancherz and Anehus-Pancherz, 1993). The superior-posterior force on the maxillary crowns could have tipped the maxilla resulting in an apparent restraining effect on the maxilla as described by Pancherz (1985). The occlusal plane also increased its angulation during the Herbst phase of treatment, but this movement was reversed during

fixed appliance treatment and there was little change post-treatment. This result reflects earlier findings by Pancherz (1982). During the retention period, on average there were few changes and none of clinical relevance. These results suggest that the vertical changes induced by the Herbst appliance, but largely corrected during fixed appliance treatment do not change following the end of treatment.

On average, during Herbst treatment in this sample, the angulation of the lower incisors uprighted by a statistically significant amount. This movement is in contrast to flaring forward as reported in earlier Herbst treatment (Pancherz, 1979). The protocol for this study requires brackets placed on the lower incisors with -10° of torque, resulting in the uprighting of these teeth. Again in this sample the upper incisors become, on average, more upright during Herbst therapy and again this can perhaps be explained as a result of a different treatment. As part of this protocol, while brackets are placed on the maxillary teeth from canine to canine the archwire is tied back against the maxillary molar crowns. It has been demonstrated that the Herbst appliance forces these molars posteriorly (Lai and McNamara, 1998) and this force is translated through the archwire and retracts the upper incisors with a significantly uprighting vector. Overjet, perhaps the most clinically obvious sign of a Class II malocclusion, was reduced during Herbst treatment as a result of retraction of the maxillary incisors and anterior movement of the entire mandibular dentition. Again, a wide range of response was observed, but all patients experienced some degree of overjet reduction. According to this treatment protocol, this measurement is overcorrected to at least an end-to-end relationship (Dischinger, 1995).

During fixed appliance treatment, the average changes were to flare both the maxillary and mandibular incisors to attain an ideal angulation. This was a treatment goal as part of the

therapeutic protocol. Despite the -10° torque brackets, the lower incisors returned to the original average angulation. This movement indicates that the uprighting force on these teeth is primarily a factor of the Herbst appliance. The overcorrection of overjet attained during Herbst treatment was reduced. By the end of treatment, overjet had been corrected towards a Class I relationship by an average of over 3mm from pre-treatment values. This correction reflects earlier results reported by Pancherz (1979 and 1985).

In the 12 months after treatment was concluded, the only average changes that were statistically significant was the relapse found in overjet and in overbite. However, the average changes were only 0.49mm and 0.55mm, respectively, which does not appear to be clinically significant. The remaining dental measures remained stable.

On the surface, this treatment protocol for Herbst therapy appears to attain stable results at least one year following the removal of appliances. With only statistically significant average changes observed in overjet, overbite, and ANB angulation, the data suggest that the Class II correction effected by the Herbst appliance remains successful on a long-term basis. While this information seems to support the null hypothesis that there is no change in skeletal and dental correction during the retention period, a number of weaknesses in this study prevent the researchers from definitively settling that debate.

First, similar to a number of previous studies (Pancherz and Fackel, 1990; Hansen, Pancherz, and Hagg, 1991; Pancherz and Anehus-Pancherz, 1994), this study had no control group with which to compare long-term results. A concurrent control group would enable the researchers to determine whether a stable Class II correction in the post-treatment time period was affected by the treatment or, as Johnston suggests, is simply an effect of favorable

growth that tends to accompany a variety of functional appliances (Johnston, 1998).

Unfortunately, a concurrent control group is not possible in the context of private practice.

Second, the length of the retention period is too short to confidently state that the treatment is stable. A period of 12 months following appliance removal does not ensure that the subjects have completed their peak growth period, suggesting that some changes after treatment are affected by natural growth patterns and not relapse of treatment or the treatment itself. Earlier studies have designated that the recall be performed at the “end of the growth period” to be certain that the dentofacial complex was changing as little as possible from natural patterns (Hansen and Pancherz, 1992 and Hansen et al, 1995). While a longer retention period – particularly one which lasted until the end of the subjects’ growth – would be efficacious for more definitively determining stability, it is unfortunately unattainable with this sample. The Herbst appliance has not been employed long enough in this private practice to allow such a long time period. A recall of subjects at the five or ten year mark after treatment would enhance the validity of this study.

There was a large range of response to treatment noted. While a small range of response was seen during the retention period, it is possible that the variety of response during treatment may affect the stability of correction. Certainly, the severity of the malocclusion before treatment may affect the level of response and stability especially considering that the protocol calls for an overcorrection until the incisal edges are end-to-end. But, as stated earlier by Tulloch et al, this factor alone cannot explain the wide variety, both positive and negative, seen at each time point (Tulloch et al, 1997). Gender, time in Herbst, and hand-wrist stage were analyzed as possible confounders, but there was no correlation between any of the variables and post-treatment stability. One variable that was not

examined was patient compliance with retention. How well the patients wore their retainers following the end of treatment would most likely have an impact on the stability of the result. Further studies are needed to determine what factors have an effect on long-term stability of Herbst treatment.

The treatment protocol employed in this study consists of at least 12 months of Herbst treatment, followed by a period of time in fixed appliances and a standardized method of retention. Earlier studies have employed a Herbst treatment of 6-8 months followed by no fixed appliances (Pancherz et al, 2003) or an unclear retention method (Pancherz and Anehus-Pancherz, 1993) and have demonstrated significant relapse after treatment. It is unclear if the key to long-term stability of correction is this formula of 12 months of Herbst therapy plus fixed appliances plus retention. Further studies are needed to compare this protocol with other combinations of orthodontic treatment involving the Herbst appliance.

The design of this study could potentially have had an impact on the generalizability of the results. Since this project employed a single clinician, it is difficult to apply this population to Herbst patients as a whole. A potential bias exists that remains a factor in all retrospective studies in that the sample population is dependant on the selection of the clinician. However, this study minimizes this bias due to the fact that the sample is of consecutive patients. All non-surgical Class II patients in the stated time frame are included. There also exists potential measurement bias due to the fact that the single person completing the cephalometric digitizing was not masked to the time point designations. The radiographs were traced in chronological sequence, possibly introducing a level of bias in the landmark identification. For future studies of Herbst therapy, a randomized clinical trial involving patients from multiple practitioners would offer a higher level of generalizability.

E. Conclusion

1. The Class II correction seen during this treatment protocol appears generally stable after 12 months following the end of treatment.
2. The relapse during the retention period is statistically significant for overjet, overbite, and the ANB angle. However, the small movements for each of these measures suggest that the relapse is not clinically significant.
3. Further studies are needed to determine what factors contribute to Herbst treatment stability and to compare the stability of this treatment with other treatment protocols.

F. Tables

Table 1: Demographic characteristics of subjects prior to the start of treatment

	Mean	Sd
Age at Pre-treatment	12.74	1.11
Herbst (in months)	13.08	1.75
Fixed appliance (in months)	18.49	4.82
Retention (in months)	19.75	7.33

Table 2: Percentage of subjects in various stages of growth prior to the start of treatment

Hand-Wrist stage	Pre-peak	Peak	Post-Peak
% Subjects	50.00	26.83	23.17

Table 3: Descriptive Statistics for the Pre-treatment Cephalometric Measures

Measurement	Mean	Sd
ANB (°)	5.63	1.80
SNB (°)	76.23	3.95
Mand unit length (mm)	113.44	5.98
B pt to N perp (mm)	-13.15	7.08
Pog to N perp (mm)	-13.70	8.30
StB pt to N perp (mm)	-1.48	7.35
SN-MPA (°)	31.85	6.05
PP-MPA (°)	26.81	5.25
SN-PP (°)	7.27	3.95
SN-OP (°)	17.40	4.10
Overjet	6.55	2.10
Overbite	5.13	1.98
L1-MPA (°)	81.36	6.97
L1-SN (°)	49.52	6.41
U1-SN (°)	101.92	6.77

Table 4: Descriptive Statistics for the Changes in the anteroposterior position between successive time points

Measurements	During Herbst Treatment			During Fixed Treatment			During Retention		
	Mean	Sd	P value	Mean	Sd	P value	Mean	Sd	P value
ANB (°)	-3.38	1.19	<.001	1.08	1.28	<.001	-0.31	0.88	0.01
SNB (°)	1.33	1.28	<.001	-0.68	1.30	<.001	-0.03	0.99	0.98
Mand unit length (mm)	5.40	2.51	<.001	1.82	2.30	<.001	0.80	1.73	0.09
B pt to N perp (mm)	1.54	2.46	<.001	-1.28	2.41	<.001	-0.04	1.85	0.99
Pog to N perp (mm)	1.97	2.74	<.001	-1.51	2.72	<.001	0.03	2.23	0.80
StB pt to N perp (mm)	3.38	2.71	<.001	-1.95	2.87	<.001	-0.45	2.11	0.19

Table 5: Descriptive Statistics for the Changes in the vertical position between successive time points

Measurements	During Herbst Treatment			During Fixed Treatment			During Retention		
	Mean	Sd	P value	Mean	Sd	P value	Mean	Sd	P value
SN-MPA (°)	0.14	1.90	0.18	0.40	1.42	0.03	-0.23	1.56	0.19
PP-MPA (°)	-0.53	1.96	0.10	0.55	2.02	0.03	-0.35	1.83	0.20
SN-PP (°)	0.68	1.97	<.001	-0.18	1.87	0.54	0.16	1.75	0.61
SN-OP (°)	5.48	2.89	<.001	-5.01	2.77	<.001	-0.48	2.07	0.17

Table 6: Descriptive Statistics for the Changes in the dental position between successive time points

Measurements	During Herbst Treatment			During Fixed Treatment			During Retention		
	Mean	Sd	P value	Mean	Sd	P value	Mean	Sd	P value
Overjet	-7.52	2.66	<.001	4.07	2.41	<.001	0.49	0.94	0.04
Overbite	-5.15	2.05	<.001	1.97	1.36	<.001	0.55	0.98	<.001
L1-MPA (°)	-3.88	5.86	<.001	3.53	4.56	<.001	0.75	3.06	0.13
L1-SN (°)	-4.03	6.23	<.001	3.13	4.76	<.001	0.98	3.06	0.06
U1-SN (°)	-3.28	6.50	<.001	5.40	4.43	<.001	-0.44	3.05	0.33

G. Figures

Figure 1: The 26-point cephalometric analysis model.

1. Ruler Point 1
2. Ruler Point 2
3. Nasal Tip
4. Labrale Inferius
5. Soft Tissue B Point
6. Soft Tissue Pogonion
7. Nasion
8. Orbitale
9. Sella
10. Condylion
11. PNS
12. ANS
13. A Point
14. Supradentale
15. Max Inc Tip
16. Max Inc Apex
17. Post Occlusal Plane Point
18. Ant Occlusal Plane Point
19. Menton
20. Gnathion
21. Pogonion
22. B Point
23. Mand Inc Tip
24. Mand Inc Apex
25. Gonion
26. Porion

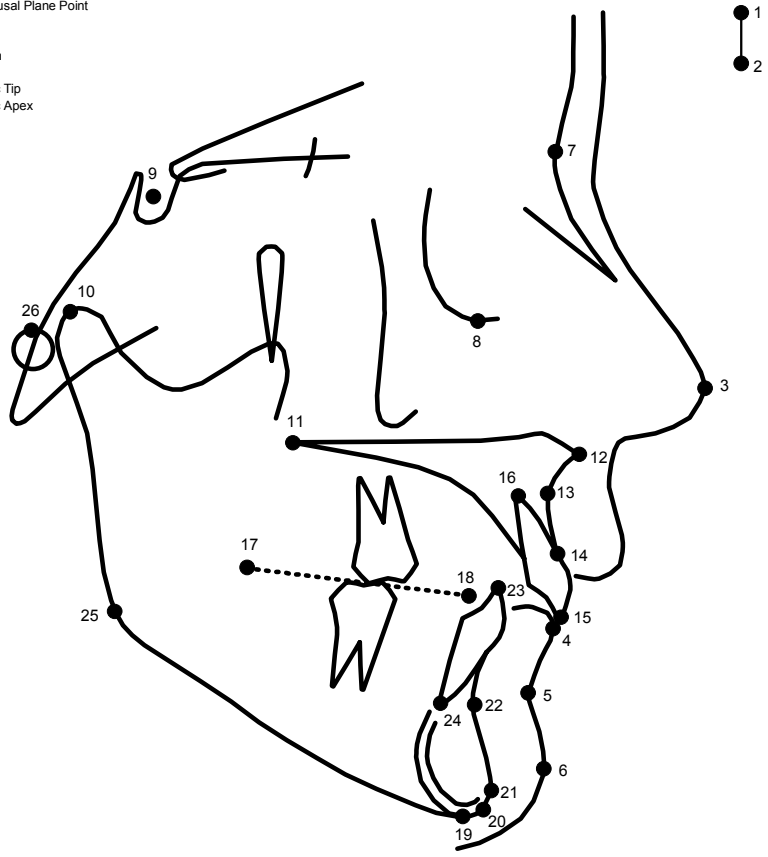


Figure 2: Box plots of descriptive statistics at four time points for the measures B point to Nasion perpendicular and ANB angle

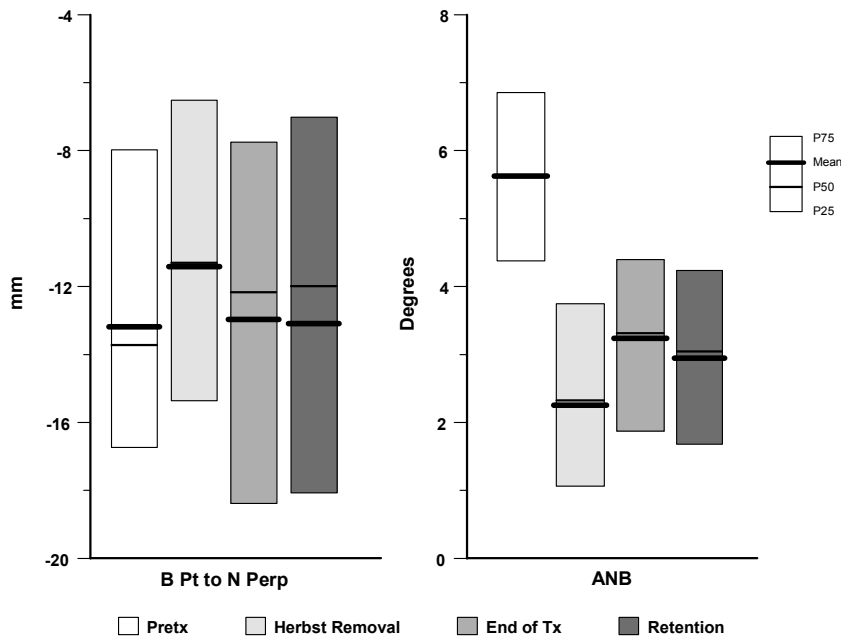


Figure 3: Box plots of changes in measurements between successive time points for the measures B point to Nasion perpendicular and ANB angle

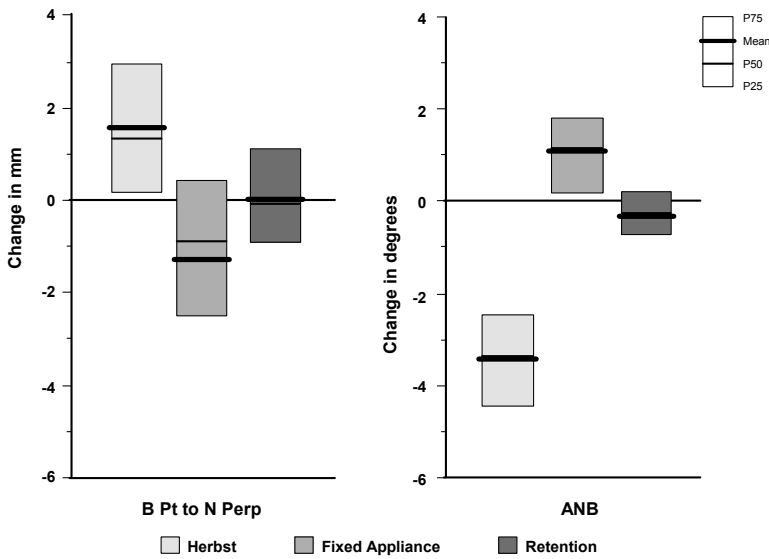


Figure 4: Percentage of patients with changes greater than 2° or 2mm for the measures B point to Nasion perpendicular and ANB angle

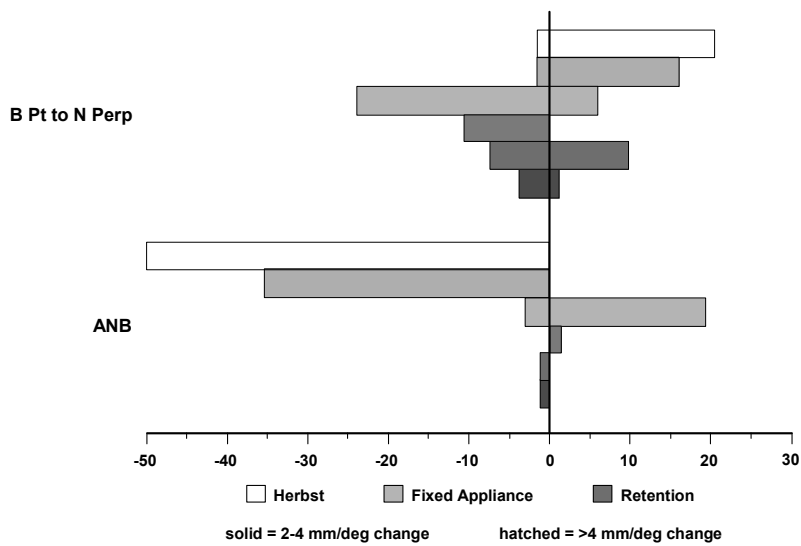


Figure 5: Box plots of descriptive statistics at four time points for the measures mandibular plane angle and occlusal plane angle

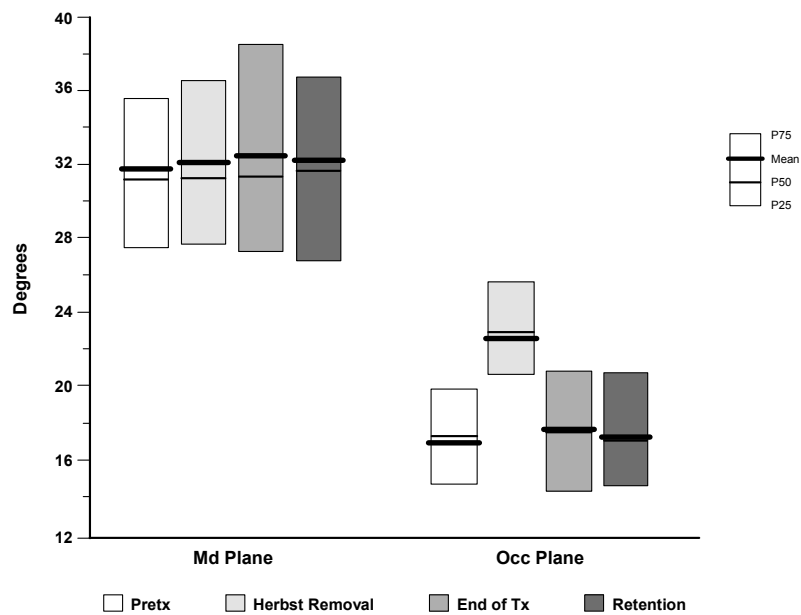


Figure 6: Box plots of changes in measurements between successive time points for the measures mandibular plane angle and occlusal plane angle

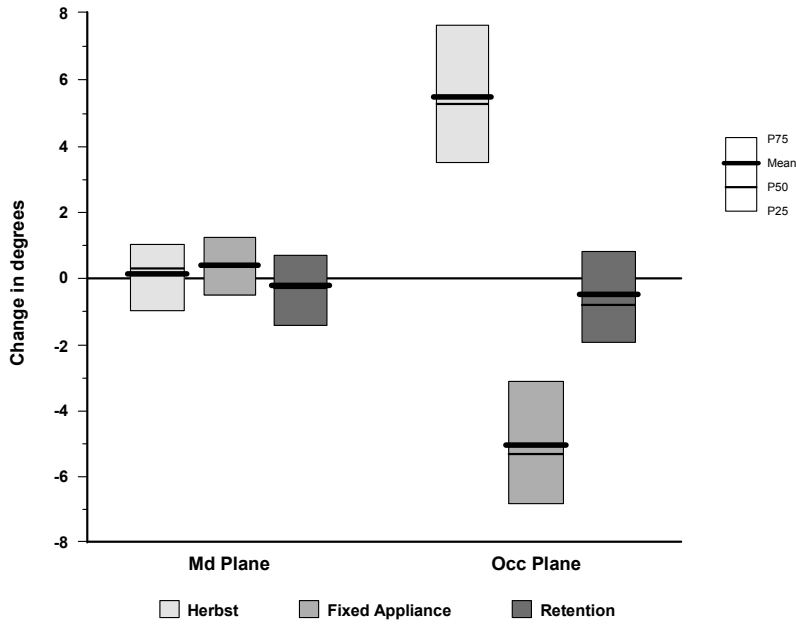


Figure 7: Percentage of patients with changes greater than 2° for the measures mandibular plane angle and occlusal plane angle

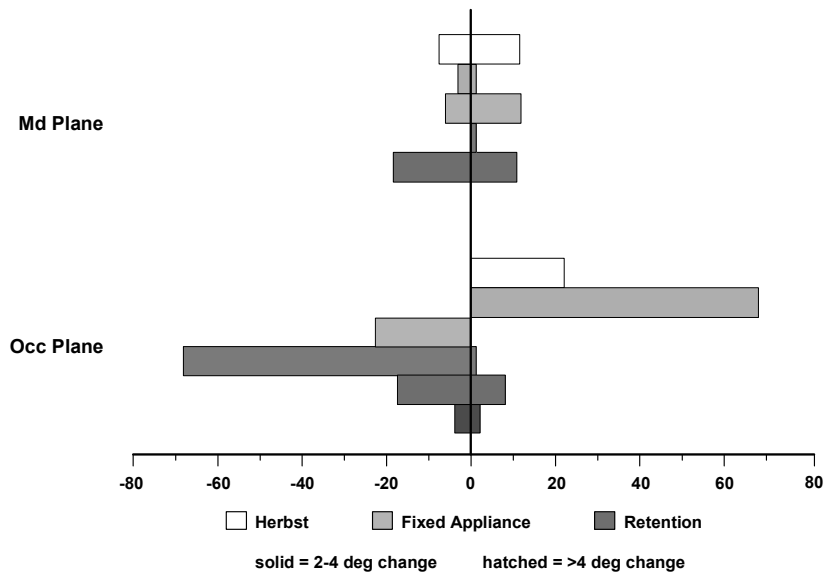


Figure 8: Box plots of descriptive statistics at four time points for the measures overjet and overbite

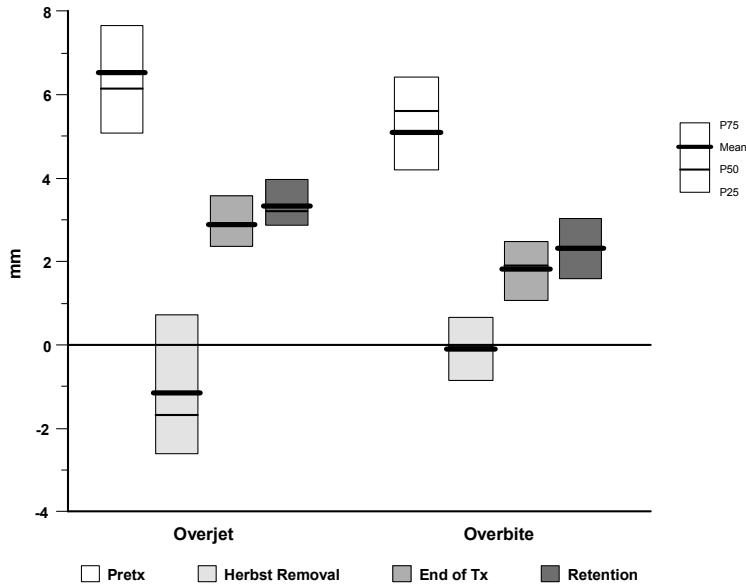


Figure 9: Box plots of changes in measurements between successive time points for the measures overjet and overbite

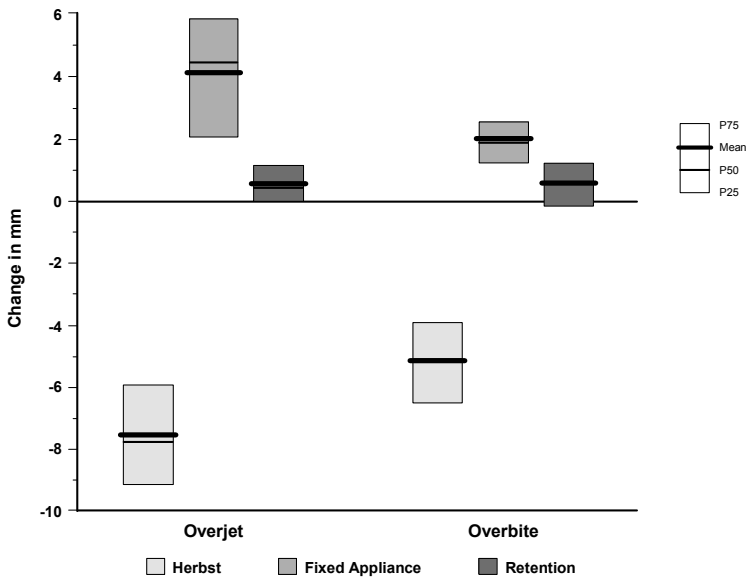
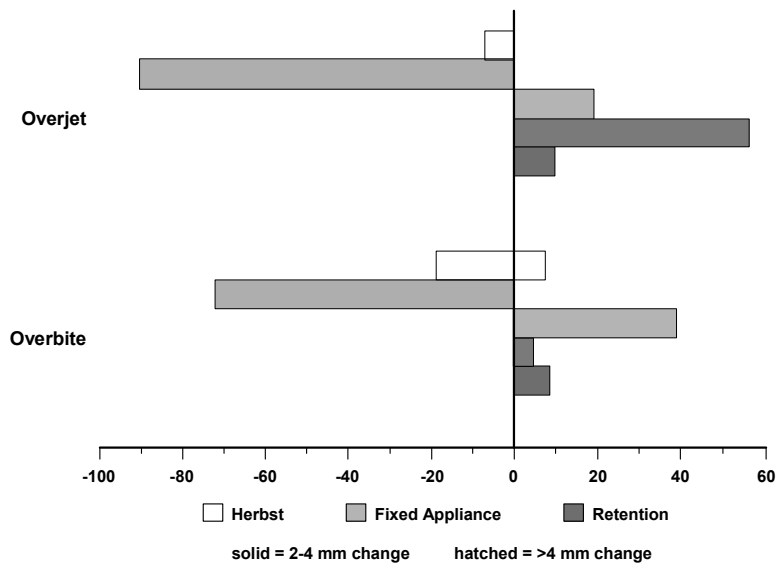


Figure 10: Percentage of patients with changes greater than 2mm for the measures overjet and overbite



H. Appendix A. Mixed Model Approach.

Since there was low variability among patients with respect to length of time between visits, time was treated as a categorical variable where 1 = baseline visit, 2 = end of Herbst therapy, 3 = end of fixed appliance therapy, and 4 = retention recall. Since the focus of the study is on the changes that occur during each clinical interval with the hypothesis that “large” changes would occur during interval 1 (baseline to end of Herbst therapy), no to moderate changes during interval 2 (end of Herbst therapy to removal of fixed appliances), and no change during interval 3 (removal of fixed appliances to recall), a deviations coding scheme which provided deviations from the mean of the previous visit, ie incremental change from the previous visit was used, where $x_{1it} = 1$ if visit > 1 , and 0 otherwise; $x_{2it} = 1$ if visit > 2 , and 0 otherwise; and $x_{3it} = 1$ if visit > 3 , and 0 otherwise. Reference cell coding was used for hand-wrist stage using SAS default coding such that hand-wrist stage 7-11 was the reference category.

Initially, a saturated random coefficients model with random intercept and random slope between baseline value and outcome value specified as random effects b_{i0} and b_{i1} , respectively with visit, hand wrist stage, gender, and time in Herbst appliance as fixed effects as well as the pairwise interaction between time in Herbst appliance and hand-wrist stage was fit. Covariance structures (unstructured, compound symmetry, heterogeneous compound symmetry) were evaluated using likelihood ratio tests and AIC criterion. Heterogeneous compound symmetry was selected because of the few (4) parameters to be estimated and convergence problems with other covariance structures. The covariates, time in Herbst appliance and gender and the pairwise interactions, were not statistically significant

explanatory variables for any of the cephalometric measures and were dropped from the model. The final model included only the main effects of visit and hand wrist stage:

$$Y_{it} = (\beta_{01} + \beta_{02} z_{1i} + \beta_{03} z_{2i} + b_{i0}) + (\beta_1 + b_{i1}) x_{1it} + \beta_2 x_{2it} + \beta_3 x_{3it} + e_{it}$$

where $b_i = (b_{i0}, b_{i1})'$ and e_{it} are independent normally distributed random variables with $\text{var}(b_{i0}) = \sigma_0^2$ is the subject to subject variation in intercept, $\text{var}(b_{i1}) = \sigma_1^2$ is the subject-specific deviation about the change between baseline and the average of all subsequent visits, $\text{cov}(b_{i0}, b_{i1}) = \sigma_{01}$ is the subject to subject covariance between intercept and slope, and $\text{var}(e_{it}) = \sigma_e^2$ is the within subject residual variability. The following parameters in the model are of particular interest:

β_1 is the population averaged change in outcome from baseline to end of Herbst therapy

β_2 is the population averaged change in outcome from end of Herbst therapy to removal of fixed appliances

β_3 is the population averaged change in outcome from removal of fixed appliances to recall.

I. REFERENCES

1. Pancherz H. The Herbst Appliance – Its biologic effects and clinical use. *Am J Orthod* 1985; 87: 1-20.
2. Pancherz H, Fischer S. Amount and Direction of Temporomandibular Joint Growth Changes in Herbst Treatment: A Cephalometric Long-term Investigation. *Angle Orthod* 2003; 73: 493-501.
3. Pancherz H. Treatment of Class II malocclusions by jumping the bite with the Herbst appliance. *Am J Orthod* 1979; 76: 423-442.
4. Burkhardt D, McNamara J, Baccetti T. Maxillary molar distalization or mandibular enhancement: A cephalometric comparison of comprehensive orthodontic treatment including the pendulum and the Herbst appliance. *Am J Orthod Dentofacial Orthop* 2003; 123: 108-116.
5. Pancherz H, Anehus-Pancherz M. The headgear effect of the Herbst appliance: a cephalometric long-term study. *Am J Orthod Dentofacial Orthop* 1993; 103: 510-520.
6. Fishman LS. Radiographic evaluation of skeletal maturation. A clinically oriented method based on hand-wrist films. *Angle Orthod* 1982; 52: 88-112.
7. Pancherz H, Fackel U. The skeletofacial growth pattern pre- and post-dentofacial orthopaedics. A long-term study of Class II malocclusions treated with the Herbst appliance. *Eur J Orthod* 1990; 12: 209-218
8. Lai M, McNamara JA Jr. An evolution of two-phase treatment with the Herbst appliance and preadjusted edgewise therapy. *Semin Orthod* 1998; 4: 46-58.
9. Schweitzer M, Pancherz H. The incisor-lip relationship in Herbst/multibracket appliance treatment of Class II, Division 2 malocclusions. *Angle Orthod* 2001; 71: 358-363.
10. Manfredi C, Cimino R, Trani A, Pancherz H. Skeletal changes of Herbst appliance therapy investigated with more conventional cephalometrics and European norms. *Angle Orthod* 2001; 71: 170-176.
11. Ruf S, Pancherz H. Temporomandibular joint growth adaptation in Herbst treatment: a prospective magnetic resonance imaging and cephalometric roentgenographic study. *Euro J Orthod* 1998; 20: 375-388.
12. Johnston L. Growth and the Class II patient: rendering unto Caesar. *Semin Orthod* 1998; 4: 59-62.
13. Pancherz H. Vertical dentofacial changes during Herbst appliance treatment. A cephalometric investigation. *Swed Dent J Suppl* 1982; 15: 189-196.

14. Dischinger T. Edgewise Herbst Appliance. *J Clin Orthod* 1995; 29: 738-742.
15. Hansen K, Pancherz H, Hagg U. Long-term effects of the Herbst appliance in relation to the treatment growth period: a cephalometric study. *Eur J Orthod* 1991; 13: 471-481.
16. Pancherz H, Anehus-Pancherz M. Facial profile changes during and after Herbst appliance treatment. *Eur J Orthod* 1994; 16: 275-286.
17. Hansen K, Pancherz H. Long-term effects of Herbst treatment in relation to normal growth development: a cephalometric study. *Eur J Orthod* 1992; 14: 285-295.
18. Hansen K, Iemamnueisuk P, Pancherz H. Long-term effects of the Herbst appliance on the dental arches and arch relationships: a biometric study. *Br J Orthod* 1995; 22: 123-134.
19. Tulloch JFC, Proffit WR, Phillips C. Influences on the outcome on early treatment for Class II malocclusion. *Am J Orthod Dentofacial Orthop* 1997; 111: 533-542.