IN VIVO MICROLEAKAGE EVALUATION OF TWO ROOT FILLING MATERIALS IN TEETH WITHOUT A CORONAL SEAL

Derek Duggan

A thesis submitted to the faculty of the University of North Carolina at Chapel Hill in partial fulfillment of the requirements for the degree of Master of Science in the School of Dentistry (Endodontics)

Chapel Hill
2008

Approved by,

Dr. Martin Trope (Advisor)

Dr. FabricioTeixeira (Reader)

Dr. Roland Arnold (Reader)

Dr. Daniel Caplan (Reader)

Abstract

Derek Duggan

In vivo microleakage evaluation of two root-filling materials in teeth without a coronal seal

(Under the direction of Dr. Martin Trope)

Two carrier-based materials were compared to assess their resistance to coronal microleakage in a dog model when no coronal seal was present. Histologic evidence of inflammation and infection were the outcome parameters used. Experimental teeth were filled with carrier-based Resilon® (Epiphany®, n=25) or with carrier-based gutta-percha (Thermafil®, n=25) and were left exposed for four months. One control group received a coronal seal over Epiphany® or Thermafil® root fillings. A second control group was instrumented and left empty. There was a higher frequency of inflamed teeth in the Thermafil® group (29%) than in the Epiphany® group (9%). 2 of 22 Epiphany® filled teeth (9%) showed evidence of tubular infection, whereas 16 of 23 Thermafil® filled teeth (70%) were infected. The difference in infection rates between Epiphany® and Thermafil® was statistically significant ($p < 0.001$).

Acknowledgements

Dr. Martin Trope who is an inspiring role model, as a professional and as a man

Dr. Fabricio Teixeira for his teaching ability and for his support of this research

Dr. Roland Arnold for his selfless support, which has spanned the breadth of my professional activities at UNC, including this research project

Dr. Daniel Caplan for his teaching skills and for his assistance with this study

Dr. Alice Curran for her guidance in analyzing the histological specimens

Annissa Anderson and DLAM support staff for facilitating my research

Dr. Andre Mol for expert advice and for the use of radiographic equipment

Kristin Main for her patience and expert advice with formatting

Dr. Leigh Thorne for the generous use of her facilities and support staff

Dr. Wallace Ambrose for the generous use of his facilities and his time

Dr. Julius Atashili for his expert assistance with data analysis

Dr. Marcel Yotebieng for his expert assistance with data analysis

Dr. Tawil for his generosity and professional guidance

Dr. Kirakozova for her selfless assistance and guidance

UNC Department of Endodontics

The AAE Foundation who funded this research

Dad, Mam, Linda and Caroline for all their love and support

Table of Contents

Page

List of Tables

List of Figures

Page

List of Abbreviations and Symbols

DNA	Deoxyribonucleic Acid
EDTA	Ethylenediamenetetraacetic Acid
IACUC	Institutional Animal Care and Use Committee
ISO	International Organization for Standardization
IV	Intravenous
kg	kilogram
mg	milligram
mL	milliliter
mm	millimeter
MPa	Mega Pascal
MTA	Mineral Trioxide Aggregate
®	Registered trademark
rpm	Revolutions per minute

Introduction

Etiology of Apical Periodontitis

Contemporary endodontic treatment is a product of two primary fields of research, namely, the biological mechanisms that lead to the development of periapical disease, and secondly, the clinical interventions designed to reverse this process. New scientific data leads to adjustments in clinical protocols, and the focus of the clinician should be on integrating high quality evidence into their own practice protocols.

Although Miller observed the presence of bacteria in necrotic dental pulp tissue in the late nineteenth century (1), the etiology of periapical disease continued to be a topic of debate during the first half of the twentieth century. Prior to the development of modern microbial culturing methods, many investigators failed to isolate bacteria from periapical lesions. Consequently, the necrotic pulp and root filling materials were among the principal causative factors implicated in the development of apical periodontitis.

An elegant study published in 1965 exposed the pulps of both germ-free rats and conventional rats (2). In the germ-free rats, there was minimal pulpal inflammation and no detectable periapical disease over time, but exposing the pulps in the control rats invariably resulted in pulpal and periapical disease due to invasion of the pulp space by the resident oral flora. In a later study using

primates, Moller reproduced the findings of Kakehashi by inoculating one group of teeth with bacteria and aseptically devitalizing the second group of teeth (3). After six months, the infected teeth had developed periapical disease, and the teeth with sterile devitalized pulps showed no evidence of such disease and remained uninfected.

A succession of later studies in humans confirmed the key role of bacteria in the development of periapical disease. Sundqvist isolated bacteria from intact traumatized teeth with radiographic evidence of periapical disease (4). None of the teeth with radiographically healthy periapical tissue demonstrated evidence of bacteria in the root canal space. The presence of bacteria has also been demonstrated in carious teeth with periapical lesions (5). Fabricius showed how different bacterial strains can induce variable periapical tissue destruction and how their survival in the root canal can be dependent on the presence or absence of other bacterial strains in their immediate environment (6).

The role of anaerobic bacteria in endodontics is a crucial one. Early culture studies in endodontics did not use strict anaerobic sampling techniques, and contamination of samples from the surrounding oral tissues was a constant hazard. With the development of methods whereby anaerobes are protected from oxygen during the sampling, transport, and culturing phases, a more accurate profile of endodontic pathogens has emerged. Subsequent to this, the polymerase chain reaction (PCR) technique has been successfully applied to endodontics, and a wide variety of new and previously unknown pathogens has been identified (7).

Host Response

Periapical inflammation can be induced by accidental trauma, injury from instrumentation, or irritation from chemicals and endodontic materials (8). These factors can provoke an intense tissue-response of short duration.

Similarly, the initial reaction of the periapical tissues to bacteria or their byproducts is a non-specific acute response, which comprises vasodilation, increased vascular permeability, and extravasation of neutrophils. Endogenous mediators, such as neuropeptides, prostaglandins and kinins effect this phase (9). Although the neutrophil is essentially protective in function, this cell can also damage periapical tissues. It contains enzymes which when released, degrade the structural elements of tissue cells and extracellular matrices

When infection is involved, neutrophils not only fight the microorganisms but also release leukotrienes and prostaglandins. Leukotrienes attract more neutrophils and macrophages into the area.

Macrophages dominate the later phase of the acute response (8). They release their own complement of inflammatory mediators, which lead to continued local vascular changes, bone resorption, and extracellular matrix degradation. In addition to the recruitment of B and T lymphocytes to the periapical tissues, T-cells, which amplify the inflammatory response and activate B-cells are known as T-helper/inducer cells, and those with direct toxic and suppressive effects on other cells have been named T-cytotoxic/suppressive cells. The lymphocytes responsible for antibody production are the B-cells. On

receiving signals from bacteria-derived antigens and the T-helper cells, some of the B-cells transform into plasma cells that manufacture and secrete antibodies.

The chronic phase of apical periodontitis is heralded by the shift in a neutrophil-rich lesion to a lesion rich in macrophages, lymphocytes, and plasma cells surrounded by collagenous connective tissue (9). There appears to be a predominant role for T-lymphocytes and macrophages in the chronic periapical lesion. Activated T-cells down-regulate the output of pro-inflammatory cytokines resulting in the suppression of osteoclastic activity and reduced bone resorption. In contrast, T-cell-derived cytokines may concomitantly up-regulate the production of connective tissue growth factors with stimulatory and proliferative effects on fibroblasts and the microvasculature. T-helper cells may participate in this process.

Sealing the Root Canal System

The rationale of placing a root filling is threefold:

(1) To block pathogens leaking from the oral cavity into the periapical tissues

(2) To prevent periapical tissue fluids and products leaking into the root canal

(3) To entomb any remaining pathogens within the root canal system

Even when the highest standards are met and the most careful procedures are followed, failures still occur because of the anatomical complexity of the root canal system (10). If the root canal system is instrumented and sealed before bacteria can occupy this space, then periapical disease can only develop

if the first criterion above is not satisfied. A recent review of outcome studies for uninfected teeth reported success rates of up to 95% (11).

When teeth develop apical periodontitis, the prognosis decreases, with reported success rates ranging from 75% to 90% (12) (13) (14). If a root canal filling material is capable of preventing coronal microleakage in a tooth that is uninfected, then optimal success rates can be achieved. This objective drives the search for improved root canal filling materials and methods.

Noyes describes a Dr. E.L. Clark in 1865 filling root canals with plasticized gutta-percha, heating the filling material until it became “as hot and fluid as possible without burning it and churning it into the pulp canals with a hot instrument” (15). Over one century later, Schilder introduced a more standardized warm gutta-percha technique known as warm vertical compaction as a means of filling the root canal space in three dimensions (16).

Thermafil® has been available for almost 20 years, but the original concept was discussed in a paper by Johnson in 1978 (17). Johnson described a method where thermoplasticised gutta-percha could be more easily introduced to the root canal using a stiff carrier (stainless steel files were originally advocated for this purpose). This technique involved notching a stainless steel file near the handle to allow easy separation of the distal segment after placement of the root filling in the root canal. Gutta-percha was warmed over a flame and hand-rolled onto the file. After disinfection, the author warmed the filling material in a flame until it became shiny, and then inserted it into the root canal. The file handle was

removed and the coronal portion of gutta-percha was compacted vertically around the stainless steel carrier.

In 1989, Thermafil®, a commercial product based on Johnson's original concept, was introduced to the dental market. In the following year, an epoxy-resin sealer was sold to complement Thermafil® called Thermaseal®. In 1991, the stainless steel carriers were replaced with a resin-based polymer and the ThermaPrep® oven was introduced which provided a controlled method of heating the obturators. In 1997 Tulsa Dental introduced ThermaSystem® Plus, a system which included redesigned obturators, a redesigned oven, a modified sealer and nickel titanium size verifiers to aid in obturator selection. Contemporary Thermafil® carriers are reported to possess longitudinal grooves that are designed to both improve backflow of gutta-percha during carrier insertion and aid in retrieval of the carriers during retreatments.

More recently, some contemporary root canal filling products have been introduced to the market which posess integrated adhesive bonding technology. The rationale for incorporating this property into the root canal filling is to try to improve the leakage resistance of the material. Resilon® is a resin-based obturation material, which incorporates adhesive technology. This root filling material is a synthetic polymer-based composite designed to be used with a dual cured polymer-based composite sealer containing a mixture of dimethacrylate, urethane dimethacrylate, ethoxylated dimethacrylate and hydrophilic difunctional dimethacrylates (18). The sealer also contains calcium hydroxide, barium sulfate, barium glass and silica fillers.

Although Resilon® and the associated sealer are traditionally used in conjunction with a self-etch primer in order to bond to the root canal walls, a self-etch sealer has recently been introduced. This product eliminates the need for the dentist to perform a separate priming step in the root canal filling process.

The Epiphany® Soft Resin Endodontic Obturation System (Pentron® Clinical Technologies, LLC) includes a choice of Resilon® points or pellets as the core filling material, which facilitates the use of both lateral and vertical compaction techniques. The root filling can be bonded to the root canal using either the original Epiphany® Sealer used with Epiphany® Self-Etch Primer or a new Epiphany® SE Self-Etch Sealer, which eliminates the priming step.

A carrier-based version of the core material used in the Epiphany® Soft Resin Endodontic Obturation System has been recently developed. The carrier is a polysulfone-containing polymer with radio-opaque fillers and the surrounding Resilon® filling contains polycaprolactone and polyolefin polymers loaded with fillers. This product combines adhesive bonding technology with a carrier product, with the dual aim of optimizing leakage resistance and ease of use.

Although there have been numerous *in vitro* leakage studies comparing the leakage resistance of root filling materials, the number of *in vivo* usage studies of both traditional and more contemporary root filling materials is relatively limited. The purpose of this study was to compare the sealing ability of Thermafil®, a carrier-based gutta percha product with an experimental Epiphany® carrier-based product in a canine model when no coronal seal is present.

The Significance of a Coronal Seal

The quality of the coronal restoration appears to be more critical to endodontic success than the quality of the underlying root filling (19). This suggests that regardless of the quality of the root filling, vulnerability of root-filled teeth to coronal leakage persists at this level.

A more recent *in vivo* study has suggested that high quality root fillings can resist bacterial penetration over extended time periods despite the absence of a coronal restoration (20).

Tronstad carried out a retrospective evaluation of radiographs of root treated teeth with coronal restorations and concluded that if the root filling was deemed to be of poor quality, a high quality coronal restoration did not have a significant effect on endodontic outcome (21). Conversely, if the root filling was of good quality then a good coronal restoration significantly improved the endodontic success rate.

Among the factors which predispose a tooth to coronal leakage and subsequent endodontic failure according to Saunders and Saunders are (1) an excessively thin temporary filling layer, (2) a fracture in the coronal filling (3) a fracture in the tooth structure itself and (4) when a post space overlying the root filling is too long (22).

Review of the Literature

In Vitro Leakage Studies

A series of two papers discussed the structure and limitations of *in vitro* leakage studies, which far outnumber *in vivo* leakage studies in endodontic literature (23,24). Of 35 studies considered in a review paper, less than half of these studies had enough statistical power due to small sample sizes among other factors, raising questions regarding the validity of conclusions drawn in such studies (24).

The principal behind dye leakage studies is that a dye is expected to move through voids in the root canal space by capillary action and though fluids by the process of diffusion. Swanson found that when roots with laterally condensed gutta-percha were exposed to artificial saliva for three days, dye penetrated up to 85% the length of the roots (25). Another study exposed laterally condensed gutta-percha fillings to human saliva for up to three months (26). The saliva was changed regularly and the extent of saliva penetration was assessed. Histological staining to detect saliva leakage had the least amount of technique variation whereas the dye leakage technique varied significantly depending on the immersion time of the roots in the dye. In addition, the extent of salivary leakage increased over the three-month experimental period.

Khayat showed no difference between lateral and warm vertical compaction of gutta-percha when subjected to a dye leakage test after all teeth were exposed to human saliva for one month (27). Saliva had penetrated all experimental teeth within the month.

Kontakiotis observed that methylene blue penetrated further in dry gaps than in water-filled gaps, suggesting a difficult to control variable in dye leakage studies (28). Basic dye leakage tests are qualitative in nature therefore no information is gained on the quantity of dye, which has penetrated a given sample. This drawback has been addressed in more recent dye extraction and fluorometry leakage tests.

In the dye extraction method, a tooth is immersed in dye for a given period. The tooth is then placed in a strong acid and the concentration of dye in this acid is analyzed with a spectrophotometer. This can give information on the quantity of dye that was absorbed into the root canal system of the tooth.

Camps and Pashley compared the classical dye penetration test with the dye extraction test (29). The dye extraction method gave similar results to the control (fluid filtration) test, and neither of these two methods correlated well with the classical linear dye penetration method. This study supports the validity of the dye extraction test.

In fluorometry, a fluorescent dye is placed in an upper chamber, which connects to the upper end of a mounted root. The root tip is connected to a lower chamber containing a non-fluorescent medium. If the dye penetrates the length

of the root then it can be detected using a fluorometer, which analyses the medium in the lower chamber.

Michailesco used a fluorescence-emitting bacterium in a bacterial leakage test to compare the leakage resistance of gutta-percha filled teeth over a period of six months (30). Cold lateral, warm lateral and warm vertical compaction techniques were compared. There was no statistically significant difference between the three filling techniques regarding leakage resistance.

With radioactive tracer leakage tests, a root is mounted between two chambers with the upper chamber containing the tracer and the lower chamber containing a non-radioactive medium such as saline. If the tracer penetrates the length of the root, then radioactivity will be detected in the lower chamber.

When methylene blue was combined with three different radioactice isotope tracers in another study, the methylene blue was observed to penetrate further than any of the tracers and two of the tracers only penetrated half as deeply as the methylene blue (31).

The fluid filtration model will locate any path that allows water to pass along and more importantly, there is a quantitative element, as the volume of water that passes through can also be measured (32).

The principal of the electrochemical technique is that gaps along a root filling can result in the formation of a continuous pathway for electrolytes through which an electric current can pass and be quantified (33).

The findings of one author suggest that the electrochemical technique materially affects the root, such that a dye leakage test later performed

subsequently may give different results than if the dye leakage test was performed initially (34).

With the silver staining technique, a root is immersed in silver nitrate and following processing a dark silver precipitate demonstrates where gaps are present. The silver ions are extremely small and it is unknown whether such nanoleakage is clinically relevant in terms of the penetration of pathogens, their byproducts and associated nutrients in root-filled teeth.

In the bacterial penetration leakage test a root is mounted between an upper and a lower chamber. The upper chamber contains a test bacterium and the lower chamber contains sterile medium. If the test organism penetrates the entire length of the root and enters the lower chamber, then growth of this bacterium will result in a visible change in the appearance of the fluid in the lower chamber.

Barthel found just over 21% overall agreement between bacterial leakage and dye leakage tests using a sample of 90 teeth. He concluded that dye leakage tests may not be a suitable way of assessing leakage in root-filled teeth (35).

Torabinejad looked at 45 gutta-percha root filled teeth in an *in vitro* model in which the teeth were exposed coronally to two bacterial species in an artificial saliva suspension for extended periods (36). Both positive and negative groups were used to help validate the findings. However, there was high variability in the time taken for the bacteria to penetrate the length of the individual root fillings, ranging from 10 days to 73 days.

Other authors have looked at the resistance of root fillings to bacterial byproducts, namely endotoxins. When endodoxin is present (a derivative of the cell wall of gram-negative bacteria), it can cause inflammation at a distance from the bacteria producing the endotoxin (37). Trope addressed the issue of endotoxins in the pathology of endodontic failure (38). In almost a third of the study sample, endotoxin from an upper chamber had fully penetrated gutta-percha filled teeth lacking a coronal seal after three weeks. This paper highlighted the importance of the sealer in preventing endotoxin ingress, which it is proposed, could result in periapical inflammation even if the much larger bacteria could not penetrate a well root filled tooth. Alves showed that endotoxin penetrated through gutta-percha filled teeth almost three times more quickly than the source bacteria. Therefore, periapical inflammation may commence *in vivo* long before the bacteria manage to reach the periapical tissues (39).

Drawbacks of *In Vitro* Leakage Tests

Air trapped within the root-filled space can affect dye leakage and fluid filtration leakage models. Capillary action and the process of diffusion are affected negatively by entrapped air (40). The consequence of trapped air also has an affect on ion transport when the electrochemical leakage test is performed. If non-motile bacteria are used in leakage studies, they rely on diffusion and Brownian movement (41). Once again, entrapped air affects such movement. Methylene blue is a commonly used dye in leakage studies, however, due to its low pH, it may demineralize dentin, which may overstate the leakage

potential of a root filling (23). Another disadvantage of the dye penetration method is that unlike fluid filtration leakage models, the samples are destroyed when teeth are split in half in order to measure the extent of dye penetration. Other variables which may influence leakage study outcomes include the time elapsed following the root filling before teeth are immersed in a dye or tracer, the immersion period itself, in addition to properties of the actual tracer used such as the pH, ionic charge and molecular size (23). If radioactive tracer molecules are used to detect leakage, calcium-containing tracers can react with the calcium in apatite crystals in teeth, skewing results. In addition, some tracer molecules used in past studies are relatively large, and may be too large to pass through small gaps in a filled root canal space. This could lead to an underestimation of the leakage potential of such samples. When 60 teeth were subjected to consecutive fluid filtration and bacterial penetration leakage tests only two of the samples showed complete bacterial penetration after 60 days. A total of 21 samples showed evidence of leakage using the fluid filtration test (41). This study underlines the potentially low correlation between different leakage tests, which are intended to give information on the sealability of root filling materials. Standardization of leakage tests may be difficult to achieve due to the different skill levels of operators placing the test filling materials (42). In conclusion, *in vitro* leakage tests employ a wide range of methodologies, but findings are often not reproducible and the clinical implications of test outcomes are unclear. These concerns have led to the decision of the Journal of Endodontics to phase out the publication of such studies from 2008 onwards (43).

Sealer Studies

It is the sealer component of a root filling which seals the root canal space. .Studies have focused on different properties of sealers, which may affect their sealing ability in the clinical situation. There is currently a wide range of resin-based sealers available commercially, including EndoREZ®, a hydrophilic urethane methacrylate resin, as well as epoxy resin-based sealers such as AH26®, AH Plus®, EZ-Fill® and Thermaseal® Plus. Facer looked at sealer distribution in laterally condensed root fillings (44). Sealer was frequently absent between individual gutta-percha cones and the canal wall, and was sometimes absent completely between the cones themselves. This study demonstrates that predictably sealing all potential pathways against coronal leakage may not be achievable with some current materials and techniques. Zmener used a dye leakage model and laterally condensed gutta-percha to show significantly increased leakage with AH Plus® sealer compared to AH26® sealer (45). In a dye leakage study, Madison showed that using AH 26® sealer with gutta-percha filled teeth led to significantly more coronal leakage when compared to non resin-based sealers after teeth were left exposed to artificial saliva for one week (46). Madison later compared the ability of non resin-based sealers and AH 26® to resist dye penetration after root-filled teeth were exposed for one week in monkeys (47). No statistically significant difference in the degree of dye penetration between the three sealers was found, and all experimental teeth showed evidence of dye penetration. Kopper found that using AH Plus® showed

significantly less dye penetration than AH 26® when gutta-percha filled teeth in dogs had been left exposed to oral fluids for 45 days (48).

De Moor demonstrated no difference in sealing ability between AH 26® and AH Plus® in a dye leakage experiment, whether lateral compaction or Thermafil was used (49). Gernhart performed a dye leakage study and found that there was significantly less dye penetration when AH Plus® and EndoREZ® with a warm vertical compaction technique than when Thermafil® or cold lateral compaction techniques were used (50). Cobankara used a fluid filtration test to show that when the smear layer was left intact, leakage increased using either AH 26® or RoekoSeal® compared to when the smear layer was removed (51). Kontakiotis used a fluid transport model to show how different thicknesses of a resin sealer, a calcium hydroxide sealer and a bonding agent did not result in different leakage rates (52). After two years of storage in water, however, leakage rates in the majority of experimental teeth increased. Wu showed how a thin sealer layer resisted leakage better than a thick layer using a fluid transport model (53). Another interesting finding of this study was that after storing sealers in water for one year, the sealing ability of AH 26®, Ketac® Endo and Tubliseal® increased. Siqueira found using a bacteria leakage test that calcium hydroxide sealers used with gutta-percha allowed total recontamination of the root canals in up to 80% of the samples depending on the sealer used (54). Almeida looked at dye leakage and sealer flow tests, concluding that AH Plus®, Epiphany® sealer and Sealapex® all leaked less than Pulp Canal Sealer, and that all sealers exhibited similar flow properties (55). Gettleman found that removing the smear

layer increased the bond between AH 26®, a resin-based sealer and root dentin (56).

The setting time of sealers can vary considerably even among samples of the same product. Allan demonstrated how most samples of AH 26®, Sealapex® and Tubliseal® in root filled teeth stored in 100% humidity were only partially set after one week, and many took up to one month to set fully (57). Roth's sealer samples were mostly unset after two months. These findings are significant in light of many studies subjecting sealers to leakage tests before the sealers may have completely set, leading to potentially questionable outcome data.

Another study showed that removing the smear layer did not significantly increase the bond strength of AH 26® sealer and that bond failure occurred most frequently at the interface with gutta-percha (58). Lee and co-workers found that AH 26® showed the highest bond strengths to both dentin and to gutta-percha when compared to other sealers commonly used with gutta-percha (59). Using a tensile testing device, Saleh demonstrated that smear layer removal led to a decreased bond for AH Plus® sealer (60). The author proposed that the increased surface area of the smear layer may have offered more area for bonding leading to the results obtained. The bond strength of AH Plus® was superior to Grossman's sealer, Apexit®, Ketac® Endo and RoekoSeal®, and within the AH Plus® group the failures were mainly cohesive in nature.

Bonded Root Canal Fillings

The combination of gutta-percha apically and a composite resin coronally has compared favorably to conventional root filling materials in resisting bacterial penetration in an *in vitro* model (61). A subsequent study from the same group showed that Resilon® placed using either a cold lateral or a warm vertical compaction technique showed superior leakage resistance compared to equivalent gutta-percha filling techniques in a split-chamber bacterial leakage model (62).

The potential degradation of polycaprolactone (a major constituent of Resilon®) by hydrolytic enzymes, which are produced by documented endodontic pathogens such as Enterococcus faecalis, was the subject of a series of studies by Tay and colleagues (63-65). However, the third paper in this series separates out individual components of the Resilon® compound before subjecting the polycaprolactone to hydrolases. In the clinical situation, polycaprolactone is chemically bound within the Resilon® composite and is only exposed to tissue fluids at the apical extent of the root filling. Consequently, the clinical implications of these findings, if any, are unclear. Yourtee et al. raised concerns regarding the solubility of a range of dimethacrylates in the presence of several common tissue enzymes (66). However, whether Resilon® is soluble when exposed to oral fluids over time *in vivo* is unknown at present.

Tay et al. concluded that a complete seal cannot be achieved with either Resilon®/Epiphany® or with gutta-percha/AH Plus® sealer in the apical 4 mm of a root canal (67). A silver tracer was used in this study to demonstrate the

presence of gaps between the sealer and hybrid layer in the Resilon® samples and between the sealer and the gutta-percha in the second group. It must be borne in mind that silver ions are much smaller than bacteria; therefore, the clinical implications of outcomes from such studies remain unclear.

One study reported that teeth filled with Resilon® may be more resistant to root fracture than gutta-percha filled teeth in an *in vitro* study using a vertical loading device (68). Both cold lateral and warm vertical filling techniques were employed, but due to the wide range in forces needed to fracture individual roots and the large associated standard deviations, the validity of such a claim is debatable. Subsequent research has estimated the modulus of elasticity of Resilon® to be between 100 and 200 MPa. To reinforce roots, the modulus of a root filling material would have to be similar to that of dentin, estimated at 14,000 MPa (69).

Hiraishi et al. found that the shear bond strength of Resilon® to Next®, a methacrylate-based sealer, was significantly lower when compared to the bond strength between a composite control and Next® (70). This led the authors to question the reliability and quality of the bond between Resilon® and methacrylate based sealers. The shear bond strength of Resilon® when using RealSeal®, a methacrylate-based sealer, was found to be substantially less than the shear bond strength of a composite control in an *in vitro* study by Tay (71).

In a dye leakage study, the Epiphany® Endodontic Obturation System proved more resistant to leakage than gutta-percha when cold lateral compaction techniques were used (72). The sealer used with the Resilon® - containing cones

was a self-etching sealer. This study only allowed three days for setting of both the self-etch sealer and the AH 26® sealer prior to immersion of the teeth in dye. Kaya found the leakage resistance of Resilon®/Epiphany® and gutta-percha/AH Plus® to be similar using a glucose penetration test (73). The author underlined some desirable properties of AH Plus®, commenting on its dimensional stability and its ability to form covalent bonds between dentin collagen and resin. Raina showed no significant difference in leakage resistance between Resilon® and gutta-percha using a fluid filtration model (74). In this study, one week was allotted for sealer setting prior to beginning the leakage test. Sagsen employed a fluid filtration test, which used a computer to monitor movement of the bubble designed to demonstrate fluid movement (75). In this study, Resilon® leaked significantly less than gutta-percha. Tunga showed how Resilon® filled teeth leaked significantly less than gutta percha filled samples in a fluid filtration model (76). However, the sealers were only allowed 48 hours to set before testing was commenced. This would be considered insufficient time for proper setting of resin sealers (57). Onay compared the leakage characteristics of Resilon® and gutta-percha by using both fluid filtration and glucose transport models (77). Resilon® showed similar leakage results to gutta-percha in the fluid filtration test with the smear layer removed but leaked more using the glucose penetration test. In this study, only 4 mm of both materials were tested in the leakage models. Using a fluid filtration model over a 90 day period, Resilon® and Epiphany® sealer leaked to a similar extent to gutta-percha and AH Plus® sealer (78). Stratton used a fluid filtration model and concluded that Resilon® exhibited less leakage

than gutta-percha after allowing three weeks for the respective sealers to set fully (79). Pasqualini and colleagues used a split chamber apparatus to detect the passage of Enterococcus faecalis through both Resilon® and gutta-percha fillings (80). When turbidity was detected in the lower chamber, the solution was subjected to a PCR amplification technique called One Cut Event AmplificatioN (OCEAN). This technique can detect fragments of DNA, which pass from an upper chamber through the test root filling materials into a lower chamber. Significantly more Resilon® specimens leaked compared to gutta-percha using this method

In a fluid filtration model of three months duration, Resilon® showed increased leakage resistance compared to gutta-percha (81). Warm vertical compaction of each filling type was used. However, both Resilon® and gutta-percha showed increased leakage potential as time progressed. Paqué found that although Resilon® and gutta-percha exhibited similar leakage rates after one week in a fluid filtration model, Resilon leaked significantly more frequently following 16 months of storage in saline solution (82). Paqué suggests that the bond of Resilon® to root dentin may be prone to degradation by the presence of moisture in the dentin.

In a dual chamber bacterial leakage model, Resilon® and gutta-percha leaked to a similar degree although the average penetration time through Resilon was just over three days and the average penetration time through gutta-percha was observed to be 10 days (83). In a 50-day bacteria leakage model using Enterococcus faecalis as the test bacterium, Resilon® and gutta-percha

exhibited similar leakage characteristics demonstrating complete bacterial penetration by one month (84). Warm vertical compaction techniques were used but the respective sealers were only allowed to set for three days before being subjected to leakage.

Adhesives in Dentistry

A number of early studies suggested that bonding agents could have the potential to be sealer substitutes in endodontics (85-87). Under such circumstances, removing the smear layer with an acid allows penetration of low viscosity resins into the dentinal tubules (88). Ahlberg tested two modified bonding agents in a dye leakage study and noted the formation of numerous resin tags, which penetrated dentinal tubules in the gutta-percha filled teeth despite the fact that the smear layer was not removed. The bonding agent did not deteriorate despite the teeth being immersed in saline for three months (89). Chersoni found that when three-step total-etch adhesives were used on root dentin, no fluid droplets formed underneath the cured adhesive but that when self -etch adhesives were applied, droplets did form underneath the hydrophilic adhesive layer (90). The author suggests that these droplets of water may increase stress levels in the bond between the tooth and the adhesive leading to bond deterioration. The primer used with current formulations of Resilon® is a self-etch primer, which would come under the category of self-etch adhesives.

Optimal application of primer does not occur with current methods as recommended by manufacturers of bonded root filling materials. Furthermore,

the carrier component in the primer is not removed effectively by absorbing the excess with dry paper points. One of the consequences of these limitations is a decrease in bond strength. (91).

Another study concluded that two-step self-etch adhesives were not significantly inferior to three-step adhesives in terms of bond strength and durability, but that all adhesive systems tested degraded noticeably within three months of application (92). Hydrolysis of both dentin and adhesive components in vivo is a problem in bonded root canal fillings, which has not been adequately addressed yet. It is also known that the character of root canal dentin changes according to the location, with tubule density and orientation varying considerably (93). This topographic variation may effect the quality of any bond formed there.

Gesi demonstrated interesting bond failure characteristics when gutta-percha and Resilon® were used to fill root canals (94). Using an *in vitro* push-out test design, the most common bond failure in the gutta-percha group occurred between the filling and the resin sealer. When the Resilon® bond failed, this most commonly occurred at the sealer/root interface at loads significantly lower than those required to cause bond failure in the gutta-percha group. Hiraishi reported the bond of a typical microhybrid composite to Next®, a methacrylate-based resin sealer, to be four times stronger than the bond between Resilon and Next® (70). Although the bond failures were of a mixed and cohesive nature with the composite controls, the bond failures between Resilon® and Next® were adhesive in nature, calling into question the bond between the latter two materials. Nakabayashi removed the smear layer prior to applying a bonding

agent to root dentin and described the formation of a hybrid layer of resin and dentin (95). This finding was deemed to represent a durable bond by the authors. A significantly stronger bond has been reported to exist between root dentin and a bonded composite compared to the bond between root dentin and glass ionomer sealer (96). This paper also alluded to the presence of resin microtags, which had penetrated patent dentinal tubules. A dye leakage test showed that significantly less leakage occurred when a dentin bonding agent was used in addition to a resin sealer in gutta-percha filled teeth (97). Another study concluded that the bond strengths of two adhesives used for bonding to coronal dentin were slightly lower when applied to root dentin (98).

Mjor reported on the decreased density and diameter of dentinal tubules in apical root dentin (99). This may increase the importance of any hybrid layer formed between root filling adhesives and intertubular dentin. The author states that a layer of cementum can be present up to 2 mm inside the root canal, which can affect the bonding characteristics of the dentin in this area. Other research has concluded that the majority of retention when using dentin adhesives in root canals is derived from micromechanical retention from the collagen in the intertubular dentin (100,101). However, Kanca concluded that it is not possible to control the wetness of the hybrid layer in the apical part of a root canal, a variable that is critical to the bond strength of this interface (102). In light of such evidence, it is apparent that achieving a reliable adhesive bond in the apical third of root canals is not predictable using current materials and methods.

Resin sealers in thin layers generate high forces during polymerization contraction (103). Such forces can cause gap formation between bonded root fillings and root dentin if the bond is not sufficiently strong enough to resist these forces. In root canals, the geometry is highly unfavorable for adhesive bonding. The extremely high ratio of bonded surfaces to unbonded surfaces of resin sealer in a root canal (configuration factor) places very high stress levels on the bond from polymerization contraction. Configuration factors are deemed unfavorable for bonding when they exceed 3:1(104), but in a root canal, they are far greater than this (105). Some portions of the catalyst in self-cured resins are basic in nature. Such components can be neutralized by acidic self-etching primers such as Epiphany, resulting in less effective polymerization. It is known that current hydrophilic primers can interact with water in dentin resulting in a weakening of the adhesive bond. Recent studies have looked at the possibility of using a more hydrophobic primer to avoid this situation (106,107). Other studies have looked at ways of reducing the effects of polymerization shrinkage with the use of indirect bonded core materials in root canals, although such protocols are still in the early stage of development (108).

Thermafil®

In a dye leakage study where a zinc oxide sealer was used, Beatty demonstrated superior leakage characteristics for Thermafil compared to laterally compacted gutta percha (109). Lares employed a dye leakage model to show similar leakage properties for Thermafil® and laterally compacted gutta percha in

curved molar root canals but improved leakage results when using laterally compacted gutta-percha in straight canals of anterior teeth (110). Several dye leakage studies have shown laterally compacted gutta-percha to leak significantly less than Thermafil® (111), (112), (113).

Gençoglu found significantly less leakage using Thermafil® compared to laterally compacted gutta-percha in a dye leakage study whether the smear layer was present or not, however, removing the smear layer significantly reduced leakage in both groups (114).

Dummer carried out a dye leakage study, which showed no difference in the leakage properties of Thermafil® and laterally condensed gutta-percha in straight canals but did demonstrate significantly less leakage using Thermafil® in curved canals (115). In addition, the lateral condensation technique was reported to be considerably slower to complete than the Thermafil® technique.

Bhambhani showed that Thermafil® and warm vertically compacted gutta-percha showed similar leakage characteristics in a dye leakage study (116). In another *in vitro* study, Thermafil® demonstrated significantly less leakage when the smear layer was removed and additional vertical compaction was performed around the Thermafil® carrier (117).

A dye leakage study showed significantly increased leakage when Thermafil® carriers were devoid of gutta-percha on their apical halves (118). This study attempted to replicate the leakage characteristics of Thermafil® when filling material is stripped away from the carrier on insertion into a canal. However, it is unclear whether the removal of the entire apical half of the gutta-percha coating

is a theoretical rather than a clinically relevant model for comparison in such studies. Furthermore, it was impossible to distinguish radiographically between the polymer carrier, gutta-percha and the sealer in this study.

Gençoglu concluded that Thermafil® leaked significantly less than both cold laterally compacted and warm vertically compacted gutta-percha (119). In addition, Thermafil® exhibited the highest core filling to sealer ratio (it must be remembered that the “core” alluded to in this paper includes the plastic carrier in Thermafil®, which is a distinct entity which is not chemically bonded to the surrounding gutta-percha.

De Deus proposed that non-circular shaped canals might be more effectively filled using a warm gutta-percha technique rather than cold lateral compaction. However, he showed no significant difference in sealing ability between Thermafil®, cold lateral and warm vertical compaction techniques in a dye leakage study of oval shaped canals (120).

In a fluid filtration study, vertically compacted gutta-percha fillings were shown to leak significantly less than Thermafil® when 3 mm of root filling remained in curved canals (121). Pommel showed that Thermafil® and warm vertically compacted gutta-percha leaked to a similar degree in another fluid filtration study (122). Interestingly, Pommel found no correlation between three successive in vitro leakage tests in determining the leakage resistance of Thermafil®, although a bacterial leakage model was not among the leakage models used. Karagenç subjected laterally compacted and Thermafil® root fillings to four leakage tests (123). The fluid filtration test suggested that the

laterally condensed fillings leaked less, the dye leakage and electrochemical tests suggested no difference in leakage values between the filling materials and the bacteria leakage test resulted in less leakage with Thermafil®. This study elegantly demonstrates the lack of correlation between different *in vitro* leakage models.

Siqueira compared Thermafil® with cold lateral and warm vertical condensation techniques using a dual chamber bacterial leakage model (53). Evidence of bacterial penetration through the entire root filling was observed in 75% to 90% of cases depending on the root filling technique used but no one technique was significantly superior when statistical analysis of the data was carried out. Gilbert performed dye leakage and bacteria leakage tests on a selection of root filled teeth (124). With bacterial leakage testing, vertically compacted gutta-percha showed significantly better leakage properties than laterally compacted gutta-percha. Thermafil® did not perform significantly better than the lateral compaction group, however. The dye leakage test did not find any difference in leakage properties among the three groups.

Hugh described how Thermafil® and warm vertically compacted gutta-percha demonstrated better sealer coverage of the root canal walls than laterally condensed gutta-percha but that all filling techniques showed inconsistent and incomplete sealer coverage (125). Jarrett described Thermafil® fillings occupying 97% of the root canal space, comparing favorably to 92% or more of the cross sectional area occupied by warm vertical and cold lateral compaction techniques (126). Gutmann deemed the radiographic appearance of Thermafil® to be

superior to laterally compacted gutta-percha fillings in the first in a series of two papers (127). In the second paper of the series, the author found similar leakage rates for Thermafil® and laterally compacted gutta-percha fillings at different time points after the root fillings were placed, and the leakage rates increased with time (128).

Usage Studies

The use of non-human primates for endodontic usage tests has been recommended because their dental anatomy and supporting tissues are strikingly similar to the same tissues in humans. The anatomy of the teeth allows enhanced ability to effectively isolate the teeth with rubber dam clamps without the necessity of modifying existing equipment (129). Beagle dog teeth are more conical in nature and this makes isolation of these teeth challenging in comparison.

Pascon assessed periapical tissue responses up to three years after the placement of gutta-percha root fillings in primate subjects (129). Sealers in the first two groups were based on either a resin or on zinc oxide. The third root filling protocol used gutta-percha points dipped in chloroform. Inflammation of varying degrees was observed in all three groups at all time-points. Another study assessed periapical tissue inflammation in primates for up to six months after placement of the root fillings (130). Teeth were instrumented 1 mm short of the radiographic apex, but periapical inflammation was histologically evident in almost one third of the samples examined one to six months following the root

treatments. This study did not use rubber dam clamps, and instead isolated the teeth with the aid of floss ligatures; four of the 60 teeth demonstrated histological evidence of bacteria in the root canal space, which the author suggested may have been due to contamination of root canals during the instrumentation phase. The author also states that use of the Brown and Brenn in this study may have underestimated the presence of bacteria, as gram-negative bacteria do not stain readily when using this stain. Holland undertook a usage study involving canine subjects and demonstrated that the type of sealer used with a root filling material can influence periapical inflammation (131). In addition, deliberately creating patency in the teeth of these subjects resulted in increased periapical inflammation. In any such study, deliberately creating patency may introduce a confounder which could significantly alter histologic outcomes. Pereira exposed gutta-percha fillings to oral fluids for 45 days in another canine usage model (132). Only 4 mm of root filling remained at the beginning of the experiment, and three sealers were compared using a dye leakage model. There was no statistically significant difference in leakage values between AH Plus®, an epoxy-resin sealer, a silicone sealer, and an urethane dimethacrylate sealer. In one of the first studies that used an *in vivo* model to test the resistance of root filling materials to coronal leakage, Friedman performed a dog study comprising four subjects and subdivided the selected premolar teeth (the second, third and fourth mandibular premolars) into six treatment groups (133). Independent variables included the root filling material used (gutta-percha and sealer, sealer alone, gutta-percha alone) and whether the tooth was inoculated with plaque or not.

After 14 weeks, a third of the teeth containing gutta-percha and sealer exhibited no inflammation on histology. The author suggests that a minimum of six dogs are used in future research, with 56 roots being required to demonstrate any significant differences between groups. Friedman carried out a later study in six dogs where the resistance of gutta-percha to bacterial penetration when using two different sealer products was assessed (134). Autologous plaque was placed directly above the root filling and a coronal seal was then placed over the plaque. Periapical inflammation was classified as none, mild or severe. 84% of the roots filled using KT-308 sealer and gutta-percha were free of inflammation periapically whereas only 54% of the roots filled using Roth's sealer and gutta-percha were inflammation free periapically after the six month observation period. In an *in vivo* study, gutta-percha filled teeth were inoculated with isologous plaque, and a 2 mm white MTA® orifice plug was placed over half of the root fillings (135). Mild histological inflammation was seen in 17% of the roots with the MTA® orifice plug and in 39% of the roots with no orifice plug. However, no severe inflammation was seen on histology in any of the experimental teeth after 10 months. The main conclusions to be drawn from this paper are that (1) the presence of inflammation is itself a highly variable outcome variable when root filled teeth are inoculated with plaque samples, and (2) an MTA® orifice barrier may only marginally reduce coronal leakage in the *in vivo* situation. In a more recent study, Yamauchi showed that when an IRM® or composite orifice barrier was placed over root fillings, just under 40% of such teeth exhibited periapical inflammation after an eight-month period compared to just under 90% of teeth lacking such a

barrier showing periapical inflammation (136). Shipper assessed the presence of apical periodontitis after filling root canals with either gutta-percha/AH26® or with Resilon®/Epiphany® in beagle dogs (137). Shipper inoculated the experimental teeth with autologous plaque and placed coronal seals. The plaque was replaced on several occasions before the dogs were sacrificed. There was significantly less inflammation around teeth filled with Resilon® compared to those filled with gutta-percha. In a canine study where the experimental root fillings were left exposed to oral fluids, Leonardo found significantly less periapical inflammation in Resilon® filled teeth compared to gutta-percha filled teeth when no coronal seal was present (138). It should be noted that one of the negative control groups in this study (the gutta-percha filled teeth with a coronal seal) actually demonstrated more periapical inflammation than the Resilon group lacking a coronal seal.

Human Outcome Studies

Chu and colleagues performed a clinical outcome study, which compared laterally compacted gutta percha with Thermafil® root fillings in a variety of tooth types (139). This study had a good recall rate of over 80% and teeth were assessed three years after treatments were completed. A resin sealer was used with both filling types. The Thermafil® group showed an 81% healing rate and the laterally compacted group demonstrated 79% healing. Gagliani found that 48% of teeth with periapical lesions had completely healed two years after root treatment was performed using Thermafil® obturation material (140). A recent

clinical outcome study of Resilon® root fillings showed complete radiographic healing in 75% of cases followed up for a minimum of one year (141). A further 23% of cases demonstrated partial healing at the 1 year radiographic evaluation. When the body of literature is considered in its entirety, a lack of consensus remains regarding which root canal filling protocol offers the best resistance to coronal microleakage.

Introduction For Submission to Peer-Reviewed Journal

Contemporary endodontic treatment is a product of two primary fields of research, namely, understanding the biological mechanisms that lead to the development of periapical disease, and secondly, applying clinical interventions designed to reverse this process. Periapical inflammation can be induced by accidental trauma, injury from instrumentation, or irritation from chemicals and endodontic materials (8). Infection of the root canal system is a prerequisite for the development of periapical disease (2, 3, 4, 5, 6). The initial reaction of the periapical tissues to bacteria or their byproducts is a non-specific acute response, which comprises vasodilation, increased vascular permeability, and extravasation of neutrophils (9). Macrophages dominate the later phase of the acute response (8).

A recent review of outcome studies for uninfected teeth reported success rates of up to 95% (11). When teeth develop apical periodontitis, the prognosis decreases, with reported success rates ranging from 75% to 90% (12) (13) (14). If a root canal filling material is capable of preventing coronal microleakage in a tooth that is uninfected, then optimal success rates can be anticipated.

The purpose of this study was to compare the sealing ability of Thermafil®, a carrier-based gutta-percha product with Epiphany® a Resilon®-containing carrier-based product, in a canine model when no coronal seal is

present. Thermafil® has been available for almost 20 years, but the original concept was discussed in a paper by Johnson in 1978 (17). In 1989, Thermafil®, a commercial product based on Johnson's original concept, was introduced to the dental market. Thermafil® consists of a resin-based polymer core which is coated in alpha-phase gutta-percha. The Epiphany® Soft Resin Endodontic Obturation System (Pentron® Clinical Technologies, LLC) includes a choice of Resilon® points or pellets as the core filling material, which facilitates the use of both lateral and vertical compaction techniques. The root filling can be bonded to the root canal using either the original Epiphany® Sealer used with Epiphany® Self-Etch Primer or a new Epiphany® SE Self-Etch Sealer, which eliminates the priming step. A carrier-based version of the core material used in the Epiphany® Soft Resin Endodontic Obturation System has been recently developed. The carrier is a polysulfone-containing polymer with radio-opaque fillers and the surrounding Resilon® filling contains polycaprolactone and polyolefin polymers loaded with fillers. A carrier-based version of Epiphany® was compared to Thermafil® in this current usage study. Although there have been numerous *in vitro* leakage studies comparing the leakage resistance of root filling materials, the number of *in vivo* usage studies of both traditional and more contemporary root filling materials is relatively limited.

Literature Review for Submission to Peer-Reviewed Journal

There are several limitations to *in vitro* endodontic leakage studies in the literature (23, 24). One limitation relates to a lack of statistical power partly due to small sample sizes, raising questions regarding the validity of conclusions made in such studies (24). *In vitro* studies have used dyes (26, 27), water (32), the passage of electric currents (33) and bacterial strains (36) as markers for coronal leakage. Other reseachers have concluded that endotoxins pass through root filled teeth at a faster rate than their associated bacteria (37, 38, 39). The shortcomings when applying adhesive technology to endodontics have been addressed in numerous studies (90 - 94,102 -107). The Epiphany® product tested in this study uses such bonding technology. Thermafil® has been subjected to numerous *in vitro* leakage tests (109 – 128). Similarly, Resilon® - containing products have been tested under similar conditions (72 – 84). Usage tests have compared leakage rates *in vivo* using various combinations of root filling products and sealers (132 – 138). Human outcome studies of Thermafil® and Resilon® - containing products have demonstrated similar success rates for these materials compared to other root filling products on the market (39, 40, 41).

Materials and Methods

Group Assignment

Eight beagle dogs approximately three years old were selected for this study. Treatment was performed on eight premolars per dog (Dog 5 received treatment on 10 lower premolars). A total of 66 premolars were treated in this study. Within each dog, three teeth were filled with Epiphany®, three teeth were filled with Thermafil®, one tooth received an Epiphany® filling with a coronal seal and one tooth received a Thermafil® filling with a coronal seal. The teeth in each dog were randomized in the following manner. Each treatment intervention was assigned a name which was written on a small card. Three cards were labeled "Epiphany®", three cards were labeled "Thermafil®", and two cards were labeled "Control". For Dog 5, an additional "Epiphany®" card and an additional "Thermafil®" card were completed, as this dog received 10 interventions. All cards were placed in a box and the cards were mixed by hand. The cards were drawn in succession in a blinded manner and the selected interventions were assigned to teeth in the selected dog in the following order:

Left Jaw: 1st premolar, 2nd premolar, 3rd premolar, 4th premolar

Right Jaw: 1st premolar, 2nd premolar, 3rd premolar, 4th premolar

The protocol followed was approved by the University of North Carolina Institutional Animal Care and Use Committee (IACUC). Customized radiographic bite-stents were used to achieve consistent radiographic angulations during the study. Pre-operative radiographs were taken of the teeth to be treated and no radiographic evidence of periapical pathology was observed. To assist the taking of radiographs, medetomidine 1 mg/M2 (milligrams per square meter of body surface area) was used intramuscularly for sedation purposes and aptimazole 1 mg/kg was deposited subcutaneously for sedation reversal at the completion of radiographic procedures. Treatment was performed under general anesthesia. Induction was achieved with pentothal 13.5 mg/kg IV (Abbott Laboratories, North Chicago, Illinois). Up to 2% isoflurane (Halocarbon Laboratories, River Edge, New Jersey) was used for maintenance supplemented with 0.5 ml per quadrant of plain 0.5 percent bupivicaine (Abbott Laboratories, North Chicago, Illinois) to achieve local anesthesia of the inferior alveolar nerve. To minimize post-operative pain, tramadol 3 mg/kg was administered orally to each dog every 12 hours for two days prior to treatment. This was complemented with a post-operative subcutaneous injection containing 0.2 mg/kg of butorphanol (Fort Dodge, IA). To reduce the chance of post-operative infection, an intramuscular injection of 20,000 units per kg of Penicillin G was administered following treatment. Staff in the Department of Laboratory Animal Medicine monitored the post-operative recovery of each subject. The dogs were monitored daily for the duration of the study to ensure that they were consuming their normal diet and that no clinical signs of infection were evident.

A strict aseptic protocol was followed prior to all treatment procedures. All lower premolar teeth were cleaned of debris using moist gray pumice. Rubber dam isolation using sterile rubber dam clamps was carried out and Cavit® (3M® ESPE, St. Paul, MN) was used to optimize the seal around individual teeth as required. 10% povidone-iodine (Medical Supply Co.Inc. New York, NY) was applied generously to the teeth and to the surrounding area to optimize aseptic conditions. The occlusal surface of each lower premolar was reduced by approximately 2 mm and occlusal access cavities were prepared in each tooth using a sterile round carbide bur (SS White Burs Inc. Lakewood,NJ) in an air-turbine dental handpiece under constant sterile saline irrigation. On accessing the pulp chamber, access cavities were completed using an Endo-Z® Bur (Dentsply Maillefer, Tulsa, OK). The presence of vital pulp tissue after accessing all 66 teeth confirmed that none of the experimental teeth were infected. As beagle dog premolar roots have closed apices, working lengths were established using tactile sense, supported by information obtained from pre-operative radiographs. Following confirmation of a glide path, each root canal was instrumented in a crown-down fashion using K3® NiTi rotary files (SybronEndo Corp., Orange, CA) of progressively decreasing taper to a final apical size of ISO 45 (apical taper of .04mm/mm). Each root was irrigated with 1 mL of 1.25% sodium hypochlorite (Clorox Company, Oakland, CA) between files using a 10 ml syringe and a 30-guage nickel-titanium irrigating needle (Vista Dental Products, Racine, WI). When instrumentation was complete, canals were irrigated with 2 ml of 17% ethylenediaminetetraacetic acid (EDTA), (Vista Dental Products, Racine,

WI), applied over one minute. Each canal was then flushed with 2 ml of sterile water followed by a 2 mL final rinse of 2% chlorhexidine (Vista Dental Products, Racine, WI). Sterile paper points (Dentsply Maillefer, Tulsa, OK) were used to dry each canal. A separate set of instruments was used for each of the experimental root filling materials to avoid mixing of the different root filling products.

Group 1: Epiphany® (n = 25)

A size verifier was used to determine that the obturator size to be used was appropriate. Epiphany® self-etching sealer was removed from refrigeration and allowed to reach room temperature prior to use. The sealer was applied in each root canal using a lentulo spiral rotating in the canal at 300 rpm. Epiphany® obturators were disinfected for one minute in 2% chlorhexidine (Vista Dental Products, Racine, WI), rinsed with sterile water and dried with sterile gauze. The obturators were heated in a ThermaPrep® Plus Oven and inserted without delay in the prepared canals at the end of a full heating cycle indicated by a double beep, following manufacturer's instructions. The handle of each obturator was stabilized while the carrier was sectioned at the orifice level. Excess filling material surrounding the carrier was compacted apically using Buchanan pluggers. Excess sealer was removed from the pulp chamber using alcohol and sterile cotton pellets. The coronal surface of the root filling was light cured for 40 seconds to create an immediate coronal seal. After preparing the dentin in the access cavity with GC® dentin conditioner (GC America Inc., Alsip, IL) a small sterile chlorhexidine-containing cotton pellet was placed on the floor of the pulp

chamber. The access cavity was sealed with Fuji IX® GP FAST (GC America Inc., Alsip, IL). The coronal seal was removed after one week. This was done to allow sufficient time for the sealer to set fully.

Group 2: Thermafil® (n = 25)

A size verifier was used to determine that the obturator size to be used was appropriate. Thermaseal® Plus sealer was applied in each root using a lentulo spiral rotating at 300 rpm. Thermafil® obturators were disinfected for one minute in 2% chlorhexidine (Vista Dental Products, Racine, WI), rinsed with sterile water and dried with sterile gauze. Each obturator was heated in a ThermaPrep® Plus Oven until an audible signal indicated that the obturator was ready for placement. It was then inserted without delay into the prepared root canal. The handle of each obturator was stabilized while the carrier was sectioned at the orifice level. Excess gutta-percha surrounding the carrier was compacted apically using Buchanan pluggers, according to the manufacturer's instructions. A small sterile chlorhexidine-containing cotton pellet was placed on the floor of the pulp chamber and the access cavity was sealed with Fuji® IX GP FAST (GC America Inc., Alsip, IL). The coronal seal was removed after one week. This was done to allow sufficient time for the sealer to set fully.

Group 3: Empty Control (n = 8)

Teeth in this group were instrumented and were then left completely empty for the duration of the study.

Group 4: Sealed Control (n = 8)

Teeth in this group were instrumented and root-filled with an Epiphany® obturator (n=4) or with a Thermafil® obturator (n=4). Each tooth received a glass ionomer coronal seal using Fuji® IX GP FAST (GC America Inc., Alsip, IL). This coronal seal was left intact for the duration of the study.

Radiographs were taken of teeth immediately after they were root treated. The dogs were inspected on a daily basis to ensure that they were consuming their allotted diet and that there was no evidence of any swelling or infection in the oral cavity. All eight dogs remained in good overall health and consumed a normal diet for the duration of the study. No soft tissue swelling or sinus tract indicative of periapical disease developed in any subject.

After four months, the dogs were sacrificed using an intravenous barbiturate overdose of 6% pentobarbital (Butler Company, Columbus, OH) dosed at 120 mg/kg. The carotid arteries were surgically exposed and canulated. The dogs were perfused with 10% neutral buffered formalin. Jaw blocks containing the lower premolars were resected and were fixed in 10% phosphate-buffered formalin. All mucoperiosteal tissue was removed from the resected blocks. The blocks were decalcified in 10% EDTA and then embedded in

paraffin. Prepared serial longitudinal sections were approximately five microns thick and included both the root canal space and the surrounding periapical tissues. Sections were made in a mesio-distal plane parallel to the long axis of each root until each root canal reached its most apical extent within the root. Alternating serial sections were then mounted and stained with either Hematoxylin & Eosin (H&E) or Brown & Brenn (B&B) stains. Examination of specimens was performed using an Olympus BH Light microscope connected to a Spot RT camera (Diagnostic Images, Inc.).

H&E stained specimens were examined under a light microscope using up to 1000x magnification by two blinded, calibrated evaluators (DD and PZT). A binary scale of measurement was used to assess the histologic outcome regarding inflammation:

No inflammation:

Periodontal Ligament (PDL) of normal width and architecture. Few / no inflammatory cells visible in the periapical tissues. Trabecular bone of normal architecture and density in close proximity to the PDL (Figure 1)

Inflammation:

PDL of increased width containing numerous inflammatory cells and an irregular distribution of trabecular bone surrounding the PDL (Figure 2)

Brown and Brenn stained specimens were examined at 1000x magnification under a light microscope using an oil immersion objective lens by two blinded evaluators (DD and PZT). Infection of the root dentin was assessed according to the following binary scale:

No bacteria present:

No visible bacterial aggregations on any of the root canal walls or within individual dentinal tubules (Figure 3)

Bacteria present:

Bacteria aggregations visible on root canal walls and / or within individual dentinal tubules (Figure 4)

Data Analysis

We performed a stratified analysis to test the association between inflammation and filling type and also between infection and filling type. In doing so, we controlled for any dog or tooth position effect using the Cochrane Mantel Haentzel test. The tests were carried out at the 0.05 significance level.

Results

66 teeth were treated in this study. Two of the teeth were lost (both teeth were in the Thermafil® group) during histological sectioning leaving 64 teeth for analysis. Histologic analysis of inflammation was carried out on 60 teeth as a definitive diagnosis could not be made regarding inflammation presence in four teeth due to the quality of the histologic specimens (four Thermafil® teeth). Histologic analysis of infection was carried out on 61 teeth as histologic specimens from three teeth (two Thermafil® teeth and one Epiphany® tooth) were not of adequate diagnostic quality. Fisher's Exact Test showed that treatment types were well distributed across the different tooth types as well as across the right and left sides of the jaws ($p=0.258$). This confirmed that randomization was successful.

Histological Evidence of Inflammation

There was no statistically significant difference in the number of teeth with inflamed periapical tissue on histology across the eight dogs ($p=0.13$), across the five tooth types ($p=0.54$), across the right jaw and left jaw ($p=0.48$) or across the treatment groups ($p=0.38$). 9% of the Epiphany® group showed inflammation, whereas 29% of the Thermafil® group were inflamed (Table 1). When controlling for a dog effect, there was no statistically significant difference in inflammation

presence between any of the groups studied ($p>0.05$) (Table 2). When controlling for a tooth position effect (1st, 2nd, 3rd or 4th premolar), the Epiphany® group had 9% of teeth with inflammation compared to 29% of the Thermafil® group. This difference was statistically significant ($p<0.05$) (Table 2).

Histological Evidence of Infection

There was no significant difference in the proportion of teeth with evidence of bacteria across the eight dogs ($p=0.95$) or across the five tooth positions ($p=0.49$). 9% of the Epiphany® teeth were infected, whereas 70% of the Thermafil® teeth were infected (Table 3). None of the eight empty controls were infected and 12% of the sealed controls were infected. The difference in infection rates between Epiphany® and Thermafil® was statistically significant when controlling for dog and for tooth position ($p<0.01$) (Table 4).

There was no statistically significant difference in the proportion of infected teeth between Epiphany® and the control groups ($p>0.05$) when controlling for dog and for tooth position (Table 4). There was a statistically significant difference in the infection rate of the Thermafil® group compared to the negative control groups when controlling for dog and for tooth position ($p<0.01$) (Table 4).

Relationship between Outcome Parameters

There was a statistically significant correlation between histological evidence of inflammation and histological evidence of infection ($p=0.002$). 78% of inflamed teeth contained visible bacterial colonies in the root canal system,

whereas only 22% of teeth that were free of inflammation were visibly infected. This finding suggests that histologic evidence of inflammation may be a suitable surrogate marker for evidence of coronal microleakage in usage models.

Discussion

The purpose of this study was to subject two contemporary root filling products to a continuous 4-month microbial challenge in an *in vivo* model using histologic markers to assess coronal leakage. The histologic outcomes were determined by analyzing prepared histologic specimens of all treated teeth. The first histologic marker was evidence of an inflammatory response in the periapical tissues and the second histologic marker was evidence of bacterial colonization of root dentin.

In this study, no radiographic assessment of periapical inflammation was made. However, De Rossi has shown in a canine model that evidence of early-stage periapical inflammation, even if present, is poorly detected using either conventional or digital radiography (142). A high correlation has been shown between histology and digital subtraction radiography regarding the presence of periapical inflammation in dogs, and such an approach may be considered by other researchers in future usage studies(143).

Beagle dogs do not possess a principal patent foramen, and a previous canine usage study similar to this one created patency in the teeth prior to root filling placement (138). In this current study where the natural apical delta of accessory canals was maintained, there was a significantly lower incidence of periapical inflammation across the five treatment groups. The problem with trying

to replicate human apical anatomy by creating patency in teeth in the canine model is that an uncontrolled confounder is introduced. There is an assumption that teeth across all treatment groups will be overinstrumented to a similar degree and that the inflammatory response to this arbitrary assault on the periapical tissues will be consistent across all teeth. Another canine study showed a significantly higher incidence of inflamed periapical tissues when teeth were deliberately overinstrumented and patency was maintained compared to when patency was not maintained prior to root filling placement (131). Inflammation incidence appears to be related to how the apical third of the tooth is instrumented in canine subjects. Consequently, periapical inflammation may not be a suitable surrogate marker for coronal leakage in the dog model when uninfected root filled teeth are exposed to oral fluids. It should be emphasized that several previous usage tests using canine subjects inoculated root filled teeth prior to placing coronal seals. This latter approach has been shown to consistently induce periapical inflammation in a relatively short time (144-146).

When all teeth were assessed for evidence of infection, there was no statistically significant difference observed between the Epiphany® group and the control groups. Only one of the 16 control teeth (a sealed control tooth) showed evidence of bacteria within the root canal. This may be due to initial contamination of the root canal during instrumentation, a hazard which has been documented in a previous usage study (130).

In the Thermafil® group, 16 of 23 teeth (70%) showed evidence of bacteria in the root canal dentin, whereas two of 22 teeth (9%) in the Epiphany®

group demonstrated infected root canals. This difference was statistically significant ($p < .0001$). Teeth were considered to be infected when chains of cocci could be observed within the dentinal tubules of the root. A biofilm adhering to the root canal wall containing further aggregations of bacteria was observed in a large proportion of these teeth. The presence of cocci in the lumen of the root canals was not considered to be adequate evidence of an infected root canal, as bacteria could easily be spread from the coronal aspect of teeth across the lumen during the slide preparation process. In all cases where Brown and Brenn stained specimens demonstrated the presence of bacteria in dentinal tubules, a similar pattern of cocci in the tubules was observed in successive Hematoxylin and Eosin specimens taken from the same root. Brown and Brenn stains do not consistently stain gram-negative bacteria, which would be expected to comprise the majority of endodontic pathogens (130). Several studies have shown that 30% or more of infected teeth may not show histologic evidence of bacteria in dentinal tubules using conventional staining techniques (147, 148). Therefore, the significant limitations of using histological specimens to derive conclusions relating to coronal leakage cannot be underestimated.

Conclusion

The aim of this study was to compare the coronal leakage resistance of two carrier-based root-filling products *in vivo*. A dog model was used in which Epiphany® and Thermafil® root fillings were exposed to oral fluids for 4 months. When a histological inflammatory response was considered as a surrogate marker for coronal leakage, the Epiphany® group (9% inflamed) showed a lower frequency of inflammation than the Thermafil® group (29% inflamed). When the presence of bacteria in dentinal tubules was used as an indicator of coronal leakage, the Epiphany® group contained two infected teeth compared to nine infected teeth in the Thermafil® group. This difference was highly statistically significant ($p<0.001$). Both of the histologic outcome measures used in this study have limitations, and it is widely recognized that the physics of current adhesive technology cannot produce a satisfactory bond between a root filling and the surrounding root. Despite such shortcomings, Epiphany® appeared to resist bacterial penetration more effectively than Thermafil® under the conditions of this usage model. This would suggest that a consistent homogenous bond throughout the root canal system may not be the critical factor in preventing coronal microleakage.

Tables

Table 1: Histologic Inflammation (1): Distribution of Teeth among Two Outcomes

Treatment	Healthy (%)	Inflamed (%)	Total (%)
Epiphany®	21 (91)	2 (9)	23 (100)
Thermafil®	15 (71)	6 (29)	21 (100)
Empty Control	7 (88)	1 (12)	8 (100)

Table 2: Histolologic Inflammation (2): Comparing Rates among all Groups

Treatment Groups **(% Inflamed)**	**p-value** Controlling for dog effect	**p-value** Controlling for dog effect
Epiphany® (9%) and Thermafil® (29%)	0.132	**0.046***
Epiphany® (9%) and empty control (12.5%)	0.259	0.248
Epiphany® (9%) and sealed control (0%)	0.414	0.564
Thermafil® (29%) and empty control (12.5%)	1.000	0.345
Thermafil® (29%) and sealed control (0%)	0.134	0.101

* results in bold with an asterisk are statistically significant at the level of 0.05

Table 3: Histologic Infection (1): Distribution of Teeth among Two Outcomes

Treatment	Healthy (%)	Inflamed (%)	Total (%)
Epiphany®	20 (91)	2 (9)	22 (100)
Thermafil®	7 (30)	16 (70)	23 (100)
Empty Control	8 (100)	0 (0)	8 (100)
Sealed control	7 (87.5)	1 (12.5)	8 (100)

Table 4: Histologic Infection (2): Comparing Rates among all Groups

Treatment **(% Infected)**	**p-value** Controlling for dog effect	**p-value** Controlling for tooth effect
Epiphany® (9%) and Thermafil® (70%)	**0.0001 ***	**0 .0001***
Epiphany® (9%) and empty control (0%)	0.414	0.519
Epiphany® (9%) and sealed control (12.5%)	0.829	0.782
Thermafil® (70%) and empty control (0%)	**0.002***	**0.001***
Thermafil® (70%) and sealed control (12.5%)	**0.011***	**0.012***

* results in bold with an asterisk are statistically significant at the level of 0.05

Figures

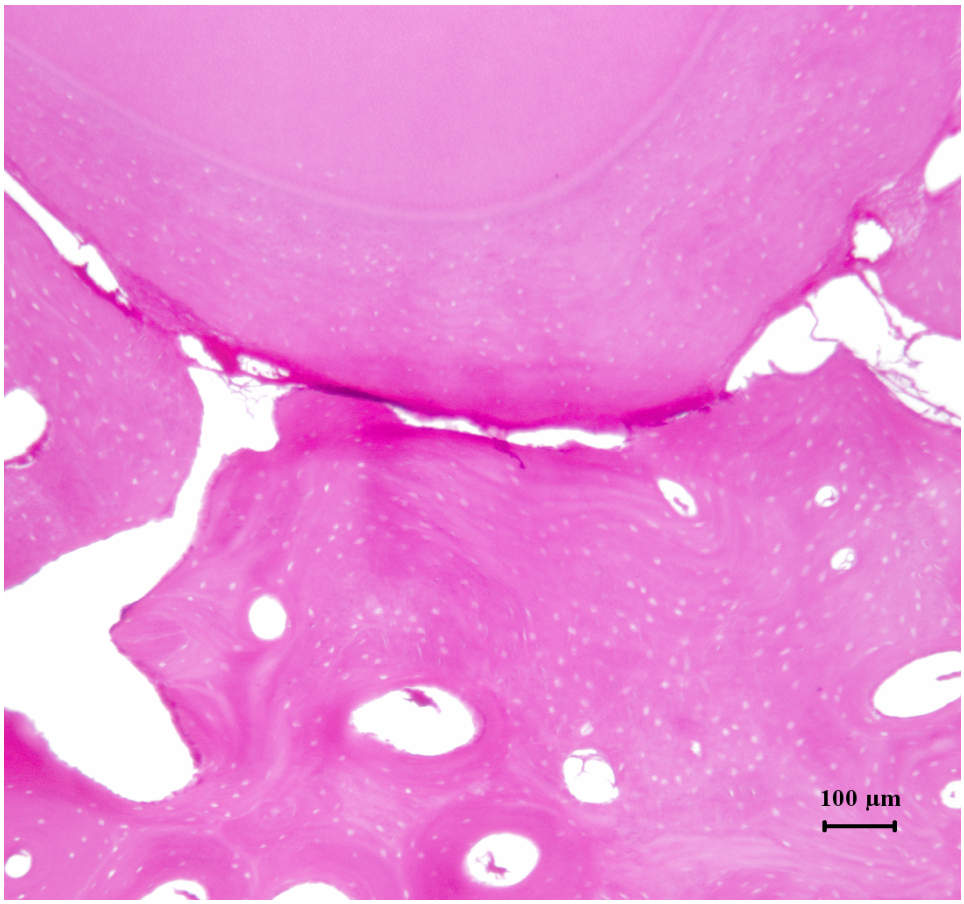

Figure 1: Histologic Health

Organized trabecular bone and a PDL of minimal thickness devoid of inflammatory cells surround the apex of this root (Specimen taken from the negative Thermafil® group).

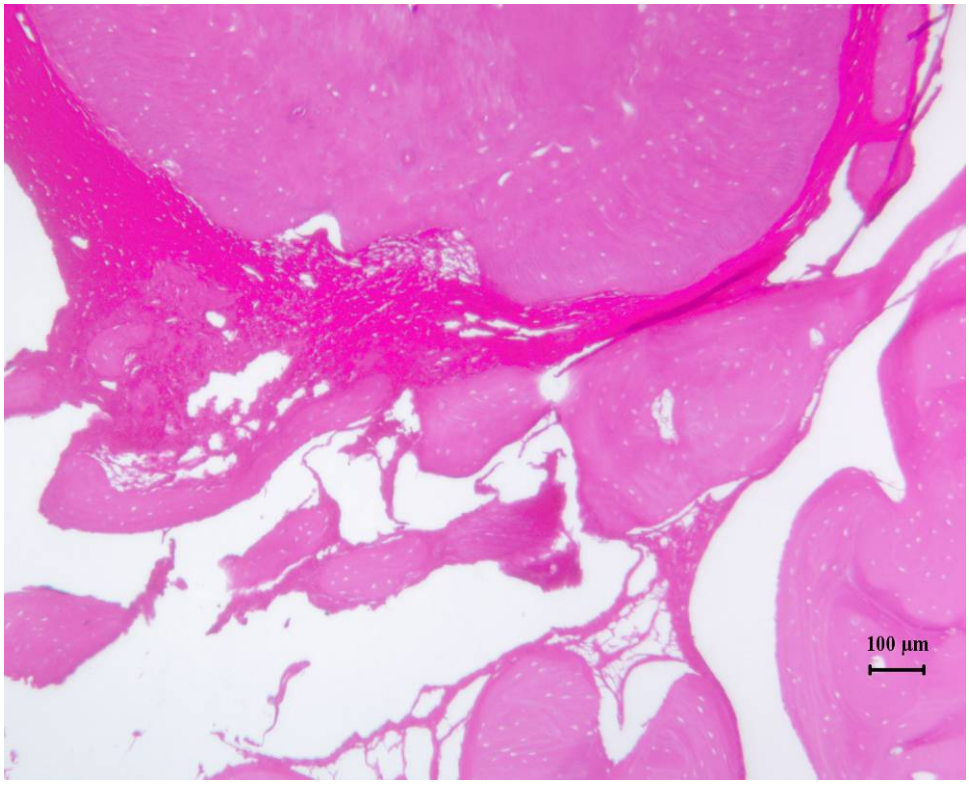

Figure 2: Histologic Inflammation

Disorganized, fragmented trabecular bone surrounds thickened PDL tissue which has been infiltrated by numerous inflammatory cells (Specimen taken from the Epiphany® group).

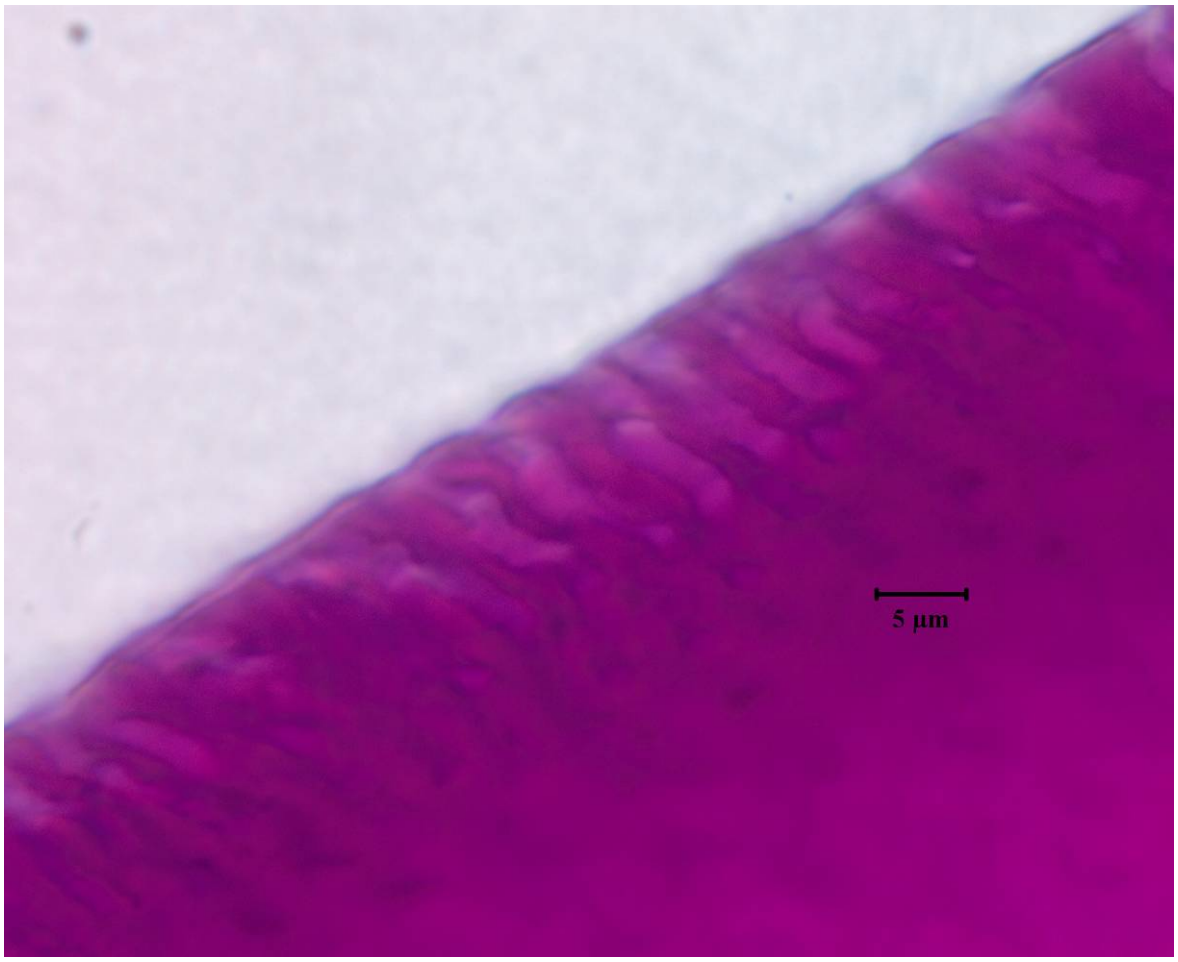

Figure 3: Bacteria-Free Root Dentin

This image shows a portion of a root canal wall with patent, bacteria-free dentinal tubules (Specimen taken from Epiphany® group).

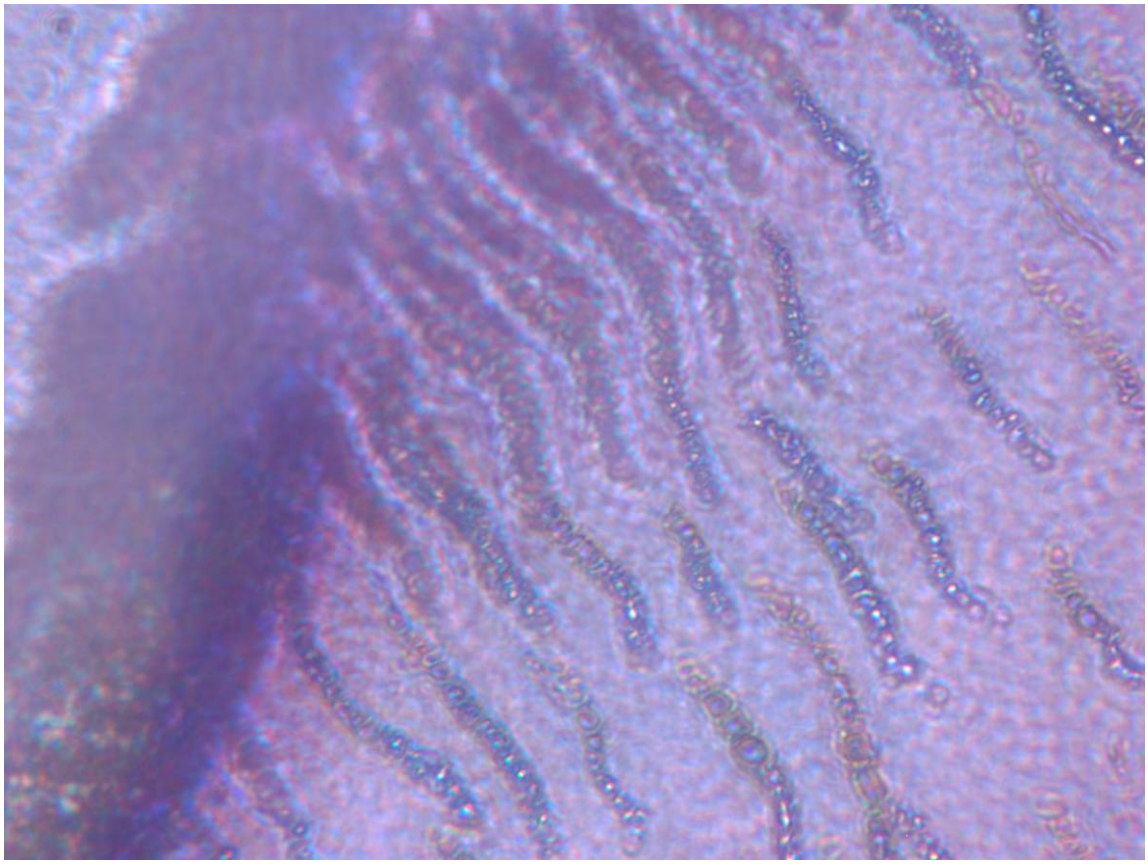

5 µm

Figure 4: Infected Root Dentin

A biofilm on the root canal wall is visible on the left side of this image magnified at 1000x. The underlying dentinal tubules contain numerous bacteria (Specimen taken from the Thermafil® group).

References

(1) Miller WD. The Micro-Organisms of the Human Mouth. Philadelphia: White Dental; 1890.

(2) KAKEHASHI S, STANLEY HR, FITZGERALD RJ. The Effects of Surgical Exposures of Dental Pulps in Germ-Free and Conventional Laboratory Rats. Oral Surg.Oral Med.Oral Pathol. 1965 Sep;20:340-349.

(3) Moller AJ, Fabricius L, Dahlen G, Ohman AE, Heyden G. Influence on periapical tissues of indigenous oral bacteria and necrotic pulp tissue in monkeys. Scand.J.Dent.Res. 1981 Dec;89(6):475-484.

(4) G. Sundqvist. Bacteriological studies of necrotic dental pulps. Sweden: University of Umea; 1976.

(5) Baumgartner gJC, Falkler WA,Jr. Bacteria in the apical 5 mm of infected root canals. J.Endod. 1991 Aug;17(8):380-383.

(6) Fabricius L, Dahlen G, Holm SE, Moller AJ. Influence of combinations of oral bacteria on periapical tissues of monkeys. Scand.J.Dent.Res. 1982 Jun;90(3):200-206.

(7) Mullis KB, Faloona FA. Specific synthesis of DNA in vitro via a polymerase-catalyzed chain reaction. Methods Enzymol. 1987;155:335-350.

(8) Nair PN. Pathogenesis of apical periodontitis and the causes of endodontic failures. Crit.Rev.Oral Biol.Med. 2004 Nov 1;15(6):348-381.

(9) Stashenko P, Teles R, D'Souza R. Periapical inflammatory responses and their modulation. Crit.Rev.Oral Biol.Med. 1998;9(4):498-521.

(10) Hess W. Formation of root canal in human teeth. J Natl Dent Assoc 1921;3:704-734.

(11) Basmadjian-Charles CL, Farge P, Bourgeois DM, Lebrun T. Factors influencing the long-term results of endodontic treatment: a review of the literature. Int.Dent.J. 2002 Apr;52(2):81-86.

(12) Bystrom A, Happonen RP, Sjogren U, Sundqvist G. Healing of periapical lesions of pulpless teeth after endodontic treatment with controlled asepsis. Endod.Dent.Traumatol. 1987 Apr;3(2):58-63.

(13) Sjogren U, Hagglund B, Sundqvist G, Wing K. Factors affecting the long-term results of endodontic treatment. J.Endod. 1990 Oct;16(10):498-504.

(14) Peters LB, Wesselink PR. Periapical healing of endodontically treated teeth in one and two visits obturated in the presence or absence of detectable microorganisms. Int.Endod.J. 2002 Aug;35(8):660-667.

(15) Noyes E. Fifty years of root canal fillings. J.Am.Dent.Assoc. 1922;1:784-794.

(16) Schilder H. Filling root canals in three dimensions. Dent.Clin.North Am. 1967 Nov:723-744.

(17) Johnson WB. A new gutta-percha technique. J.Endod. 1978 Jun;4(6):184-188.

(18) Teixeira FB, Teixeira EC, Thompson J, Leinfelder KF, Trope M. Dentinal bonding reaches the root canal system. J.Esthet.Restor.Dent. 2004;16(6):348-54; discussion 354.

(19) Ray HA, Trope M. Periapical status of endodontically treated teeth in relation to the technical quality of the root filling and the coronal restoration. Int.Endod.J. 1995 Jan;28(1):12-18.

(20) Ricucci D, Bergenholtz G. Bacterial status in root-filled teeth exposed to the oral environment by loss of restoration and fracture or caries--a histobacteriological study of treated cases. Int.Endod.J. 2003 Nov;36(11):787-802.

(21) Tronstad L, Asbjornsen K, Doving L, Pedersen I, Eriksen HM. Influence of coronal restorations on the periapical health of endodontically treated teeth. Endod.Dent.Traumatol. 2000 Oct;16(5):218-221.

(22) Saunders WP, Saunders EM. Coronal leakage as a cause of failure in root-canal therapy: a review. Endod.Dent.Traumatol. 1994 Jun;10(3):105-108.

(23) Wu MK, Wesselink PR. Endodontic leakage studies reconsidered. Part I. Methodology, application and relevance. Int.Endod.J. 1993 Jan;26(1):37-43.

(24) Schuurs AH, Wu MK, Wesselink PR, Duivenvoorden HJ. Endodontic leakage studies reconsidered. Part II. Statistical aspects. Int.Endod.J. 1993 Jan;26(1):44-52.

(25) Swanson K, Madison S. An evaluation of coronal microleakage in endodontically treated teeth. Part I. Time periods. J.Endod. 1987 Feb;13(2):56-59.

(26) Magura ME, Kafrawy AH, Brown CE,Jr, Newton CW. Human saliva coronal microleakage in obturated root canals: an in vitro study. J.Endod. 1991 Jul;17(7):324-331.

(27) Khayat A, Lee SJ, Torabinejad M. Human saliva penetration of coronally unsealed obturated root canals. J.Endod. 1993 Sep;19(9):458-461.

(28) Kontakiotis EG, Georgopoulou MK, Morfis AS. Dye penetration in dry and water-filled gaps along root fillings. Int.Endod.J. 2001 Mar;34(2):133-136.

(29) Camps J, Pashley D. Reliability of the dye penetration studies. J.Endod. 2003 Sep;29(9):592-594.

(30) Michailesco PM, Valcarcel J, Grieve AR, Levallois B, Lerner D. Bacterial leakage in endodontics: an improved method for quantification. J.Endod. 1996 Oct;22(10):535-539.

(31) Matloff IR, Jensen JR, Singer L, Tabibi A. A comparison of methods used in root canal sealability studies. Oral Surg.Oral Med.Oral Pathol. 1982 Feb;53(2):203-208.

(32) Derkson GD, Pashley DH, Derkson ME. Microleakage measurement of selected restorative materials: a new in vitro method. J.Prosthet.Dent. 1986 Oct;56(4):435-440.

(33) Jacobson SM, von Fraunhofer JA. The investigation of microleakage in root canal therapy. An electrochemical technique. Oral Surg.Oral Med.Oral Pathol. 1976 Dec;42(6):817-823.

(34) Amditis C, Bryant RW, Blackler SM. The assessment of apical leakage of root-filled teeth by the electrochemical technique. Aust.Dent.J. 1993 Feb;38(1):22-27.

(35) Barthel CR, Moshonov J, Shuping G, Orstavik D. Bacterial leakage versus dye leakage in obturated root canals. Int.Endod.J. 1999 Sep;32(5):370-375.

(36) Torabinejad M, Ung B, Kettering JD. In vitro bacterial penetration of coronally unsealed endodontically treated teeth. J.Endod. 1990 Dec;16(12):566-569.

(37) Warfvinge J, Dahlen G, Bergenholtz G. Dental pulp response to bacterial cell wall material. J.Dent.Res. 1985 Aug;64(8):1046-1050.

(38) Trope M, Chow E, Nissan R. In vitro endotoxin penetration of coronally unsealed endodontically treated teeth. Endod.Dent.Traumatol. 1995 Apr;11(2):90-94.

(39) Alves J, Walton R, Drake D. Coronal leakage: endotoxin penetration from mixed bacterial communities through obturated, post-prepared root canals. J.Endod. 1998 Sep;24(9):587-591.

(40) Goldman M, Simmonds S, Rush R. The usefulness of dye-penetration studies reexamined. Oral Surg.Oral Med.Oral Pathol. 1989 Mar;67(3):327-332.

(41) Wu MK, De Gee AJ, Wesselink PR, Moorer WR. Fluid transport and bacterial penetration along root canal fillings. Int.Endod.J. 1993 Jul;26(4):203-208.

(42) AliGhamdi A, Wennberg A. Testing of sealing ability of endodontic filling materials. Endod.Dent.Traumatol. 1994 Dec;10(6):249-255.

(43) Editorial Board of the Journal of Endodontics. Wanted: a base of evidence. J.Endod. 2007 Dec;33(12):1401-1402.

(44) Facer SR, Walton RE. Intracanal distribution patterns of sealers after lateral condensation. J.Endod. 2003 Dec;29(12):832-834.

(45) Zmener O, Spielberg C, Lamberghini F, Rucci M. Sealing properties of a new epoxy resin-based root-canal sealer. Int.Endod.J. 1997 Sep;30(5):332-334.

(46) Madison S, Swanson K, Chiles SA. An evaluation of coronal microleakage in endodontically treated teeth. Part II. Sealer types. J.Endod. 1987 Mar;13(3):109-112.

(47) Madison S, Wilcox LR. An evaluation of coronal microleakage in endodontically treated teeth. Part III. In vivo study. J.Endod. 1988 Sep;14(9):455-458.

(48) Kopper PM, Figueiredo JA, Della Bona A, Vanni JR, Bier CA, Bopp S. Comparative in vivo analysis of the sealing ability of three endodontic sealers in post-prepared root canals. Int.Endod.J. 2003 Dec;36(12):857-863.

(49) De Moor RJ, De Bruyne MA. The long-term sealing ability of AH 26 and AH plus used with three gutta-percha obturation techniques. Quintessence Int. 2004 Apr;35(4):326-331.

(50) Gernhardt CR, Kruger T, Bekes K, Schaller HG. Apical sealing ability of 2 epoxy resin-based sealers used with root canal obturation techniques based on warm gutta-percha compared to cold lateral condensation. Quintessence Int. 2007 Mar;38(3):229-234.

(51) Cobankara FK, Adanr N, Belli S. Evaluation of the influence of smear layer on the apical and coronal sealing ability of two sealers. J.Endod. 2004 Jun;30(6):406-409.

(52) Kontakiotis EG, Wu MK, Wesselink PR. Effect of sealer thickness on long-term sealing ability: a 2-year follow-up study. Int.Endod.J. 1997 Sep;30(5):307-312.

(53) Wu MK, Wesselink PR, Boersma J. A 1-year follow-up study on leakage of four root canal sealers at different thicknesses. Int.Endod.J. 1995 Jul;28(4):185-189.

(54) Siqueira JF,Jr, Rocas IN, Favieri A, Abad EC, Castro AJ, Gahyva SM. Bacterial leakage in coronally unsealed root canals obturated with 3 different techniques. Oral Surg.Oral Med.Oral Pathol.Oral Radiol.Endod. 2000 Nov;90(5):647-650.

(55) Almeida JF, Gomes BP, Ferraz CC, Souza-Filho FJ, Zaia AA. Filling of artificial lateral canals and microleakage and flow of five endodontic sealers. Int.Endod.J. 2007 Sep;40(9):692-699.

(56) Gettleman BH, Messer HH, ElDeeb ME. Adhesion of sealer cements to dentin with and without smear layer. Endodoncia 1991 Apr-Jun;9(2):83-91.

(57) Allan NA, Walton RC, Schaeffer MA. Setting times for endodontic sealers under clinical usage and in vitro conditions. J.Endod. 2001 Jun;27(6):421-423.

(58) Wennberg A, Orstavik D. Adhesion of root canal sealers to bovine dentine and gutta-percha. Int.Endod.J. 1990 Jan;23(1):13-19.

(59) Lee KW, Williams MC, Camps JJ, Pashley DH. Adhesion of endodontic sealers to dentin and gutta-percha. J.Endod. 2002 Oct;28(10):684-688.

(60) Saleh IM, Ruyter IE, Haapasalo M, Orstavik D. The effects of dentine pretreatment on the adhesion of root-canal sealers. Int.Endod.J. 2002 Oct;35(10):859-866.

(61) Shipper G, Trope M. In vitro microbial leakage of endodontically treated teeth using new and standard obturation techniques. J.Endod. 2004 Mar;30(3):154-158.

(62) Shipper G, Orstavik D, Teixeira FB, Trope M. An evaluation of microbial leakage in roots filled with a thermoplastic synthetic polymer-based root canal filling material (Resilon). J.Endod. 2004 May;30(5):342-347.

(63) Tay FR, Pashley DH, Williams MC, Raina R, Loushine RJ, Weller RN, et al. Susceptibility of a polycaprolactone-based root canal filling material to degradation. I. Alkaline hydrolysis. J.Endod. 2005 Aug;31(8):593-598.

(64) Tay FR, Pashley DH, Yiu CK, Yau JY, Yiu-fai M, Loushine RJ, et al. Susceptibility of a polycaprolactone-based root canal filling material to degradation. II. Gravimetric evaluation of enzymatic hydrolysis. J.Endod. 2005 Oct;31(10):737-741.

(65) Hiraishi N, Yau JY, Loushine RJ, Armstrong SR, Weller RN, King NM, et al. Susceptibility of a polycaprolactone-based root canal-filling material to

degradation. III. Turbidimetric evaluation of enzymatic hydrolysis. J.Endod. 2007 Aug;33(8):952-956.

(66) Yourtee DM, Smith RE, Russo KA, Burmaster S, Cannon JM, Eick JD, et al. The stability of methacrylate biomaterials when enzyme challenged: kinetic and systematic evaluations. J.Biomed.Mater.Res. 2001 Dec 15;57(4):522-531.

(67) Tay FR, Loushine RJ, Weller RN, Kimbrough WF, Pashley DH, Mak YF, et al. Ultrastructural evaluation of the apical seal in roots filled with a polycaprolactone-based root canal filling material. J.Endod. 2005 Jul;31(7):514-519.

(68) Teixeira FB, Teixeira EC, Thompson JY, Trope M. Fracture resistance of roots endodontically treated with a new resin filling material. J.Am.Dent.Assoc. 2004 May;135(5):646-652.

(69) Williams C, Loushine RJ, Weller RN, Pashley DH, Tay FR. A comparison of cohesive strength and stiffness of Resilon and gutta-percha. J.Endod. 2006 Jun;32(6):553-555.

(70) Hiraishi N, Papacchini F, Loushine RJ, Weller RN, Ferrari M, Pashley DH, et al. Shear bond strength of Resilon to a methacrylate-based root canal sealer. Int.Endod.J. 2005 Oct;38(10):753-763.

(71) Tay FR, Hiraishi N, Pashley DH, Loushine RJ, Weller RN, Gillespie WT, et al. Bondability of Resilon to a methacrylate-based root canal sealer. J.Endod. 2006 Feb;32(2):133-137.

(72) Silveira FF, Soares JA, Nunes E, Mordente VL. Negative influence of continuous wave technique on apical sealing of the root canal system with Resilon. J.Oral Sci. 2007 Jun;49(2):121-128.

(73) Kaya BU, Kececi AD, Belli S. Evaluation of the sealing ability of gutta-percha and thermoplastic synthetic polymer-based systems along the root canals through the glucose penetration model. Oral Surg.Oral Med.Oral Pathol.Oral Radiol.Endod. 2007 Dec;104(6):e66-73.

(74) Raina R, Loushine RJ, Weller RN, Tay FR, Pashley DH. Evaluation of the quality of the apical seal in Resilon/Epiphany and Gutta-Percha/AH Plus-filled root canals by using a fluid filtration approach. J.Endod. 2007 Aug;33(8):944-947.

(75) Sagsen B, Er O, Kahraman Y, Akdogan G. Resistance to fracture of roots filled with three different techniques. Int.Endod.J. 2007 Jan;40(1):31-35.

(76) Tunga U, Bodrumlu E. Assessment of the sealing ability of a new root canal obturation material. J.Endod. 2006 Sep;32(9):876-878.

(77) Onay EO, Ungor M, Orucoglu H. An in vitro evaluation of the apical sealing ability of a new resin-based root canal obturation system. J.Endod. 2006 Oct;32(10):976-978.

(78) Biggs SG, Knowles KI, Ibarrola JL, Pashley DH. An in vitro assessment of the sealing ability of resilon/epiphany using fluid filtration. J.Endod. 2006 Aug;32(8):759-761.

(79) Stratton RK, Apicella MJ, Mines P. A fluid filtration comparison of gutta-percha versus Resilon, a new soft resin endodontic obturation system. J.Endod. 2006 Jul;32(7):642-645.

(80) Pasqualini D, Scotti N, Mollo L, Berutti E, Angelini E, Migliaretti G, et al. Microbial leakage of Gutta-Percha and Resilon root canal filling material: a comparative study using a new homogeneous assay for sequence detection. J.Biomater.Appl. 2008 Jan;22(4):337-352.

(81) Wedding JR, Brown CE, Legan JJ, Moore BK, Vail MM. An in vitro comparison of microleakage between Resilon and gutta-percha with a fluid filtration model. J.Endod. 2007 Dec;33(12):1447-1449.

(82) Paque F, Sirtes G. Apical sealing ability of Resilon/Epiphany versus gutta-percha/AH Plus: immediate and 16-months leakage. Int.Endod.J. 2007 Sep;40(9):722-729.

(83) Munoz HR, Saravia-Lemus GA, Florian WE, Lainfiesta JF. Microbial leakage of Enterococcus faecalis after post space preparation in teeth filled in vivo with RealSeal versus Gutta-percha. J.Endod. 2007 Jun;33(6):673-675.

(84) Baumgartner G, Zehnder M, Paque F. Enterococcus faecalis type strain leakage through root canals filled with Gutta-Percha/AH plus or Resilon/Epiphany. J.Endod. 2007 Jan;33(1):45-47.

(85) Torabinejad M, Kahn H, Bankes D. Isopropyl cyanoacrylate as a root canal sealer. J.Endod. 1984 Jul;10(7):304-307.

(86) Zidan O, ElDeeb ME. The use of a dentinal bonding agent as a root canal sealer. J.Endod. 1985 Apr;11(4):176-178.

(87) Hammond RM, Meyers IA. A laboratory investigation of a composite resin/dentine bonding agent mixture used as a root canal sealer. Aust.Dent.J. 1992 Jun;37(3):178-184.

(88) Tidmarsh BG. Acid-cleansed and resin-sealed root canals. J.Endod. 1978 Apr;4(4):117-121.

(89) Ahlberg KM, Tay WM. A methacrylate-based cement used as a root canal sealer. Int.Endod.J. 1998 Jan;31(1):15-21.

(90) Chersoni S, Acquaviva GL, Prati C, Ferrari M, Grandini S, Pashley DH, et al. In vivo fluid movement through dentin adhesives in endodontically treated teeth. J.Dent.Res. 2005 Mar;84(3):223-227.

(91) Tay FR, Pashley DH, Yoshiyama M. Two modes of nanoleakage expression in single-step adhesives. J.Dent.Res. 2002 Jul;81(7):472-476.

(92) De Munck J, Van Landuyt K, Peumans M, Poitevin A, Lambrechts P, Braem M, et al. A critical review of the durability of adhesion to tooth tissue: methods and results. J.Dent.Res. 2005 Feb;84(2):118-132.

(93) Ferrari M, Mannocci F, Vichi A, Cagidiaco MC, Mjor IA. Bonding to root canal: structural characteristics of the substrate. Am.J.Dent. 2000 Oct;13(5):255-260.

(94) Gesi A, Raffaelli O, Goracci C, Pashley DH, Tay FR, Ferrari M. Interfacial strength of Resilon and gutta-percha to intraradicular dentin. J.Endod. 2005 Nov;31(11):809-813.

(95) Nakabayashi N, Ashizawa M, Nakamura M. Identification of a resin-dentin hybrid layer in vital human dentin created in vivo: durable bonding to vital dentin. Quintessence Int. 1992 Feb;23(2):135-141.

(96) Leonard JE, Gutmann JL, Guo IY. Apical and coronal seal of roots obturated with a dentine bonding agent and resin. Int.Endod.J. 1996 Mar;29(2):76-83.

(97) Mannocci F, Ferrari M. Apical seal of roots obturated with laterally condensed gutta-percha, epoxy resin cement, and dentin bonding agent. J.Endod. 1998 Jan;24(1):41-44.

(98) Mannocci F, Sherriff M, Ferrari M, Watson TF. Microtensile bond strength and confocal microscopy of dental adhesives bonded to root canal dentin. Am.J.Dent. 2001 Aug;14(4):200-204.

(99) Mjor IA, Smith MR, Ferrari M, Mannocci F. The structure of dentine in the apical region of human teeth. Int.Endod.J. 2001 Jul;34(5):346-353.

(100) Tagami J, Tao L, Pashley DH. Correlation among dentin depth, permeability, and bond strength of adhesive resins. Dent.Mater. 1990 Jan;6(1):45-50.

(101) Pereira PN, Okuda M, Sano H, Yoshikawa T, Burrow MF, Tagami J. Effect of intrinsic wetness and regional difference on dentin bond strength. Dent.Mater. 1999 Jan;15(1):46-53.

(102) Kanca J,3rd. Wet bonding: effect of drying time and distance. Am.J.Dent. 1996 Dec;9(6):273-276.

(103) Feilzer AJ, De Gee AJ, Davidson CL. Increased wall-to-wall curing contraction in thin bonded resin layers. J.Dent.Res. 1989 Jan;68(1):48-50.

(104) Yoshikawa T, Sano H, Burrow MF, Tagami J, Pashley DH. Effects of dentin depth and cavity configuration on bond strength. J.Dent.Res. 1999 Apr;78(4):898-905.

(105) Carvalho RM, Pereira JC, Yoshiyama M, Pashley DH. A review of polymerization contraction: the influence of stress development versus stress relief. Oper.Dent. 1996 Jan-Feb;21(1):17-24.

(106) Sadek FT, Pashley DH, Nishitani Y, Carrilho MR, Donnelly A, Ferrari M, et al. Application of hydrophobic resin adhesives to acid-etched dentin with an alternative wet bonding technique. J.Biomed.Mater.Res.A. 2008 Jan;84(1):19-29.

(107) Tay FR, Pashley DH, Kapur RR, Carrilho MR, Hur YB, Garrett LV, et al. Bonding BisGMA to dentin--a proof of concept for hydrophobic dentin bonding. J.Dent.Res. 2007 Nov;86(11):1034-1039.

(108) Bouillaguet S, Bertossa B, Krejci I, Wataha JC, Tay FR, Pashley DH. Alternative adhesive strategies to optimize bonding to radicular dentin. J.Endod. 2007 Oct;33(10):1227-1230.

(109) Beatty RG, Baker PS, Haddix J, Hart F. The efficacy of four root canal obturation techniques in preventing apical dye penetration. J.Am.Dent.Assoc. 1989 Nov;119(5):633-637.

(110) Lares C, elDeeb ME. The sealing ability of the Thermafil obturation technique. J.Endod. 1990 Oct;16(10):474-479.

(111) Barkins W, Montgomery S. Evaluation of Thermafil obturation of curved canals prepared by the Canal Master-U system. J.Endod. 1992 Jun;18(6):285-289.

(112) Chohayeb AA. Comparison of conventional root canal obturation techniques with Thermafil obturators. J.Endod. 1992 Jan;18(1):10-12.

(113) Baumgardner KR, Taylor J, Walton R. Canal adaptation and coronal leakage: lateral condensation compared to Thermafil. J.Am.Dent.Assoc. 1995 Mar;126(3):351-356.

(114) Gencoglu N, Samani S, Gunday M. Evaluation of sealing properties of Thermafil and Ultrafil techniques in the absence or presence of smear layer. J.Endod. 1993 Dec;19(12):599-603.

(115) Dummer PM, Lyle L, Rawle J, Kennedy JK. A laboratory study of root fillings in teeth obturated by lateral condensation of gutta-percha or Thermafil obturators. Int.Endod.J. 1994 Jan;27(1):32-38.

(116) Bhambhani SM, Sprechman K. Microleakage comparison of thermafil versus vertical condensation using two different sealers. Oral Surg.Oral Med.Oral Pathol. 1994 Jul;78(1):105-108.

(117) Taylor JK, Jeansonne BG, Lemon RR. Coronal leakage: effects of smear layer, obturation technique, and sealer. J.Endod. 1997 Aug;23(8):508-512.

(118) Lee CQ, Cobb CM, Robinson SJ, LaMartina T, Vo T. In vitro evaluation of the Thermafil technique with and without gutta percha coating. Gen.Dent. 1998 Jul-Aug;46(4):378-381.

(119) Gencoglu N, Garip Y, Bas M, Samani S. Comparison of different gutta-percha root filling techniques: Thermafil, Quick-fill, System B, and lateral condensation. Oral Surg.Oral Med.Oral Pathol.Oral Radiol.Endod. 2002 Mar;93(3):333-336.

(120) De-Deus G, Audi C, Murad C, Fidel S, Fidel RA. Sealing ability of oval-shaped canals filled using the System B heat source with either gutta-percha or Resilon: an ex vivo study using a polymicrobial leakage model. Oral Surg.Oral Med.Oral Pathol.Oral Radiol.Endod. 2007 Oct;104(4):e114-9.

(121) Fan B, Wu MK, Wesselink PR. Leakage along warm gutta-percha fillings in the apical canals of curved roots. Endod.Dent.Traumatol. 2000 Feb;16(1):29-33.

(122) Pommel L, Camps J. In vitro apical leakage of system B compared with other filling techniques. J.Endod. 2001 Jul;27(7):449-451.

(123) Karagenc B, Gencoglu N, Ersoy M, Cansever G, Kulekci G. A comparison of four different microleakage tests for assessment of leakage of root canal fillings. Oral Surg.Oral Med.Oral Pathol.Oral Radiol.Endod. 2006 Jul;102(1):110-113.

(124) Gilbert SD, Witherspoon DE, Berry CW. Coronal leakage following three obturation techniques. Int.Endod.J. 2001 Jun;34(4):293-299.

(125) Hugh CL, Walton RE, Facer SR. Evaluation of intracanal sealer distribution with 5 different obturation techniques. Quintessence Int. 2005 Oct;36(9):721-729.

(126) Jarrett IS, Marx D, Covey D, Karmazin M, Lavin M, Gound T. Percentage of canals filled in apical cross sections - an in vitro study of seven obturation techniques. Int.Endod.J. 2004 Jun;37(6):392-398.

(127) Gutmann JL, Saunders WP, Saunders EM, Nguyen L. A assessment of the plastic Thermafil obturation technique. Part 1. Radiographic evaluation of adaptation and placement. Int.Endod.J. 1993 May;26(3):173-178.

(128) Gutmann JL, Saunders WP, Saunders EM, Nguyen L. An assessment of the plastic Thermafil obturation technique. Part 2. Material adaptation and sealability. Int.Endod.J. 1993 May;26(3):179-183.

(129) Pascon EA, Leonardo MR, Safavi K, Langeland K. Tissue reaction to endodontic materials: methods, criteria, assessment, and observations. Oral Surg.Oral Med.Oral Pathol. 1991 Aug;72(2):222-237.

(130) Orstavik D, Mjor IA. Usage test of four endodontic sealers in Macaca fascicularis monkeys. Oral Surg.Oral Med.Oral Pathol. 1992 Mar;73(3):337-344.

(131) Holland R, Sant'Anna Junior A, Souza V, Dezan Junior E, Otoboni Filho JA, Bernabe PF, et al. Influence of apical patency and filling material on healing process of dogs' teeth with vital pulp after root canal therapy. Braz.Dent.J. 2005;16(1):9-16.

(132) Pereira Cda C, de Oliveira EP, Gomes MS, Della-Bona A, Vanni JR, Kopper PM, et al. Comparative in vivo analysis of the sealing ability of three endodontic sealers in dog teeth after post-space preparation. Aust.Endod.J. 2007 Dec;33(3):101-106.

(133) Friedman S, Torneck CD, Komorowski R, Ouzounian Z, Syrtash P, Kaufman A. In vivo model for assessing the functional efficacy of endodontic filling materials and techniques. J.Endod. 1997 Sep;23(9):557-561.

(134) Friedman S, Komorowski R, Maillet W, Klimaite R, Nguyen HQ, Torneck CD. In vivo resistance of coronally induced bacterial ingress by an experimental glass ionomer cement root canal sealer. J.Endod. 2000 Jan;26(1):1-5.

(135) Mah T, Basrani B, Santos JM, Pascon EA, Tjaderhane L, Yared G, et al. Periapical inflammation affecting coronally-inoculated dog teeth with root fillings augmented by white MTA orifice plugs. J.Endod. 2003 Jul;29(7):442-446.

(136) Yamauchi S, Shipper G, Buttke T, Yamauchi M, Trope M. Effect of orifice plugs on periapical inflammation in dogs. J.Endod. 2006 Jun;32(6):524-526.

(137) Shipper G, Teixeira FB, Arnold RR, Trope M. Periapical inflammation after coronal microbial inoculation of dog roots filled with gutta-percha or resilon. J.Endod. 2005 Feb;31(2):91-96.

(138) Leonardo MR, Barnett F, Debelian GJ, de Pontes Lima RK, Bezerra da Silva LA. Root canal adhesive filling in dogs' teeth with or without coronal restoration: a histopathological evaluation. J.Endod. 2007 Nov;33(11):1299-1303.

(139) Chu CH, Lo EC, Cheung GS. Outcome of root canal treatment using Thermafil and cold lateral condensation filling techniques. Int.Endod.J. 2005 Mar;38(3):179-185.

(140) Gagliani MA, Cerutti A, Bondesan A, Colombo M, Godio E, Giacomelli G. A 24-month survey on root canal treatment performed by NiTi engine driven files and warm gutta-percha filling associated system. Minerva Stomatol. 2004 Oct;53(10):543-554.

(141) Conner DA, Caplan DJ, Teixeira FB, Trope M. Clinical outcome of teeth treated endodontically with a nonstandardized protocol and root filled with resilon. J.Endod. 2007 Nov;33(11):1290-1292.

(142) De Rossi A, De Rossi M, Rocha LB, da Silva LA, Rossi MA. Morphometric analysis of experimentally induced periapical lesions: radiographic vs histopathological findings. Dentomaxillofac.Radiol. 2007 May;36(4):211-217.

(143) Delano EO, Tyndall D, Ludlow JB, Trope M, Lost C. Quantitative radiographic follow-up of apical surgery: a radiometric and histologic correlation. J.Endod. 1998 Jun;24(6):420-426.

(144) Katebzadeh N, Sigurdsson A, Trope M. Radiographic evaluation of periapical healing after obturation of infected root canals: an in vivo study. Int.Endod.J. 2000 Jan;33(1):60-66.

(145) Grecca FS, Leonardo MR, da Silva LA, Tanomaru Filho M, Borges MA. Radiographic evaluation of periradicular repair after endodontic treatment of dog's teeth with induced periradicular periodontitis. J.Endod. 2001 Oct;27(10):610-612.

(146) De Rossi A, Silva LA, Leonardo MR, Rocha LB, Rossi MA. Effect of rotary or manual instrumentation, with or without a calcium hydroxide/1% chlorhexidine intracanal dressing, on the healing of experimentally induced chronic periapical lesions. Oral Surg.Oral Med.Oral Pathol.Oral Radiol.Endod. 2005 May;99(5):628-636.

(147) Peters LB, Wesselink PR, Buijs JF, van Winkelhoff AJ. Viable bacteria in root dentinal tubules of teeth with apical periodontitis. J.Endod. 2001 Feb;27(2):76-81.

(148) Matsuo T, Shirakami T, Ozaki K, Nakanishi T, Yumoto H, Ebisu S. An immunohistological study of the localization of bacteria invading root pulpal walls of teeth with periapical lesions. J.Endod. 2003 Mar;29(3):194-200.