

**THE EFFICACY OF TEMPORARY SKELETAL ANCHORAGE VERSUS
MAXILLARY OSTEOTOMY IN TREATMENT OF ANTERIOR OPEN BITE**

Glenn Gibson McCall, III, DDS

A thesis submitted to the faculty of the University of North Carolina at Chapel Hill in partial fulfillment of the requirements for the degree of Master of Science in the School of Dentistry (Orthodontics).

**Chapel Hill
2012**

Approved by:

Ceib Phillips, MPH, PhD

Rose D. Sheats, DDS, MPH

George Blakey, III, DDS

Nicole Scheffler, DDS, MS

©2012
Glenn Gibson McCall, III
ALL RIGHTS RESERVED

ABSTRACT

G. GIBSON MCCALL, III: The Efficacy of Temporary Skeletal Anchorage Versus Maxillary Osteotomy in Treatment of Anterior Open Bites
(Under the direction of Dr. Ceib Phillips)

Treatment modalities for anterior open bites are aimed at superiorly positioning the maxillary dentition. The purpose of this study is to compare the efficacy and stability of closing anterior open bites with either temporary skeletal anchorage (TSA) or maxillary osteotomy. Cephalograms of TSA and surgery patients were digitized at three different time points. Nine measures were compared to analyze treatment changes and relapse. Unstructured covariance variances were considered. All parameters were estimated by REML method. Success was defined as $OB > 0\text{mm}$ at the end of the retention period. Positive mean OB was achieved with both treatment modalities. In the retention period, mean positive OB was maintained, however both groups had minor relapse. Overall success rate of TSA was 88% while surgery had 72%. TSA was as effective in obtaining positive OB as maxillary osteotomy in mild to moderate open bite patients and was shown to be stable for over 2 years.

ACKNOWLEDGEMENTS

I would like to thank the following for their contribution, support and dedication:

Dr. Ceib Phillips, for her mentorship, support and encouragement throughout the development and completion of this project; for her insight and expertise with statistical analysis; and for making what could be a very stressful process so enjoyable.

Dr. Nicole Scheffler, for her tremendous help and advice.

Dr. Rose Sheats for her help and advice with the manuscript.

Ms. Debbie Price, for your time and assistance with data input and table design.

My loving and understanding wife, Emi McCall, for always providing me with her love, assistance, encouragement, wisdom and guidance.

And last, but not least, my two wonderful children, Mac and Eliza, who allow me to keep a proper perspective.

TABLE OF CONTENTS

LIST OF TABLES.....	vi
LIST OF FIGURES.....	vii
I. LITERATURE REVIEW	1
II. MANUSCRIPT INTRODUCTION.....	11
III. MATERIALS AND METHODS.....	15
A. Sample Selection.....	15
B. Cephalometric Analysis	15
C. Statistical Analysis	16
IV. RESULTS	17
V. DISCUSSION	20
VI. CONCLUSIONS.....	24
REFERENCES	36

LIST OF TABLES

Table 1. Treatment Time Points.....	25
Table 2. Mean Skeletal and Dental Measurements.....	26
Table 3. P Values Associated with the Variance Component General Linear Models	27

LIST OF FIGURES

Figure 1. 29-Point Digitization Scheme Landmarks.....	28
Figure 2. Pattern of Change for U1-PP.....	29
Figure 3. Pattern of Change for MPA.....	30
Figure 4. Pattern of Change for U6-PP.....	31
Figure 5. Pattern of Change for PP-SN.....	32
Figure 6. Pattern of Change for OB.....	33
Figure 7. OB Charted for Surgery Patients.....	34
Figure 8. OB Charted for TSA Patients.....	35

I LITERATURE REVIEW

ANTERIOR OPEN BITE

One of the most challenging malocclusions that orthodontists face is an anterior open bite. This malocclusion is often due to excessive vertical development in the posterior maxilla. Conventional orthodontic treatment modalities aimed at intruding the posterior maxillary dentition have proven to be wrought with difficulties. Therefore, a combination of orthodontics and orthognathic surgery has been utilized to surgically move the posterior maxilla superiorly to help close the anterior open bite more predictably. This surgery, however, comes at a high cost to the patient including increased morbidity, risks, and complications. With the application of temporary skeletal anchorage (TSA), orthodontists now have a tool to move teeth in ways not possible before. Absolute intrusion of the maxillary posterior dentition now can be accomplished to close an anterior open bite without a major surgery.

Open Bite Malocclusion

Anterior open bite is characterized by the absence of vertical overlap of the upper and lower incisors. It can be difficult to quantitatively assess a patient's overbite clinically - due to the lack of a stable reference frame. Subtelny and Sakuda provided a way to reproducibly measure the overbite of a patient by using the occlusal plane as a reference on a cephalometric head film¹. The prevalence of anterior open bite has been estimated to be

fairly consistent, 3.3-3.6%, in the age ranges of typical orthodontic patients (8-50 years old). 99% of the anterior open bites were mild, less than 2 mm. A racial discrepancy was present with African Americans being five times more likely than white or Hispanics to have an anterior open bite².

The etiology of the anterior open bite has been related to various factors – aberrant vertical growth, abnormal muscle function or growth (including the tongue), and digit-sucking habits¹. There are two different categories of anterior open bites: dental and skeletal. Dental open bites are most often seen in patients with normal facial growth patterns combined with proclination or infra-eruption of anterior teeth³. They are commonly caused by a digit sucking habit, but have been reported to be due to a tongue posture⁴. Frequently treatment for dental open bites is extractions and retraction of the anterior teeth to close the open bite, commonly called the “draw-bridge effect”³. Skeletal open bites have a more complex presentation. They have an excessive vertical development of the maxillary posterior dentition and complex⁵. This excessive vertical growth manifests itself in a posteriorly tipped palatal plane with maxillary molars supra-erupted causing a down and back rotation of the mandible⁶⁻⁸. As a result of this rotation, the lower face height is increased and the mandibular plane is steepened leading to a long-faced appearance⁹. Frost et al said that the vertical excess often occurs below the palatal plane and the mandibular plane affected secondarily¹⁰. Reyneke and colleagues said that there can be a lack of vertical growth of the mandibular ramus⁵. Dental characteristics of the skeletal open bite include normal or supra-erupted upper incisors when compared to normal facial proportions¹. After considering the characteristics of an anterior open bite, treatment should be aimed at the source of the problem, the posterior maxilla.

Traditional Orthodontic Treatment

Using orthodontics alone closure of an open bite can happen one of two ways: elongation of the anterior teeth or intruding the posterior teeth^{11, 12}. The stability of elongating the anterior teeth is questionable¹², so orthodontically intruding the maxillary posterior dentition is preferred. Various treatments have been attempted to intrude the posterior maxillary dentition. In growing patients, relative intrusion by impeding the vertical growth of the posterior maxilla while allowing the anterior maxilla to grow can be used to prevent an anterior open bite from ultimately occurring. Patients who have completed their growth require absolute intrusion repositioning the dentition apically. This is a difficult movement for orthodontists to produce without side effects such as extrusion of the anterior teeth¹³. The maxillary incisors are not usually infra-erupted so any elongation is undesirable¹. An excessive show of incisors and gingival tissue when smiling would result in an unacceptable clinical result³.

Historically, high-pull headgear has been the treatment of choice for patients who are still growing³. This works to hold the vertical development of the maxillary dentition and impede its normal downward and forward growth vector. Adding a functional splint to the headgear was suggested by Caldwell¹⁴. The splint has been shown to displace the maxilla posteriorly and superiorly creating relative intrusion of the posterior dentition. Another treatment modality used in growing patients is the open bite bionator¹⁵. Vertical-pull chin cups were shown to effectively reduce the plane angle and had some reduction in molar extrusion¹⁶. One common thread among all of these treatment modalities is a high level of cooperation from the patient is required while growth occurs. If excellent cooperation from the patient is not received, successful treatment is nearly impossible.

For the non-growing patients absolute intrusion of the maxillary posterior dentition has been attempted. Posterior bite blocks with or without magnets have been tried with little intrusion obtained^{17,18}. These treatment modalities require a significant amount of intermolar space for a minimum thickness of acrylic which props a patient open even more. The MEAW technique developed by Kim uses a 0.016x0.022 SS wire with multiple boot loops and heavy vertical elastics to attempt to intrude posterior teeth¹⁹. A recent study looking at 21 successfully treated patients with MEAW found that most of the correction occurred by extrusion of the maxillary anterior teeth²⁰. Patients were also found to have significant extrusion of the mandibular posterior teeth with an opening of the mandibular plane angle and a lengthening of the face height. Because of the complexity with the other open bite treatments some practitioners for simplicity's sake just use conventional archwires and anterior vertical elastics to close the bite. This treatment relies solely on the extrusion of anterior teeth to close the open bite.

Operating an efficient orthodontic practice is predicated on having the treatment you are providing to have a high level of stability. Therefore, stability of the treatment modalities is of paramount importance. Lopez-Gavito found the long-term stability (>9 years post-treatment) to be 63.5% using traditional orthodontic treatment with headgear therapy²¹. Janson et al looked at 21 subjects who had non-extraction therapy with intermaxillary elastics to close the anterior open bite²². He reported 61.9% clinical stability (OB>0) at a 5 year follow-up. Remmers et al found that only 71% of patients had a positive overbite more than 5 years post-orthodontic treatment²³. Unfortunately, there were no predictors found for the open bite relapse. Another study found a 74.2% long-term success rate²⁴. Zuroff in 2010 had a sample of patients treated with extractions and headgear and found that all had positive

overbites after 9.5 years, however the sample size was very small²⁵. This finding in the literature was unusual to have no relapse. A recent meta-analysis found that approximately 75% of patients treated for an anterior open bite had positive overlap at the latest follow-up²⁶. Therefore with conventional orthodontics it has been reported that 1 in 3 or 4 patients with an anterior open bite with successful treatment will relapse back to an open bite. This should be a concerning statistic if the open bite precipitated orthodontic therapy. This has led to the continued search for more predictable ways to close an anterior open bite.

Surgical-Orthodontic Treatment

A Le Fort I was first described by Obwegeser in 1969 for correction of discrepancies in maxillary anatomy²⁷. In treatment of an anterior open bite this usually entails superiorly positioning the maxilla with bone removal to allow for appropriate positioning. This allows the mandible to rotate counter-clockwise which decreases the mandibular plane angle and anterior face height while increasing the vertical overlap of the incisors¹⁰. Reyneke and Ferretti said surgical treatment for anterior open bite should be aimed at the anatomic location of the problem – the posterior maxilla. Therefore a LeFort I has traditionally been the recommended treatment for skeletal anterior open bites. If the anterior/posterior discrepancy is too great to be corrected with only maxillary surgery, a bimaxillary procedure can be performed⁵. There has been a lot of research looking at the stability of this surgical procedure due to the predictability of the surgery. Proffit et al in a hierarchy of surgical stability showed superiorly positioning the maxilla was the most stable surgical procedure²⁸.

An impressive study done by Hoppenreijns et al in 1997 looked at 267 patients who had vertical maxillary hyperplasia with an anterior open bite. These patients had maxillary surgery in one or multiple pieces and found no difference in stability over 5 years. 19% of

these patients lacked incisor overlap with a mean overbite of 1.24 mm. It was reported there were compensatory effects from the maxillary and mandibular incisors in the retention period to counter-act the relapse from the surgical movement²⁹.

Similarly, Espeland and colleagues conducted a study examining 40 patients treated with a Le Fort I for correction of an anterior open bite³⁰. These patients were evaluated three years after the single piece osteotomy for stability of the surgical movement and overbite correction. The authors found there was a 31% relapse in the posterior maxilla and 62% relapse in the anterior maxilla which occurred mostly in the first 6 months after surgery, if there was inferior positioning opposite the surgical. 12.5% of the subjects relapsed to negative overbite during the retention period.

Stansbury et al in 2010 suggested that performing a mandibular procedure, bilateral sagittal split osteotomy (BSSO), might be a good alternative to maxillary surgery for an anterior open bite if facial balance would be disproportionately disrupted³¹. 28 patients were examined 1 year post-surgery and all had positive overbite. The authors reported skeletal relapse, however, there was dental compensation for the relapse which allowed the bite to stay closed. Other studies have disagreed with this finding. Maia in 2010 conducted an 8 year follow-up for surgical corrections for anterior open bite. The subjects had either a BSSO, bimaxillary surgery, or a Le Fort I. It was found that the relapse rate of overbite was higher in the mandibular surgery sub-group than the bimaxillary surgery group. The most stable was found to be the maxillary only surgical group³².

Two other studies have looked at long-term stability of surgical correction of an anterior open bite comparing one versus two jaw surgeries. Proffit et al in 2000 and Teittinen et al in 2010 looked at maxillary osteotomies versus bimaxillary surgery^{28, 33}. Both

found that when the surgical correction can be limited to one jaw, more stability was seen^{28, 33}. Vertical relapse of overbite has also been reported to be more likely if a patient had extrusion of incisors during the orthodontic preparation for orthognathic surgery³⁴. It was recommended to let the surgical movement create the overbite correction and make the open bite worse by intruding the incisors, if possible³⁴.

As suggested in a 2000 *Angle Orthodontist* article by Proffit et al, if an appropriate force system could be developed to intrude the maxillary posterior dentition it would provide an alternative to orthognathic surgery. Sherwood in 2007 concluded that intrusion with the use of TSA is a promising alternative to orthognathic surgery and more studies should be performed to evaluate the relapse of patients treated with this treatment modality⁴.

Temporary Skeletal Anchorage

Gainsforth and Higley in 1945 hypothesized if you could use bone as an anchorage unit then stability of treatment would be better³⁵. They placed vitallium screws in a dog mandible for movement of lower canines; however, they had only limited success with the technique. In 1983 Creekmore and Eklund became the first to report in the literature on the clinical use of temporary skeletal anchorage. These authors placed a vitallium bone screw below the anterior nasal spine and used this as anchorage to intrude the maxillary incisors³⁶. Other uses of bone as anchorage came from Melsen et al in 1998 where a steel ligature was placed through the infra-zygomatic crest. This was done in patients who were edentulous in the maxillary posterior to create posterior anchorage³⁷.

Soon after Melsen, Umemori and Sugawara were the first to publish a case report documenting the first use of TSA for closure of an anterior open bite by intrusion of posterior teeth³⁸. They utilized a Skeletal Anchorage System (SAS) where titanium surgical mini-

plates placed in the posterior mandible were used to intrude mandibular molars. The intrusion obtained of the lower molars was 3.5 mm and 5.0 mm which allowed the mandible to rotate closed with very little incisor extrusion to close the patient's anterior open bite³⁸. Sugawara and colleagues followed up this initial paper with a study looking at 9 patients with anterior open bites all treated with the SAS. 4.9 mm of overbite correction and positive overbite was achieved for all patients. These results were maintained for a 1 year follow-up with 18% relapse in overbite and 27-30% relapse in vertical position of the molars, however overbite remained positive in the follow-up period³⁹.

From 2000 to 2010 many case reports were published about the use of TSA for posterior intrusion⁴⁰⁻⁴⁴. All showed that intrusion with TSA is possible and open bites can be closed. Since then, there have been a few retrospective studies looking at treatment changes in groups of patients. Seres in 2009 looked at 7 patients with moderate to severe open bites (4-11 mm) treated with TSA and found that positive overbite was reached for all patients⁴⁵. Xun et al examined 12 patients who had maxillary molar intrusion with TSA⁴⁶. It was found that the upper first molars were intruded 1.8 mm and the mandibular first molars 1.2 mm. Maxillary and mandibular incisors were reported to have extruded 1.3 mm and average overbite correction was 4.2 mm with 2.3° reduction in mandibular plane angle. Erverdi et al targeted just the maxillary molars of 11 patients with the aid of an occlusal splint with heavy trans-palatal arches and I-shaped mini-plates⁴¹. These authors found 3.6 mm of intrusion, 5.1 mm increase in overbite, and 3.0° closure of the mandibular plane angle. No follow-up data was reported for any of these studies.

These preliminary studies show that it is possible to close an anterior open bite with TSA, however they don't address the more pertinent question: Is it stable? Deguchi and

colleagues conducted a study that looked at 30 consecutively finished patients with an initial overbite less than -3 mm which led to 15 subjects in a TSA group. Another group treated with only premolar extractions was used as a control. They found that there was less stability seen in the TSA group compared to the extractions only group. 22% of the intrusion of the upper molars was lost and 13% of the overbite correction; however, the mean overbite at 2 years was positive⁴⁷. Baek et al wanted to evaluate the post-treatment changes at two different time points to assess when the relapse occurred. There were 9 subjects who had an average of 2.39 mm of intrusion and 5.6 mm of overbite increase. The upper molars relapsed 22.88% and the overbite 17%; however, Baek found that 80% of the relapse occurred within the first year of the 3 year follow-up⁴⁸.

After a current search of the literature, two studies were found to compare TSA treatment with orthognathic surgery. Kuroda et al assessed 23 patients, 10 TSA (both upper and lower molars were intruded) and 13 surgical patients (bimaxillary surgery)⁴⁹. They found there was a statistically shorter duration of treatment in the TSA group, but there was no difference found in overbite correction. The authors concluded that “orthodontic treatment with skeletal anchorage is similar and more useful than that with orthognathic surgery”. No follow-up data was provided for this study to see how correction held up versus the surgical group. The second study was conducted at UNC. Hull et al published a study that showed only maxillary intrusion with the use of TSA and stability at least 6 months post-treatment⁵⁰. He found that stability of the overbite correction was comparable to those patients undergoing orthognathic surgery. This study for its surgical patients looked at immediate pre- and post- surgical records to look at treatment effects, but it would have been

more beneficial to look at initial records to see how the patient initially presented for treatment.

The use of TSA in orthodontic treatment has become a great tool. This treatment modality has the potential to make treatment more efficient and just as effective as surgery. Studies looking at the long-term stability of the procedure and comparing to surgical outcomes are scarce and the two examples here have extremely small sample sizes. These show promising results, but more work must be done to evaluate the efficiency, effectiveness, and stability compared to the highly stable procedure of maxillary impaction. If TSA closure of an anterior open bite can be shown to be as stable as maxillary osteotomy, then patients can have a treatment alternative that would enable them to avoid the added costs and risks associated with a major surgery.

II INTRODUCTION

One of the most challenging malocclusions that orthodontists face is the anterior open bite. The National Health and Nutritional Estimates Survey (NHANES) III estimated the prevalence of anterior open bites to be 3.3% among 18-50 year olds and 3.5% among 12-17 year olds². Practitioners should be knowledgeable about techniques to treat this type of malocclusion as effectively and predictably as possible.

The etiology of the anterior open bite has been attributed to various factors including aberrant vertical growth, abnormal muscle function or growth (including the tongue), and digit-sucking habits^{1, 7, 8}. Often both skeletal as well as dental components contribute to an anterior open bite⁴. Both of these components create excessive vertical development of the maxillary posterior dentition. This excessive vertical growth manifests itself in a posteriorly tipped palatal plane with maxillary molars supra-erupted causing a downward and backward rotation of the mandible⁶. The lower face height is increased and mandibular plane is steepened leading to a long-faced appearance³. Frost and colleagues said that the vertical excess often occurs below the palatal plane and the mandibular plane was affected secondarily¹⁰. Subtelny et al evaluated 25 individuals over the age of 12 with persistent open bite and found greater eruption of the maxillary molars and incisors, but reported that the position and size of the maxilla did not significantly differ from a control group with normal overbite¹.

In order to normalize the clinical and radiographic findings of an anterior open bite, treatment should be aimed at superiorly repositioning the maxillary dentition or the posterior maxilla itself¹⁰. With orthodontics alone, closure of an open bite can occur one of two ways: elongation of the anterior teeth or intrusion of the posterior teeth²⁸. Since the stability of elongating the anterior teeth is questionable⁵¹, most treatments are directed towards intrusion of the posterior teeth.

In growing patients, relative intrusion occurs by impeding the vertical growth of the posterior maxilla and allowing other parts of the face to grow. This can be achieved with a high-pull headgear to an occlusal splint⁵² or an open bite bionator¹⁵. In non-growing patients absolute intrusion is necessary to close the open bite. This has been attempted with posterior bite blocks with or without magnets^{17, 53} and the Multiloop Edgewise Arch Wire (MEAW) technique⁵¹. Stability and effectiveness are questionable for all of these treatments. Additionally, these treatments elongate the maxillary incisors which may already be extruded¹. Janson et al and Remmers et al found success rates of 61.9% and 71% for patients at least 5 years after conventional orthodontic treatment^{22, 23}.

Since correction of an anterior open bite is difficult to accomplish by orthodontics alone, a combination of orthodontics and surgery has been used. A maxillary Le Fort I osteotomy with superior positioning of the posterior maxilla, is currently the surgical approach used to correct the excessive vertical development of the maxilla and dentoalveolar process. This can be accomplished with a single piece maxilla or as a multi-piece procedure if there is a step in the maxillary occlusal plane. According to Proffit et al, superiorly positioning the maxilla is highly stable with greater than 90% of patients exhibiting excellent results in the first year after surgery¹¹. Espeland et al found in her retrospective study of

surgical patients that the anterior open bite correction is relatively stable over a three year period and any skeletal relapse is compensated for by dentoalveolar changes³⁰.

As with any surgery under general anesthesia there are associated risks. The LeFort I procedure is a complex surgery associated with a long healing period as well as a financial burden. Consequently, a less invasive technique to correct an anterior open bite would be very desirable. With the aid of temporary skeletal anchorage (TSA), mini-screws or bone anchors, absolute intrusion of teeth is possible. Janssen noted that skeletal anchorage is a valuable option in cases requiring intrusion, particularly of maxillary molars⁵⁴. Bone plates placed in the zygomatic buttress⁴¹ or mini-screws⁵⁵ placed in the alveolus have been used as anchorage to intrude the maxillary posterior teeth. This technique has been shown to be effective in closing anterior open bites^{13, 40, 45, 46, 56}.

Long-term stability of this treatment modality, however, remains unclear. Sugawara found that after intrusion using his skeletal anchorage system (SAS), 27-30% relapse occurred within 1 year, but the open bite remained closed³⁹. Kuroda et al published a study comparing skeletal anchorage and orthognathic surgery patients and concluded that molar intrusion is easier and is as stable as surgery. Although they report that their results were stable 2 years post-treatment, they did not provide data to support this⁵⁷. Hull's retrospective study comparing the stability of a maxillary osteotomy and maxillary intrusion with TSA stated that after 6 months little relapse occurred and the open bites remained corrected with both groups⁵⁰. In 2011, Greenlee et al published a meta-analysis comparing the treatments for anterior open bites²⁶. He concluded that both surgical and non-surgical treatments were effective at increasing the overbite an average of 4 mm, but that both groups had a decrease in the overbite during the follow-up period. He concluded that the evidence suggested that

many patients with mild to moderate open bites can be successfully treated with less invasive and less costly nonsurgical orthodontics without notable compromises in long-term stability.

Data are still lacking regarding long-term stability of treatment of an anterior open bite with TSA. If this treatment modality is shown to be as stable as maxillary osteotomy, orthodontists will be able to propose an alternative treatment with less morbidity, lower cost, and shorter healing time for anterior open bite patients.

III MATERIALS AND METHODS

Sample selection

Patients diagnosed with an anterior open bite (defined by a cephalometric overbite measurement less than 0 mm) who were treated with either temporary skeletal anchorage (TSA) to intrude maxillary posterior teeth or a LeFort I maxillary osteotomy with rigid fixation with or without a genioplasty at the UNC Memorial Hospital in combination with orthodontic treatment from 2001 to 2008 were eligible for inclusion. Forty-three patients treated in a private practice in Boone, NC or the graduate orthodontic clinic at the University of North Carolina School of Dentistry who were treated with TSA were eligible as were fifty-seven patients who had orthognathic surgery and were treated orthodontically in the graduate clinic or in private practices. No restrictions were placed on the growth status of patients, type of TSA, or type of rigid fixation used. No patients were excluded on the basis of age, race, or ethnicity. Patients were excluded if the open bite was associated with pathologic problems, recognized syndromes, or acute trauma or if records were incomplete.

Cephalometric analysis

Lateral cephalometric radiographs were required at three different time points: Pre-treatment (T1), End of orthodontic treatment (T2), and Retention (T3). All lateral cephalometric radiographs were assumed to have an average magnification of 8% (UNC and the Boone private practice were taken at a standardized distance). Cephalograms were imported into Dolphin Imaging Software version 11.5 (Charsworth, CA). Digitization was

completed by one examiner (GM) using a 29-point model (Figure 1). The following skeletal and dental measurements were evaluated: anterior face height (AFH), posterior face height (PFH), mandibular plane angle (SN-GoGn), palatal plane to SN, overbite (OB), U6 to palatal plane, U1 to palatal plane, L1 to mandibular plane, and L6 to mandibular plane.

Effectiveness, as measured by cephalometric change in overbite, and efficiency, as measured by number of months in total treatment, were evaluated using time points T1 and T2. Stability, as measured by cephalometric change, was evaluated using time points T2 and T3.

Statistical analysis

The cephalometric measurements were recorded for each subject at the three different time points. Given the expected correlation within a subject, a linear mixed effects model was used to analyze each outcome separately. Unstructured covariance variances were used, and all parameters were estimated by REML method (SAS 9.2 Proc Mixed). The model included group (SG, TSA), age, sex, time (T1, T2, T3), and the pairwise interaction of group and time to assess whether the pattern of change over time was similar. The time in treatment was analyzed by Wilcoxon rank sum with treatment group as the explanatory factor. Reliability using intraclass correlation statistic (ICC) and systematic bias using a repeated measurement ANOVA were assessed using 10 randomly selected cephalograms, digitized three separate times with at least a week between tracings by the same examiner. Level of significance was set at 0.05 for all analyses.

This project was approved by the Biomedical Institutional Review Board of the University of North Carolina at Chapel Hill.

IV RESULTS

Ten of the 43 TSA patients and thirty-nine of the 57 surgery patients were excluded for lack of records. Twenty-six of the surgical patients excluded because of incomplete records were treated by private practitioners, however, eight of the TSA patients excluded were from the graduate clinic. The final samples included 33 TSA subjects (26 female, 7 male) and 18 surgery subjects (14 female, 4 male). The TSA group had a median age of 17 years (IQR 15-27; range 12-48 years) and the surgery group had a median age of 17.5 years (IQR 16-27; range 14-39 years).

Intraexaminer reliability was excellent (ICC range: 0.96-0.99) and no systematic bias occurred ($P>0.16$).

The treatment time was statistically significantly different for the two groups ($P=0.04$): overall, the treatment time in the TSA group was 28.6% shorter. The TSA group had a median of 2.0 years (IQR 1.4-2.6 years) and the surgery group had a median time of 2.8 years (IQR 2.1-3.5 years, $P=0.040$). The median follow-up length of time was 2.0 years (IQR 0.98-2.4 years) for the TSA patients and 1.6 years (IQR 1.2-2.7 years) for the surgery patients.

Descriptive statistics for all cephalometric measures by group are summarized in Table 2. For AFH, PFH, U1-PP, L6-GoGn, and L1-GoGn the interaction of time and group was not statistically significant ($P>0.32$) indicating that the pattern of change over time was

similar for both treatment groups (Table 3). An example of the similar trend observed for these measures for the two groups is illustrated in Figure 2. For these measures, there was no statistically significant difference in the average values for the two treatment groups ($P>0.32$) controlling for age and sex. Except for PFH, treatment change was statistically significant for AFH, U1-PP, L6-GoGn, and L1-GoGn ($P<0.012$), while the post-treatment change was statistically significant ($P=0.019$) for AFH only. Both the Surgery and TSA groups had a decrease in AFH with treatment (Table 2). The U1s extruded during treatment and there was further eruption or vertical growth, although not statistically significant ($P=0.24$), in the retention period. The L6s exhibited extrusion from T1 to T2 in both groups. In the retention period the L6s intruded slightly for both groups; however this was not statistically significant ($P=0.15$). Both groups had statistically significant mean extrusion of the L1 with no significant changes in the retention period ($P=0.48$).

MPA, PP-SN, OB, and U6-PP measures exhibited patterns of change over time that were statistically different for the two treatment groups ($P<0.015$) (Figures 3-6; Table 4). There was a statistically significant change in the MPA during treatment for the surgery group with a reduction of 2.1° (SD 2.9° ; $P<0.001$) whereas the TSA subjects had very little mean MPA change with treatment ($P=0.68$). Some of this closure of the MPA was lost during the retention phase, 0.58° (SD 1.6°), a 28% decrease; however neither the surgery group nor the TSA group had significant retention changes ($P>0.12$). PP-SN increased on average 2.4° (SD 2.3° ; $P<0.001$) for the surgery subjects while the TSA group again had no significant change ($P=0.66$). Twenty percent, on average, of the rotation of the palatal plane was lost during the retention on the surgery group but this was not significant ($P=0.087$).

The TSA patients did have a significant change in the retention period with a small decrease in the angle ($P=0.047$).

In the TSA group there was an initial OB of -2.0 mm (SD 1.4 mm) and the surgery group of -3.8 mm (SD 2.7 mm), which was statistically significantly different ($P=0.002$). The change during treatment was statistically significant on both groups ($P<0.001$). By T2 both groups had mean positive OB: TSA an average OB of 1.4 mm (SD 0.85 mm) and surgery an OB of 1.2 mm (SD 0.89 mm), with no significant differences between the groups ($P=0.48$). Each group had two subjects who did not reach positive OB at the end of treatment. There was a 9.4% reduction in average OB correction during the retention period for the TSA subjects and the surgery patients had a 15% reduction which was statistically significant between the T2 and T3 ($P<0.025$). At T3, the TSA group had a mean OB of 0.98 mm (SD 1.2, range -2.3-3.0 mm) and the surgery group 0.4 mm (SD 1.4, range -2.0-2.3 mm) but the average values at T3 for the two groups were not statistically ($P=0.12$). There were 4 TSA patients and 5 surgery patients who had negative OB at the follow-up time point. Figures 7 and 8 show the OB data at the 3 time points plotted for each of the subjects in the two groups.

The TSA group had 2.1 mm (SD 1.5 mm; $P<0.001$) of intrusion of the U6 relative to the palatal plane at the completion of treatment, which was statistically significant ($P=0.015$) compared to the surgery group. The surgery group had very little change in U6 position over the three time points ($P>0.26$). Through the retention period, 36% of the intrusion gained with TSA treatment was lost ($P<0.001$).

V DISCUSSION

Time in treatment was found to be significantly shorter, on average, in the TSA group by 9 months. This is an important finding when considering potential side-effects of fixed appliances such as decalcifications, white spot lesions, and root resorption. Shorter treatment times are beneficial to the patient and the orthodontist.

The results of this study show that an anterior open bite can be effectively closed and remains stable with both surgery and TSA treatments. The surgery group closed on average 5.0 mm while the TSA group 3.3 mm, which is similar to what Greenlee et al found in his meta-analysis: OB correction was 4.2 mm for surgery and 4.0 mm for non-surgical treatment²⁶. While both groups had a positive mean OB at the follow-up period, the surgery patients started with a larger initial open bite. This could help explain why more relapse was found for the surgery group even though the final OB from treatment was similar. Both groups had patients fail to reach positive OB with treatment (2 TSA subjects and 2 surgery subjects) and relapse in the retention period to an open bite (4 TSA subjects and 5 surgery patients). Overall, the success rates (defined as $OB > 0$) were 72% for surgery and 88% for TSA, which was in line with Greenlee's overall success rate of 75% for both surgical and non-surgical therapies²⁶.

The measurements that showed statistically significant differences in the pattern of change over time were MPA, PP-SN, OB, and U6-PP. The significant changes of PP-SN and

U6-PP between groups are easily explained. For PP-SN, the surgical movement usually is to impact the posterior maxilla, thereby rotating the maxillary complex and changing the angle to SN, whereas the TSA group would not have such a change. U6-PP is another direct effect of treatment. The TSA treatment is aimed at intruding the U6 and the U6 of the surgery patient is surgically repositioned with the palatal plane. Thus, it was expected to see differences in the vertical positions of the U6s to the palatal plane between the two groups. The difference in the pattern of change over time for the two groups with respect to OB was due to the differential in initial OBs. However, at the end of treatment and in the retention period the average OB of the two groups was not significantly different.

The changes seen in MPA are harder to explain. In this study, there was a 2.1° closure of the MPA, on average, in the surgical patients while there was no change in the TSA group. Teittinen et al showed that with maxillary osteotomy surgery there was a 4° decrease in the MPA³³. Kuroda et al found that with their techniques there was a 3.3° closure of the mandibular plane with TSA, while his surgical comparison group (mandibular osteotomy) had little change in the angle⁵⁷. Kuroda used TSA in the maxilla as well as the mandible, which may have allowed more mandibular autorotation by controlling the vertical elongation of the mandibular posterior teeth⁵⁷. The elongation of the L6 by an average of 1.8 mm, which was also seen in the surgical group, may have decreased the amount of autorotation obtained by the TSA patients. Therefore, it may be a beneficial to place TSA in the mandible or use an appliance to help control the lower molars while intruding the maxillary posterior dentition to allow for autorotation of the mandible.

In this study, maxillary first molars intruded by 2.1 mm, on average, in the TSA group which was in-line with other studies examining the intrusion of the maxillary posterior

dentition with TSA. Xun et al reported 1.8 mm of maxillary molar intrusion and Erverdi et al showed 3.6 mm of molar intrusion with TSA treatment, but no follow-up values were reported^{41, 46}. Deguchi et al saw 2.3 mm and Baek et al found 2.39 mm of maxillary molar intrusion and both reported 22% relapse in the vertical position of the molar in the follow-up period^{47, 48}. The present study indicated a 37% relapse of the U6 relative to the palatal plane. Baek also examined when most of this relapse occurs and concluded that 80% of the relapse occurs in the first year after appliance removal⁴⁸.

The surgery group achieved its OB correction by a rotation of the palatal plane, impacting the posterior portion of the maxilla, and allowing the mandible to autorotate closed. In addition to this, the U1s were extruded about 1 mm and the L1s by just over 2 mm on average. The TSA group did not experience the autorotation the surgery group did, nor did they have as much extrusion of the upper and lower incisors. However, there was enough of a decrease in the mandibular plane angle and enough extrusion of the incisors to allow for the OB to be corrected in the TSA group. For both surgery and TSA groups this incisor extrusion was stable, with little vertical change in the follow-up period. Also, there was a similar pattern of change over time with respect to anterior face height. Both the surgery and TSA group had reductions in the AFH, at around 1 mm but in the follow-up period it increased about 0.5 mm.

The only measurement that did not have any statistically significant change over time after controlling for age, sex and group was PFH. This is not surprising as nothing was done to increase the distance from Condylion to Gonion. We would not expect to see any change in this measurement, except for normal growth of the patient.

This study has the largest sample size comparing TSA and surgery groups to date. However, the samples were not equivalent in size. This was predominately due to many of the private practitioners not routinely taking final cephalometric radiographs. The Dentofacial Disharmony Program at UNC receives referrals from outside orthodontists for orthognathic surgery. The Program typically relies on initial and final records, being sent in from private practitioners. 26 of 39 surgical patients were excluded from the study due to lack of final records from the treating orthodontist. This is a limitation of the study and the potential for bias with respect to the decision to take or not take final records cannot be assessed. Another was that the surgery group started with a larger open bite than the TSA group. This could introduce bias in the stability since there was a greater correction in overbite for the surgery patients. Also, there were many different practitioners providing treatment for patients in the two groups with no strict protocol for surgical set-up nor intrusion with skeletal anchorage. Although a randomized clinical trial would be the optimal design to compare these treatment alternatives, the substantial differentiation in the cost to the patient makes such a study unlikely. However, future comparison studies should be conducted with a stricter treatment protocol within each treatment modality.

VI CONCLUSIONS

1. TSA had a shorter treatment time than the surgery group.
2. TSA can be used to sufficiently intrude the Maxillary posterior dentition to correct mild to moderate open bites ($0 > OB > -5\text{mm}$) and is an effective treatment alternative to surgery for these patients.
3. OB reduction occurs in the follow-up period, therefore over-correction should be built into treatment to allow for mild relapse for both surgery and TSA treated patients.

VII. TABLES

Table 1. Summary of the time points for each treatment group

Treatment Time Points	
T1	Initial Records
T2	Removal of fixed appliances
T3	Retention Records

Table 2. Mean Skeletal and Dental Measurements

Mean Skeletal Measurements					
	T1 (SD)	T2 (SD)	T2-T1 (SD)	T3 (SD)	T3-T2 (SD)
Anterior Face Height (mm) (Nasion-Menton)					
<i>TSA</i>	78.0(7.6)	77.2(6.5)	-0.81(2.6)	77.8(6.6)	0.54(1.2)
<i>Surgery</i>	78.5(7.5)	77.1(7.6)	-1.4(3.2)	77.6(8.3)	0.58(2.2)
Posterior Face Height (mm) (Condylion-Gonion)					
<i>TSA</i>	59.3(7.0)	60.0(6.4)	0.65(4.1)	59.7(6.3)	-0.26(2.7)
<i>Surgery</i>	60.0(6.5)	60.9(7.3)	0.93(2.8)	60.3(7.5)	-0.62(2.6)
Mandibular Plane Angle (°) (SN-GoGn)					
<i>TSA</i>	39.6(5.0)	39.5(5.2)	-0.16(1.7)	39.5(5.2)	0.01(1.6)
<i>Surgery</i>	39.4(6.7)	37.3(6.3)	-2.1(2.9)	37.9(6.4)	0.58(1.6)
Palatal Plane to SN (°)					
<i>TSA</i>	-0.24(3.6)	-0.11(3.6)	0.13(1.3)	-0.51(3.5)	-0.38(0.92)
<i>Surgery</i>	-0.49(2.3)	1.9(4.5)	2.4(2.3)	1.5(4.6)	-0.47(0.99)
Mean Dental Measurements					
Overbite (mm)					
<i>TSA</i>	-2.0(1.4)	1.4(0.85)	3.3(1.5)	0.98(1.2)	-0.31(0.82)
<i>Surgery</i>	-3.8(2.7)	1.2(0.89)	5.0(2.5)	0.40(1.4)	-0.76(0.98)
U1 to ANS-PNS (mm)					
<i>TSA</i>	32.5(3.7)	33.4(3.1)	0.92(1.6)	33.7(3.3)	0.25(0.92)
<i>Surgery</i>	31.5(4.1)	32.6(4.2)	1.1(1.4)	32.6(4.3)	0.03(1.2)
U6 to ANS-PNS (mm)					
<i>TSA</i>	27.0(3.3)	25.0(3.0)	-2.1(1.5)	25.7(2.9)	0.77(0.67)
<i>Surgery</i>	26.8(2.7)	26.7(2.8)	-0.10(2.2)	27.0(3.1)	0.23(1.2)
L1 to Go-Gn (mm)					
<i>TSA</i>	43.4(4.1)	44.9(3.6)	1.6(1.4)	44.9(3.5)	0.01(0.93)
<i>Surgery</i>	42.3(4.4)	44.4(4.1)	2.1(2.0)	44.1(4.3)	-0.28(0.88)
L6 to Go-Gn (mm)					
<i>TSA</i>	32.4(3.9)	34.2(3.4)	1.8(2.0)	34.0(3.6)	-0.22(1.4)
<i>Surgery</i>	32.7(3.6)	34.3(4.1)	1.7(1.7)	34.0(4.4)	-0.34(1.1)

Table 2: Mean skeletal and dental measurements from digitized cephalograms from each time point: T1 – Pretreatment, T2 – Post-treatment, T2-T1 – Treatment changes, T3 – Follow-up, T3-T2 – Post-treatment changes.

Table 3. P values Associated with the Variance Component General Linear Model

	Age		Sex		Time Point		Group		Time Point*Group	
	F Value	P	F Value	P	F Value	P	F Value	P	F Value	P
Anterior Face Height	0.92	0.34	8.24	0.006	5.44	0.008	0.00	0.97	0.28	0.76
Posterior Face Height	1.22	0.28	18.8	<0.001	1.80	0.18	0.21	0.65	0.15	0.86
MPA	0.00	0.99	3.24	0.078	6.18	0.0041	0.68	0.41	4.62	0.015
Palatal Plane to SN	0.04	0.84	1.78	0.19	15.3	<0.001	1.32	0.26	10.3	<0.001
Overbite	3.00	0.09	0.83	0.37	115.4	<0.001	7.66	0.008	4.81	0.013
U6-Palatal Plane	5.78	0.02	16.9	<0.001	14.0	<0.001	2.14	0.15	8.2	<0.001
U1-Palatal Plane	2.15	0.15	6.26	0.02	11.9	<0.001	0.83	0.37	0.29	0.75
L1-GoGn	0.11	0.74	8.71	0.005	29.7	<0.001	0.56	0.46	1.16	0.32
L6-GoGn	0.74	0.39	9.64	0.003	20.25	<0.001	0.01	0.91	0.13	0.88
Degrees of Freedom for Age (1), Sex (1), Time Point (2), Group (1), and Time Point*Group (2)										

VIII. FIGURES

Figure 1. Representative Cephalometric Tracing

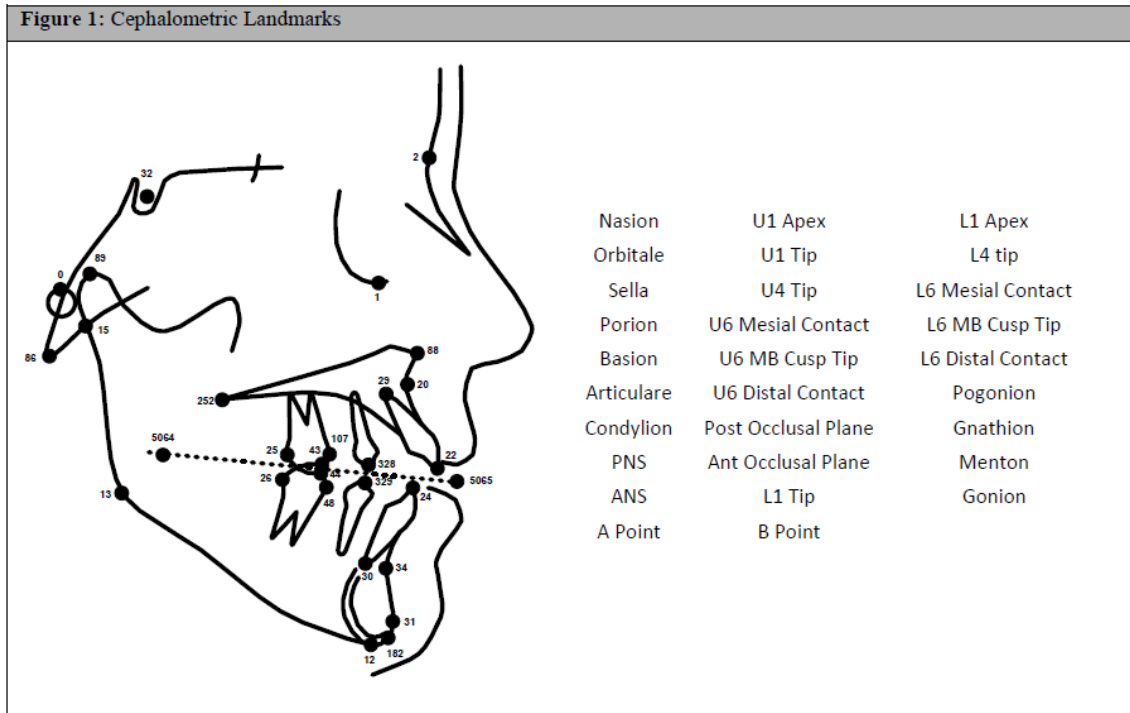


Figure 2. Pattern of Change for U1-PP Over Time

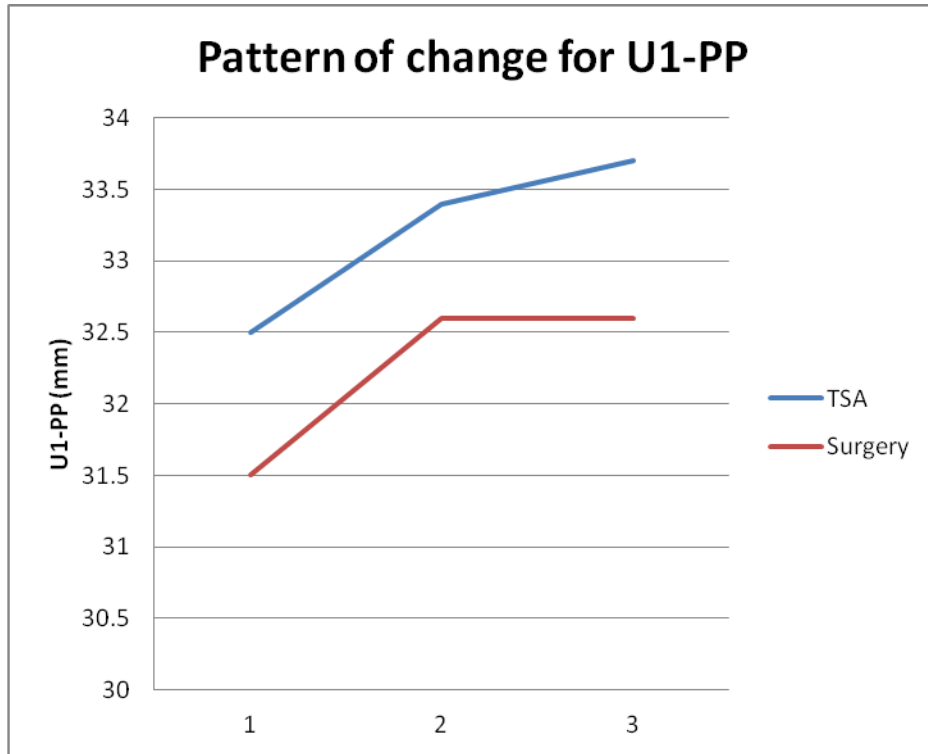


Figure 2: Mean U1-PP plotted per time point. No statistically significant pattern of change over time ($P=0.75$).

Figure 3. Pattern of Change of MPA Over Time

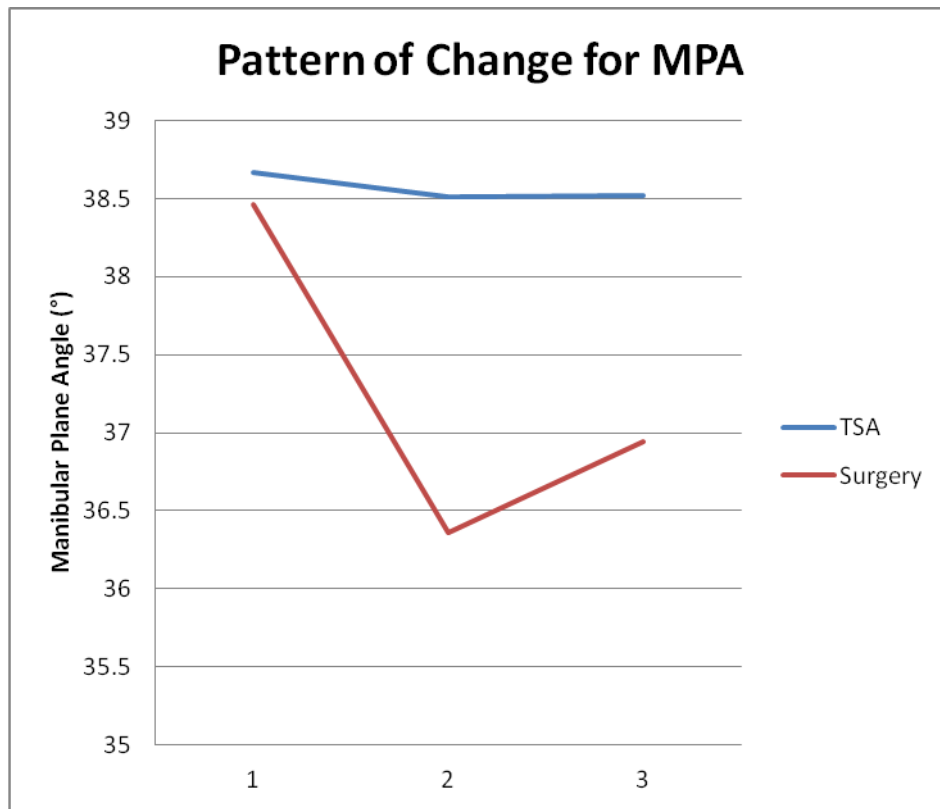


Figure 3: Estimated value of MPA when controlling for sex and age plotted per time point. There was a statistically significant change in the groups over time ($P=0.015$).

Figure 4. Pattern of Change for U6-PP Over Time

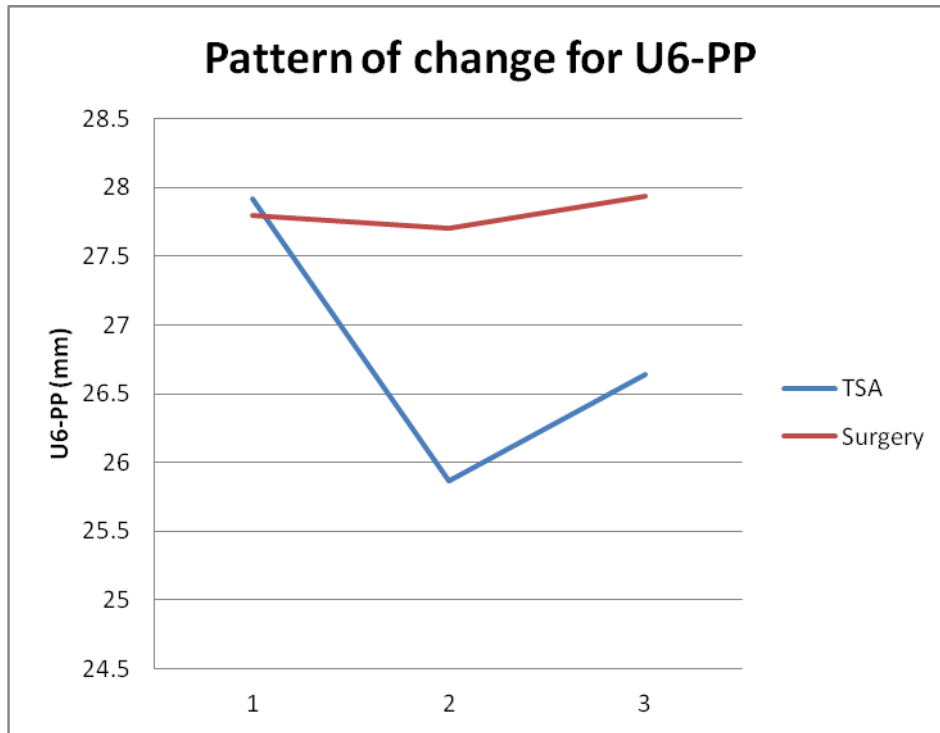


Figure 4: Estimated value of U6-PP when controlling for sex and age plotted per time point. There was a statistically significant change in the groups over time ($P<0.001$).

Figure 5. Pattern of Change for OB Over Time

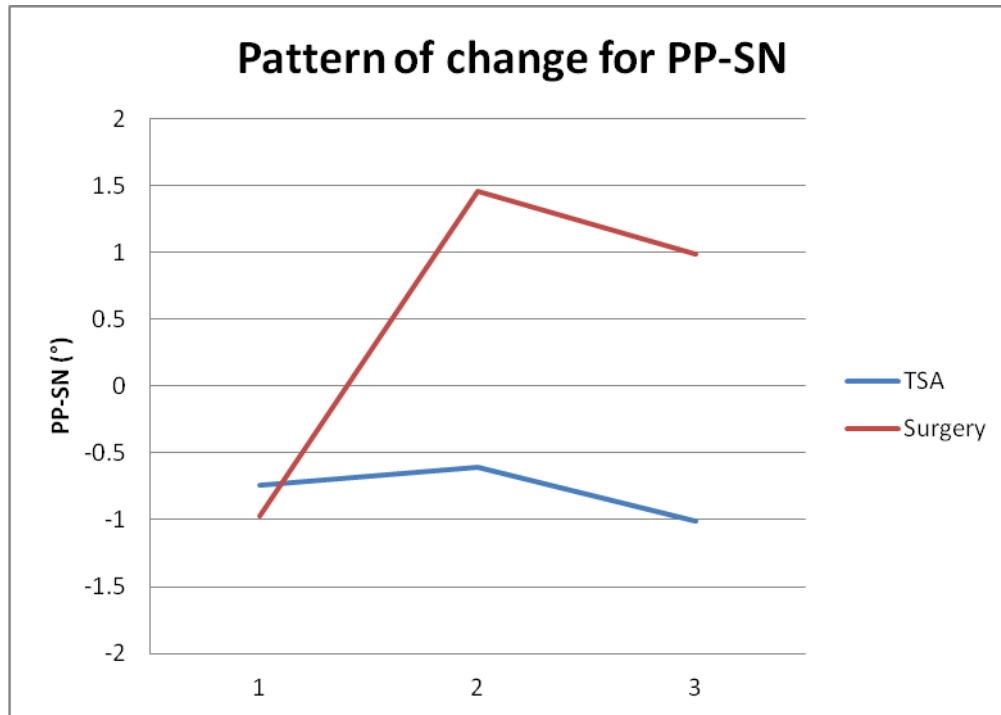


Figure 5: Estimated value of PP-SN when controlling for sex and age plotted per time point. There was a statistically significant pattern of change in the groups over time ($P < 0.001$).

Figure 6. Pattern of Change for OB Over Time

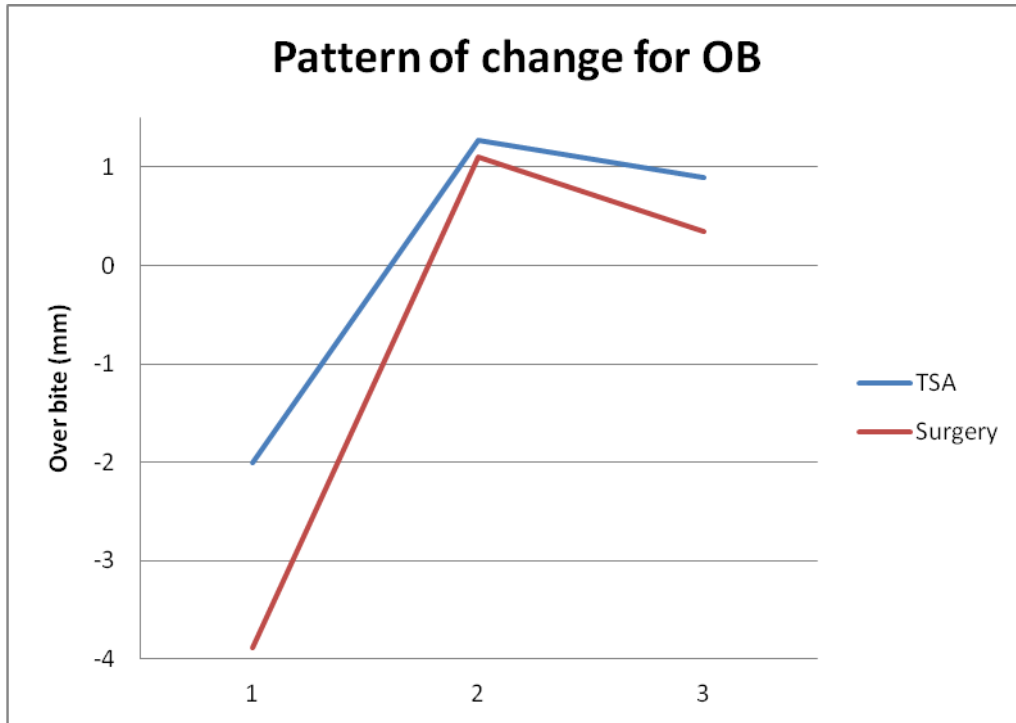


Figure 6: Estimated value of OB when controlling for sex and age plotted per time point. There was a statistically significant pattern of change in the groups over time ($P=0.013$).

Figure 7. OB Charted for All Surgery Patient at the 3 Time Points

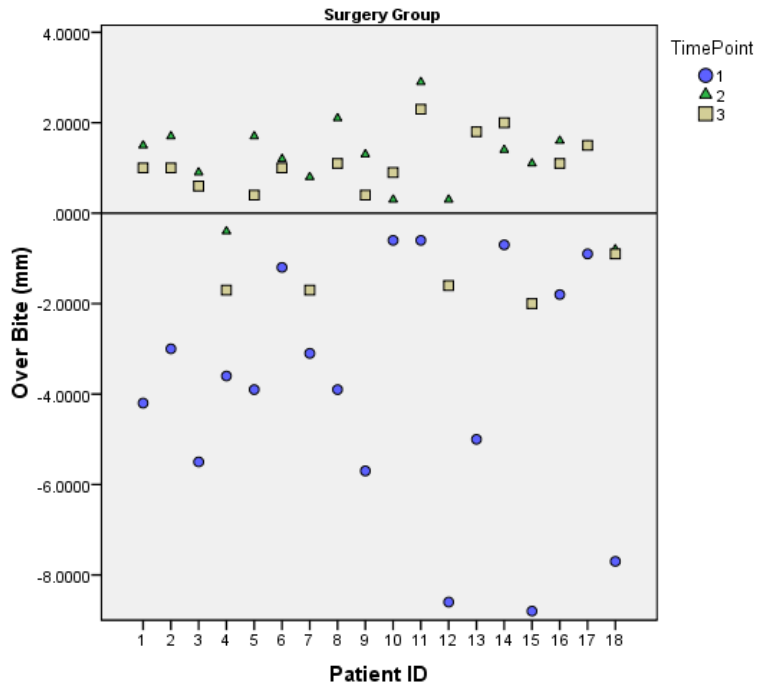


Figure 7: OB charted for all surgery patients at the 3 time points

Figure 8. OB Charted for All TSA Patients at the 3 Time Points

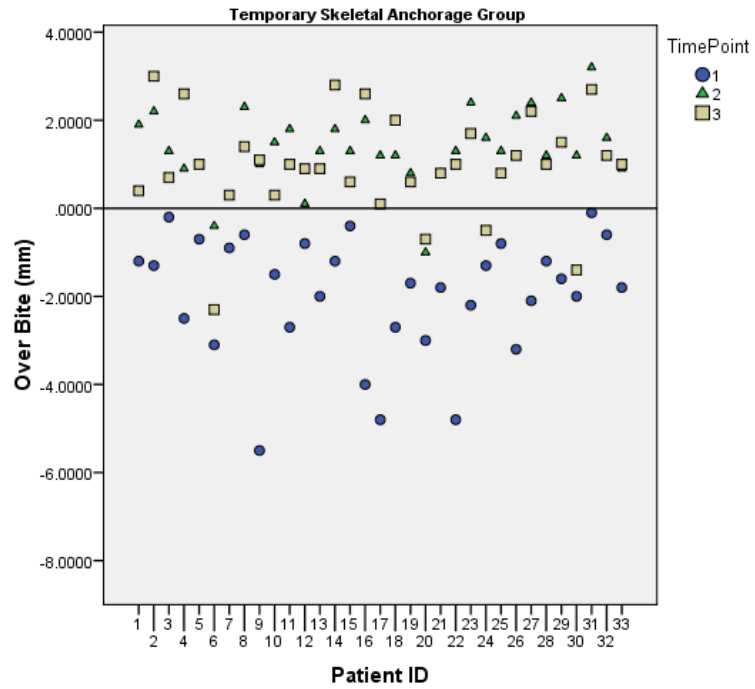


Figure 8: OB charted for all TSA patients at the 3 time points

References

1. Subtelny JD, Sakuda M. Open-bite: Diagnosis and treatment. *Am J Orthod.* 1964;50:337-358.
2. Proffit WR, Fields HW, Jr, Moray LJ. Prevalence of malocclusion and orthodontic treatment need in the United States: estimates from the NHANES III survey. *Int J Adult Orthodon Orthognath Surg.* 1998;13:97-106.
3. Beane RA, Jr. Nonsurgical management of the anterior open bite: a review of the options. *Semin Orthod.* 1999;5:275-283.
4. Sherwood K. Correction of skeletal open bite with implant anchored molar/bicuspid intrusion. *Oral Maxillofac Surg Clin North Am.* 2007;19:339-50, vi.
5. Reyneke JP, Ferretti C. Anterior open bite correction by Le Fort I or bilateral sagittal split osteotomy. *Oral Maxillofac Surg Clin North Am.* 2007;19:321-38, v.
6. Sassouni V. A classification of skeletal facial types. *Am J Orthod.* 1969;55:109-123.
7. Nielsen IL. Vertical malocclusions: etiology, development, diagnosis and some aspects of treatment. *Angle Orthod.* 1991;61:247-260.
8. Isaacson JR, Isaacson RJ, Speidel TM, Worms FW. Extreme variation in vertical facial growth and associated variation in skeletal and dental relations. *Angle Orthod.* 1971;41:219-229.
9. Schudy FF. The Rotation of the Mandible Resulting from Growth: its Implications in Orthodontic Treatment. *Angle Orthod.* 1965;35:36-50.
10. Frost DE, Fonseca RJ, Turvey TA, Hall DJ. Cephalometric diagnosis and surgical-orthodontic correction of apertognathia. *Am J Orthod.* 1980;78:657-669.
11. Proffit WR, Turvey TA, Phillips C. The hierarchy of stability and predictability in orthognathic surgery with rigid fixation: an update and extension. *Head Face Med.* 2007;3:21.
12. Proffit WR, Fields HW. *Contemporary Orthodontics.* Saint Louis: Mosby; 2000.
13. Leung MT, Lee TC, Rabie AB, Wong RW. Use of miniscrews and miniplates in orthodontics. *J Oral Maxillofac Surg.* 2008;66:1461-1466.
14. Caldwell SF, Hymas TA, Timm TA. Maxillary traction splint: a cephalometric evaluation. *Am J Orthod.* 1984;85:376-384.
15. Defraia E, Marinelli A, Baroni G, Franchi L, Baccetti T. Early orthodontic treatment of skeletal open-bite malocclusion with the open-bite bionator: a cephalometric study. *Am J Orthod Dentofacial Orthop.* 2007;132:595-598.

16. Pearson LE. Vertical control in fully-banded orthodontic treatment. *Angle Orthod.* 1986;56:205-224.
17. Iscan HN, Sarisoy L. Comparison of the effects of passive posterior bite-blocks with different construction bites on the craniofacial and dentoalveolar structures . *American Journal of Orthodontics and Dentofacial Orthopedics.* 1997;112:171-178.
18. Dellinger EL. A clinical assessment of the Active Vertical Corrector--a nonsurgical alternative for skeletal open bite treatment. *Am J Orthod.* 1986;89:428-436.
19. Kim YH. Anterior openbite and its treatment with multiloop edgewise archwire. *Angle Orthod.* 1987;57:290-321.
20. Endo T, Kojima K, Kobayashi Y, Shimooka S. Cephalometric evaluation of anterior open-bite nonextraction treatment, using multiloop edgewise archwire therapy. *Odontology.* Springer Japan; 2006;94:51-58.
21. Lopez-Gavito G, Wallen TR, Little RM, Joondeph DR. Anterior open-bite malocclusion: a longitudinal 10-year postretention evaluation of orthodontically treated patients. *Am J Orthod.* 1985;87:175-186.
22. Janson G, Valarelli FP, Henriques JF, de Freitas MR, Cancado RH. Stability of anterior open bite nonextraction treatment in the permanent dentition. *Am J Orthod Dentofacial Orthop.* 2003;124:265-76; quiz 340.
23. Remmers D, Van't Hullenaar RW, Bronkhorst EM, Berge SJ, Katsaros C. Treatment results and long-term stability of anterior open bite malocclusion. *Orthod Craniofac Res.* 2008;11:32-42.
24. de Freitas MR, Beltrao RT, Janson G, Henriques JF, Cancado RH. Long-term stability of anterior open bite extraction treatment in the permanent dentition. *Am J Orthod Dentofacial Orthop.* 2004;125:78-87.
25. Zuroff JP, Chen SH, Shapiro PA, Little RM, Joondeph DR, Huang GJ. Orthodontic treatment of anterior open-bite malocclusion: stability 10 years postretention. *Am J Orthod Dentofacial Orthop.* 2010;137:302.e1-8; discussion 302-3.
26. Greenlee GM. Stability of treatment for anterior open-bite malocclusion: a meta-analysis. *American journal of orthodontics and dentofacial orthopedics.* 2011;139:154-69.
27. Obwegeser HL. Surgical correction of small or retrodisplaced maxillae. The "dish-face" deformity. *Plast Reconstr Surg.* 1969;43:351-365.
28. Proffit WR, Bailey LJ, Phillips C, Turvey TA. Long-term stability of surgical open-bite correction by Le Fort I osteotomy. *Angle Orthod.* 2000;70:112-117.

29. Hoppenreijs TJM, Freihofer HPM, Stoelinga PJW, et al. Skeletal and dento-alveolar stability of Le Fort I intrusion osteotomies and bimaxillary osteotomies in anterior open bite deformities: A retrospective three-centre study. *Int J Oral Maxillofac Surg.* 1997;26:161-175.
30. Espeland L, Dowling PA, Mobarak KA, Stenvik A. Three-year stability of open-bite correction by 1-piece maxillary osteotomy. *Am J Orthod Dentofacial Orthop.* 2008;134:60-66.
31. Stansbury CD, Evans CA, Miloro M, BeGole EA, Morris DE. Stability of open bite correction with sagittal split osteotomy and closing rotation of the mandible. *J Oral Maxillofac Surg.* 2010;68:149-159.
32. Maia FA, Janson G, Barros SE, Maia NG, Chiqueto K, Nakamura AY. Long-term stability of surgical-orthodontic open-bite correction. *Am J Orthod Dentofacial Orthop.* 2010;138:254.e1-254.e10; discussion 254-6.
33. Teittinen M, Tuovinen V, Tammela L, Schatzle M, Peltomaki T. Long-term stability of anterior open bite closure corrected by surgical-orthodontic treatment. *Eur J Orthod.* 2011.
34. Wriedt S, Buhl V, Al-Nawas B, Wehrbein H. Combined treatment of open bite - long-term evaluation and relapse factors. *J Orofac Orthop.* 2009;70:318-326.
35. Gainsforth BL, Higley LB. Study of orthodontic anchorage possibilities in basal bone. *Am J of Orthod and Oral Surg.* 1945;31.
36. Creekmore TD, Eklund MK. The possibility of skeletal anchorage. *J Clin Orthod.* 1983;17:266-269.
37. Melsen B, Petersen JK, Costa A. Zygoma ligatures: an alternative form of maxillary anchorage. *J Clin Orthod.* 1998;32:154-158.
38. Umemori M, Sugawara J, Mitani H, Nagasaka H, Kawamura H. Skeletal anchorage system for open-bite correction. *Am J Orthod Dentofacial Orthop.* 1999;115:166-174.
39. Sugawara J, Baik UB, Umemori M, et al. Treatment and posttreatment dentoalveolar changes following intrusion of mandibular molars with application of a skeletal anchorage system (SAS) for open bite correction. *Int J Adult Orthodon Orthognath Surg.* 2002;17:243-253.
40. Park YC, Lee HA, Choi NC, Kim DH. Open bite correction by intrusion of posterior teeth with miniscrews. *Angle Orthod.* 2008;78:699-710.
41. Erverdi N, Usumez S, Solak A, Koldas T. Noncompliance open-bite treatment with zygomatic anchorage. *Angle Orthod.* 2007;77:986-990.
42. Park HS, Kwon OW, Sung JH. Nonextraction treatment of an open bite with microscrew implant anchorage. *Am J Orthod Dentofacial Orthop.* 2006;130:391-402.

43. DeVincenzo JP. A new non-surgical approach for treatment of extreme dolichocephalic malocclusions. Part 1. Appliance design and mechanotherapy. *J Clin Orthod.* 2006;40:161-170.
44. DeVincenzo JP. A new non-surgical approach for treatment of extreme dolichocephalic malocclusions. Part 2. Case selection and management. *J Clin Orthod.* 2006;40:250-260.
45. Seres L, Kocsis A. Closure of severe skeletal anterior open bite with zygomatic anchorage. *J Craniofac Surg.* 2009;20:478-482.
46. Xun C, Zeng X, Wang X. Microscrew anchorage in skeletal anterior open-bite treatment. *Angle Orthod.* 2007;77:47-56.
47. Deguchi T, Kurosaka H, Oikawa H, et al. Comparison of orthodontic treatment outcomes in adults with skeletal open bite between conventional edgewise treatment and implant-anchored orthodontics. *American Journal of Orthodontics and Dentofacial Orthopedics.* 2011;139:S60-S68.
48. Baek M, Choi Y, Yu H, Lee K, Kwak J, Park Y. Long-term stability of anterior open-bite treatment by intrusion of maxillary posterior teeth. *American Journal of Orthodontics and Dentofacial Orthopedics.* 2010;138:396.e1-396.e9.
49. Kuroda S, Katayama A, Takano-Yamamoto T. Severe anterior open-bite case treated using titanium screw anchorage. *Angle Orthod.* 2004;74:558-567.
50. Hull T. Effectiveness and Stability of Open Bite Correction Using Temporary Skeletal Anchorage: Comparison to Surgical Outcomes. *SAO News.* 2010:16-20.
51. Kim YH, Han UK, Lim DD, Serrano MLP. Stability of anterior openbite correction with multiloop edgewise archwire therapy: A cephalometric follow-up study. *American Journal of Orthodontics and Dentofacial Orthopedics.* 2000;118:43-54.
52. Closs L, Kulbersh VP. Combination of Bionator and high-pull headgear therapy in a skeletal open bite case. *American Journal of Orthodontics and Dentofacial Orthopedics.* 1996;109:341-347.
53. Noar JH, Shell N, Hunt NP. The performance of bonded magnets used in the treatment of anterior open bite. *American Journal of Orthodontics and Dentofacial Orthopedics.* 1996;109:549-556.
54. Janssen KI, Raghoobar GM, Vissink A, Sandham A. Skeletal anchorage in orthodontics--a review of various systems in animal and human studies. *Int J Oral Maxillofac Implants.* 2008;23:75-88.
55. Kravitz ND, Kusnoto B, Tsay TP, Hohlt WF. The use of temporary anchorage devices for molar intrusion. *J Am Dent Assoc.* 2007;138:56-64.
56. Erverdi N, Usumez S, Solak A. New generation open-bite treatment with zygomatic anchorage. *Angle Orthod.* 2006;76:519-526.

57. Kuroda S, Sakai Y, Tamamura N, Deguchi T, Takano-Yamamoto T. Treatment of severe anterior open bite with skeletal anchorage in adults: comparison with orthognathic surgery outcomes. *Am J Orthod Dentofacial Orthop.* 2007;132:599-605.