

**IN VIVO ASSESSMENT OF OSSEOUS WOUND HEALING USING BONE
PUTTY IN THE SURGICAL MANAGEMENT OF TOOTH EXTRACTIONS**

AKSHAY ASWATHA KUMARSWAMY

A thesis submitted to the faculty of the University of North Carolina at
Chapel Hill in partial fulfillment of the requirements for the degree of Master of Science
in the
Department of Periodontology

Chapel Hill

2011

Approved by:

Salvador Nares D.D.S, PhD

Antonio Moretti D.D.S, M.S

Eric Everett M.S, PhD

Ricardo Padilla D.D.S

© 2011

Akshay Aswatha Kumarswamy

ALL RIGHTS RESERVED

ACKNOWLEDGEMENTS

This dissertation would not have been possible without the guidance and the help of several individuals who in one way or another contributed and extended their valuable assistance in the preparation and completion of this study.

First and foremost, my utmost gratitude to my mentor Dr. Salvador Nares and committee members Drs. Antonio Moretti, Eric Everett and Ricardo Padilla whose encouragement and dedication has been my inspiration in the completion of this project.

Special thanks are in order to Dr. David Paquette for the insights he shared.

Ms. Anissa Anderson and the entire staff of the Division of Laboratory Animal Medicine at the University of North Carolina at Chapel Hill for their help with the animals in this study.

Ms. Sandra Horton at the North Carolina State Veterinary College for her help with the Histology part of this project

Mr. Brandon Frederick at the Biomedical Imaging Research Center for bearing with my innumerable requests in regards to the μ CT analysis

Thanks to Drs. Roger Arce and Jonathan Reside for their help with the statistics and formatting, respectively.

My parents Dr. Kumarswamy, Sharada and my sister Ashvini for encouraging me in my chosen path. Also my fiancée Aparna for bearing my innumerable grumblings over the past 2 years.

Last but not the least; I would like to thank Almighty God for giving me the courage and strength to handle the stress and shortcomings. I pray to him that he bless the souls of the animals used in this study and may they rest in peace.

ABSTRACT

AKSHAY ASWATHA KUMARSWAMY: In Vivo Assessment of Osseous Wound Healing using Bone Putty in the Surgical Management of Tooth Extractions.

Purpose: The objective of this pilot study was to evaluate the healing responses of a anesthetic bone putty in tooth extraction sockets of a canine model.

Materials and Methods: In five beagle dogs the right mandibular premolars were extracted. The extraction sockets were grafted with one of the four treatment arms: 1) bone putty alone, 2) bone putty mixed with xenograft particulate bone (3:1), 3) xenograft sandwiched between bone putty and 4) xenograft covered with a collagen sponge. After 6 weeks, the healing extraction sockets were evaluated by microCT and histological analysis.

Results: All sockets healed without complications. By microCT analysis, sockets grafted demonstrated comparable radiographic evidence of bone healing compared to control sockets. Histologically, a minimal inflammatory infiltrate was present in all the sockets.

Conclusions: Our pre-clinical results indicate that this bone putty is a safe, biocompatible device that may be useful in the post-operative management of tooth extractions.

TABLE OF CONTENTS

LIST OF TABLES	vii
LIST OF FIGURES AND GRAPHS	viii
LIST OF ABBREVIATIONS AND SYMBOLS	ix
I. INTRODUCTION	1
II. BIOLOGY OF THE HEALING EXTRACTION SOCKET.....	3
III. RATIONALE FOR SITE PRESERVATION	5
IV. AUTOGENOUS GRAFTS	8
V. ALLOGRAFTS.....	10
VI. XENOGRAFTS	12
VII. SYNTHETIC BONE SUBSTITUTES	14
Calcium Phosphate and Derivatives.....	15
Bio-Glass	17
Calcium Sulfate	18
VIII. OSTEOACTIVE AGENTS	19
IX. BARRIER MEMBRANES.....	21
X. SUMMARY	23
XI. INTRODUCTION TO CLINICAL STUDY	24
XII. MATERIALS AND METHODS.....	26
Surgical Procedure	26

Post-Operative Care and Euthanasia	27
Blood Chemistry Panel.....	27
Radiographic Analysis	27
Histological Analysis	28
Statistical Analysis	29
XIII. RESULTS	30
Handling Characteristics	30
Safety Assessment.....	30
Radiological Assessment.....	31
Histological Assessment	31
XIV. DISCUSSION	33
XV. CONCLUSIONS.....	36
FIGURES AND TABLES	37
REFERENCES	53

LIST OF TABLES

Table

1.	Blood chemistry tests of two representative animals (before surgery).....	37
2.	Blood chemistry tests of two representative animals (after surgery).....	38
3.	Density measurements of the materials (mg/mm ³).....	39
4.	Summary statistics for Ratio of Bone Volume to Total Volume ($p \leq 0.05$).....	40
5.	Summary statistics for Bone Density Measurements (measured in mg HA/mm ³) ($p \leq 0.05$)	41

LIST OF FIGURES AND GRAPHS

Figure

1.	Demonstration of the compressible characteristics of bone putty	42
2.	Six week post-operative occlusal view of healed ridge	43
3.	Conventional radiograph taken after animals were sacrificed at 6 weeks	44
4.	Photomicrograph of a socket treated with bone putty (BP)	45
5.	Photomicrograph of a Xenograft particle	46
6.	Photomicrograph of XBx filled socket	47
7.	Photomicrograph of XBx site with xenograft particle	48
8.	Photomicrograph of bone putty site with Gomori Trichrome staining.....	49
9.	Photomicrograph of xenograft site with Gomori Trichrome staining	50
10.	Box plot representing ratio of bone volume to total volume within volume of interest between the treatment groups	51
11.	Box plot representing density measurement comparisons between the treatment groups.....	52

LIST OF ABBREVIATIONS AND SYMBOLS

1. BG- Bioactive glass
2. BMP – Bone morphogeneic protein
3. BP –Bone putty grafted site
4. BUN – Blood Urea Nitrogen
5. CaP – Calcium phosphate
6. CPK – Creatinine Phosphokinase
7. CS – Calcium sulfate
8. EMP – Enamel matrix proteins
9. FGF – Fibroblast growth factor
10. GGT - Gamma-glutamyl transpeptidase
11. IGF – Insulin like growth factor
12. HA - Hydroxyapatite
13. IACUC – Institutional Animal Care and Use Committee
14. PDGF – Platelet derived growth factor
15. PRP – Platelet rich plasma
16. SGOT - serum glutamic oxaloacetic transaminase
17. SGPT - serum glutamic pyruvic transaminase
18. TGF- β – Transforming growth factor beta

- 19. TCP – Tricalcium phosphate
- 20. μ CT – Micro computed tomography
- 21. w/w – Weight by weight
- 22. X- xenograft grafted site
- 23. XBX – Site grafted with xenograft bone particulate sandwiched between bone putty coronally and apically
- 24. XB3 – Site grafted with a 3:1 mixture by weight of bone putty and xenograft bone particulate

INTRODUCTION

Extraction is the end of the road for a tooth. Alveolar bone resorption often occurs after a tooth extraction (1). The bones of the maxilla and mandible, as well as other bones carrying mechanical loads, adapt their strength to the applied load. Under such stress, the bone undergoes continuous remodeling and maintains its mechanical competence (2). A lack of such stress, one of them being in an extraction site, is often attributed to play a part in alveolar bone resorption (3). Other factors that play a role in alveolar bone resorption are related to metabolic (nutrition, hormonal and cellular activity), anatomic (size, shape and density of alveolar ridges) and prosthetic factors (4). Several studies have reported anywhere between 40-60% of extraction socket resorption within the first 3 years (5, 6). Mandibular sites have been observed to resorb four times faster than maxillary extraction sites (7). The advent of dental implants and their optimal placement necessitates preserving extraction sockets with bone grafts in a delayed implant placement scenario to maintain a healthy bone-implant interface over a long period of time. The goal of socket preservation is to increase bone volume thereby promoting osseointegration and improving implant stability (8). Autografts, allograft, xenografts and non-osseous material like hydroxylapatite and bone ceramics are some of the wide range of bone grafting materials used in extraction sockets and periodontal defects (9). A better understanding of bone physiology and biomechanics has shown that bone grafts serve 3 primary functions of osteoinduction, osteoconduction and

osteogenesis. These will be defined and discussed further in a section ahead. Bone morphogenetic proteins and other biomimetic agents are being used to grow or augment bone in deficient sites (10). In general, the majority of these grafting solutions are available in the form of particulate bone chips, gels or liquids. The purpose of this review is to provide an overview of the extraction defect biology and the different materials used in preserving and/or augmenting this site in preparation for a predictable restoration of the edentulous site.

BIOLOGY OF THE HEALING EXTRACTION SOCKET

The tooth extraction socket is a unique bony wound due to the presence of residual periodontal ligaments unlike other bony wounds found in the human body (11). A blood clot is formed immediately after a tooth is extracted containing neutrophilic granulocytes and a network of cross-linked fibrin fibers along with plasma fibronectin, vitronectin and thrombospondin (12). This clot is also a reservoir of growth factors and cytokines that are released by the degranulation of activated platelets and serving as a provisional matrix for cell migration. These growth factors may in fact provide the start signals for wound repair and bone growth.(13) Indeed, the early healing events following tooth extraction, studied histologically in man, noted that bone formation begins as early as 10 days after extraction (11). Numerous studies have shown that the infilling of the socket may be due to one or many of the different mesenchymal cells present in the extraction socket. These cells originate from the residual periodontal ligament, periosteum, bone marrow, or blood vessel-associated pericytes (14-16) where they group together, usually near or around blood vessels, and differentiate into osteogenic cells which deposit bone matrix, constitutively. The fibrin mesh helps form the scaffold in the extraction socket and helps organize aggregates of bony matrix called bone spicules. Separately, mesenchymal cells differentiate into osteoblasts and form the bone matrix, the osteoid, while expressing proteins namely osteonectin, osteopontin and osteocalcin (17). Osteoblasts line up along the surface of the spicule and continue to secrete osteoid resulting in the increases in size of the spicule. As the spicules continue to

grow, they fuse with adjacent spicules resulting in the formation of trabeculae. When osteoblasts become trapped in their own matrix, they differentiate into osteocytes. Osteoblasts continue to line up on the surface which increases the size. As growth continues, trabeculae become interconnected and woven bone is thus formed. The term primary spongiosa is often used to refer to the initial trabecular network. Thereafter, the periosteum is formed along the trabeculae by differentiating mesenchymal cells. The primary center of ossification is the area where bone growth occurs between the periosteum and the bone. Osteogenic cells that originate from the periosteum increase appositional growth and a bone collar is formed. The bone collar is eventually mineralized and lamellar bone is formed (11), (18).

RATIONALE FOR SITE PRESERVATION

The need for alveolar ridge preservation is based on the observation that bone loss in a socket after tooth extraction is unavoidable and unpredictable (1). A study by Nevins demonstrated that sites without bone grafting had >20% loss of the buccal plate (19). This can result in a significant bony defect and inadequate bone volume for implant placement. As discussed above, bone healing and subsequent new bone formation takes place mainly through osteoinduction, osteoconduction and osteogenesis. Bone grafts tend to possess one or more of these properties. Osteogenic cells may be transplanted into the recipient graft in autogenous bone or bone marrow. It is important to note that only freshly harvested autogenous bone grafts or bone marrow aspirates contain these cells (20).

Osteoconductivity is the ability of the material to act as passive scaffolding supporting new bone formation while facilitating ingrowth of capillaries and bone. A number of inert materials such as ceramic grafts have this property while allogenic materials are capable of undergoing creeping substitution (20). In contrast, osteoinduction is defined as the presence of differentiating factors within graft materials that facilitate the recruitment and differentiation of mesenchymal stem cells and specifically induce their formation into osteoblasts and subsequent new bone formation. The family of bone morphogenic proteins (BMP) is the prototypical stimuli. Other factors that contribute to this process include transforming growth factors (TGF- β), insulin-like growth factors (IGFs), fibroblast growth

factors (FGFs), endothelial growth factors (EGFs) and platelet derived growth factors (PDGFs) (20).

A second important property of grafting materials is the ability to preserve the space required for new bone formation while helping exclude unwanted cells from the wound thus promoting the formation of new bone (21-23). Araujo and Lindhe studied the dimensional alterations of the alveolar ridge and the process of bone modeling and remodeling after tooth extraction in dogs over 8 weeks. The 3rd and 4th premolars of these dogs were hemisected and only the distal roots were extracted. The distal portion of the teeth was closed with the mobilized gingival tissue. Histologically, there was marked osteoclastic activity in the crestal portion of the buccal and lingual walls. Significantly, the buccal walls showed more resorption compared to lingual walls. The reduction in height was accompanied by varying degrees of horizontal bone loss as a result of osteoclastic activity along the buccal and lingual walls of the socket. The resorption of the buccal/lingual walls of the extraction site occurred in two overlapping phases. During phase 1, the bundle bone was resorbed and replaced with woven bone. Since the crest of the buccal bone wall was comprised solely of bundle bone, this modeling resulted in substantial vertical reduction of the buccal crest. Phase 2 included resorption that occurred from the outer surfaces of both bone walls (24). Several studies have confirmed this aspect of bone resorption in extraction sites. Lekovic and colleagues observed extraction sockets treated with and without absorbable barrier membranes. At 6 months, significantly less crestal bone loss (-0.38mm vs. -1.50 mm), more internal socket fill (-5.81 mm vs. -3.94 mm), and less horizontal ridge resorption (-1.31 mm vs. -4.56 mm) were found in the membrane group than in the control group (25). Barone and co-workers used xenograft particulate bone to fill extraction sockets which they compared to ungrafted extractions

alone. Significantly greater horizontal resorption was observed at ungrafted extraction sites (4.3 ± 0.8 mm) compared to grafted, ridge preserved sites (2.5 ± 1.2 mm). The ridge height reduction at the buccal side was 3.6 ± 1.5 mm for the extraction-alone group, whereas it was 0.7 ± 1.4 mm for the ridge-preservation group. Moreover, the vertical change at the lingual sites was 0.4 mm in the ridge-preservation group and 3 mm in the extraction-alone group (26). Biopsy cores harvested from the test and control sites revealed a significantly higher number of connective tissue in the ungrafted sites.

AUTOGENOUS GRAFTS

Autogenous grafts are considered to be the gold standard for bone grafting procedures due to its osteogenic, osteoinductive, and osteoconductive properties (10). In addition, they do not present a risk of disease transmission as the donor and recipient site are obtained from the same patient (27, 28). Cancellous bone has a higher percentage of cells and as a result has more osteogenic potential. Several clinical case studies have highlighted the use of intra-oral sites such as the chin and the ramus as potential harvesting areas to augment ridge deficiencies reporting a considerable degree of success with minimal to no complications (29-32). Palatal and mandibular tori have also been used to augment localized defects during implant site augmentation (33, 34). The potential complications encountered with such procedures are V3 paresthesia, insufficient cortical bone volume, disfiguration of the chin, infection and affecting adjacent tooth vitality (31, 35, 36). Extra-oral autogenous bone is available in larger quantities from iliac crest, rib, calvaria and tibia. The main advantage of autogenous bone is that it maintains bone structures such as minerals, collagen and viable osteoblasts (10). The main disadvantage is the requirement for a second surgical procedure and associated risks of pain, donor site morbidity and infection (1). Donor site morbidity is not warranted for such a small defect (viz. an extraction site) when allografts have shown to be equally successful (9). There are essentially two forms of non-vascularized free autogenous bone grafts: cortical and cancellous. Cancellous grafts re-vascularize more rapidly and completely when compared to cortical grafts whereas cortical grafts are better

able to withstand mechanical forces (11). Further, autologous grafts have been successfully used alone or in combination with allografts and xenografts in socket preservation techniques in delayed as well as immediate implant placement (37, 38).

ALLOGRAFTS

Allografts are bone grafts derived from the same species. They are commercially available in three forms: fresh frozen, freeze-dried bone allograft (FDBA) and demineralized freeze-dried bone allograft (DFDBA). FDBA is osteoconductive and osteoinductive and as the name implies, it is sterilized then freeze dried. Histological sections containing FDBA have shown osteoid forming bone spicules with osteoblasts observed at the rim of the osteoid deposits (39). DFDBA contains BMP's embedded in the matrix which aid in inducing bone formation. These BMP's are exposed during the demineralization process by osteoclasts (10). To date, 13 BMP proteins have been identified (BMP1-BMP13). Since BMPs are thought to possess osteoinductive and conductive properties, DFDBA is classified as such (40). A histological study in humans reported the presence of DFDBA particles at a significant distance from areas of bone formation and consisted of scarce connective tissue collagen fibers and empty osteocytic lacunae. This can be attributed to the presence of BMPs which may have induced bone formation (41).

Newer methods have recently been employed for the delivery of allograft materials. Carriers include collagen and/or selected polymers which contain the allograft material in a gel, putty or sponge-like consistency (40). Their potential uses include the treatment of periodontal bony defects, extraction sockets, ridge augmentations, cysts and bony defects of the jaw (40, 42). The main disadvantage of allografts is patient rejection due to religious beliefs or possible disease transmission. However, allografts undergo rigorous screening,

selection and testing of donors to ensure they are free of any communicable diseases and as such are considered safe for use by the American Association of Tissue Banks (43).

A recent systematic review published findings on the clinical effectiveness and predictability of allogeneic bone blocks for the correction of alveolar ridge deformities to support dental implant placement in humans.(44) A majority of the studies were observational studies in nature with no randomized clinical trials available in the literature to date. Although clinical evidence remained limited to case series and observations, these reports concluded that block allograft had a high rate of incorporation (>90%) and implant survival (99-100%). An article by Holtzclaw (45) outlined the various steps starting from graft harvest to recipient surgery. As soon as the tissue is procured, a soft-tissue stripping is performed followed by a reduction in size to approximately 5mm for easier processing. Saline, acetone, ethanol or hydrogen peroxide are used to debride, clean and decontaminate followed by antimicrobial, antimycotic and antifungal treatment. Liquid nitrogen freezes the bone particles down to -80 degrees C. The bone particles are then lyophilized with repetitive solvent washes to eliminate moisture content and reduce antigenicity. The particles undergo secondary size reduction approximately to about 250 to 750 micrometers. Thereafter, they are packaged in sterilized containers and undergo one final round of low-dose γ -radiation at low temperatures before being dispatched to the market.(45)

XENOGRAFTS

Xenografts are bone tissues derived from a different species other than the recipient species (9). An experimental study in dog extraction sockets noted that the presence of a xenograft (Bio-Oss Collagen) failed to inhibit the processes of modeling and remodeling that took place in the socket walls following tooth extraction. In fact, it apparently promoted *de novo* hard tissue formation, particularly in the cortical region of the extraction site (46). Further studies done in beagle dogs by the same group reported that this xenograft material acted as an osteoconductive material, was present after 6 months, and counteracted marginal ridge contraction (46, 47).

A human histological study evaluated xenograft histomorphometrically, and calculated the mean percentage of bone, residual graft and connective tissue by area over a mean healing time of 6 months. The mean percentage bone-to-graft contact was also calculated. The mean percentage area of new bone formation was 26.9%, and the percentage of residual graft and connective tissue as 25.6% and 47.4%, respectively. The mean percentage contact length between bone and residual graft was 34%. After 6 months, the xenograft still occupied $\frac{1}{4}^{\text{th}}$ of the area while another $\frac{1}{4}^{\text{th}}$ was occupied by new bone with connective tissue forming the remaining $\frac{1}{2}$ (48). However, the resorption of bovine bone has been seen in animal studies (49) more so than in humans (50). Nevertheless, the maintenance of the physical socket dimension can be enhanced by the use of xenograft bone particulate material.

For patients, one of the main disadvantages of a xenograft may be patient anxiety due to their fear over Bovine Spongiform Encephalitis (BSE) or “mad cow disease”. BSE is transmitted by a protein known as a “prion”. To date, only 3 human cases of BSE have been reported in continental United States as a result of meat ingestion (51). Thus, the prion is contained within the bone’s organic component so the risk of disease transmission is negligible as the organic components of bone are extracted during the processing and sterilization procedures (52).

Xenograft materials have been used in conjunction with bioactive peptides and have shown promising results in regenerating bone. A synthetically manufactured short chain amino acid peptide known as P-15 has been demonstrated to enhance bone activity. P-15 has been reported to attract and bind osteoblasts onto the bone grafting matrix. P-15 competes for attachment of collagen on cell surface sites and facilitates the physiological process similar to collagen by exchanging mechanical signals and promoting cell differentiation (53). P-15 associated with a synthetic or anorganic bone matrix has also been reported to enhance the osteoinductive effect (54).

SYNTHETIC BONE SUBSTITUTES

Synthetic bone substitutes are synthetically derived materials shown to be biocompatible, induce a minimal fibrotic reaction, and undergo remodeling and support new bone formation. Mechanically, these materials should have similar strength to that seen with cortical/cancellous bone (55). They should also be matched with a similar modulus of elasticity to that of bone (56). Synthetic materials that demonstrate some of these properties are composed of calcium and silicon. The disadvantages of these materials in the clinical settings include: low or unpredictable resorption, difficulty in handling (coral derived hydroxyapatite) and occasional inflammatory and foreign body reactions (56). Synthetic bone grafts used for site preservation to be discussed in this review include the ceramics such as calcium phosphates, calcium sulfates and composite polymers. Ceramics are inorganic crystalline materials that serve as synthetic scaffolds and are made from calcium phosphate currently in use in dentistry and in orthopedics (57). Tricalcium phosphate ceramic has a stoichiometry similar to bone precursors. They are not present naturally but have been shown to induce a biologic response similar to bone (58). Discussed further are a few of the synthetic bone substitutes used in clinical dentistry.

Calcium Phosphate and Derivatives

Hydroxyapatite (HA) is a calcium phosphate derived bioactive material present in human bone and teeth (57). It can be extracted and obtained from natural sources such as bovine bone or coral. Coral porosity is an important property in its role as a graft material. The porosity size has been reported to be directly related to its rate of bone formation and resorption. The smaller the porosity, the greater its density and compressive strength and corals of higher porosity facilitate larger ion exchange thus promoting faster bone turnover (59). Corals are sintered at high temperatures which eliminate organic material including proteins thus preventing graft v/s host disease in patients. New bone is formed around the particulates of hydroxyapatite in stages. That is, by formation of fibrous tissue around the chips of HA and later forming woven bone. HA is noted histologically after new bone has been formed (60) and is generally osteoconductive although a few studies have suggested that it has osteoinductive properties (61-63). Hydroxyapatite has also been used as coating on dental implants to enhance their osseointegration potential. Direct bone attachment has been observed on plasma-sprayed HA-coated titanium alloy surface, while fibrous tissue was encapsulated on the uncoated surface.(64) The disadvantages of HA is the tendency for migration of the granules, the lack of complete resorptive process of the particles (65) and its bacterial susceptibility.(66)

Another derivative widely used in clinical dentistry is β -tricalcium phosphate. The first dental application was reported by Nery et al. in the 1970's using a synthetic porous material obtained by sintering a 'tricalcium phosphate reagent' that was originally described as "tricalcium phosphate" or "TCP" but later demonstrated to consist of a mixture of HA and TCP (67). Attachment as well as phagocytosis of tricalcium phosphate has been demonstrated *in-vitro* (64, 68)(64, 64, 68, 68, 69). TCP enhances attachment, proliferation, and differentiation of osteoblasts and expression of collagen, proteoglycans, osteopontin, osteocalcin and bone sialoprotein (70, 71). This supports the findings that TCP is an osteoconductive material (70) although it has been known classified as an osteoconductive material (72, 73). Since this osteoinductive property was observed in some calcium phosphate materials but not in others of similar composition, these materials were described to have 'intrinsic' osteoinductivity. This inductive phenomenon for some calcium phosphate (CaP) materials was attributed to the topography, geometry, composition, macropore size, and percent porosity of the CaP. Such geometry was believed to allow entrapment and concentration of circulating bone growth factors (BMPs) and osteoprogenitor cells imparting osteoinductive properties to the CaP materials. An alternative method by which CaP can induce bone is by using it as a carrier. This is called "Engineered Osteoinductivity" i.e. the material is combined with growth factors which induce bone formation (67). This has been used in the field of periodontal regeneration in combination with collagen peptides and platelet derived growth factors (PDGF) (54, 74). However, one disadvantage for its use in extraction defects may be the high cost of PDGF.

Bio-Glass

Bio-active glasses (BG) are silico-phosphate chains that are used in glass ionomer cements. It is considered to be highly biocompatible and exhibit bone bonding, a phenomenon also observed with other bioactive ceramics. This process is a result of the surface reactive silica, calcium, and phosphate groups that are characteristic of these materials. Silica is believed to play a critical role in bioactivity. These materials have the ability to chemically bond with bone and are proposed to function as small bone regenerative chambers (75). Although BG is generally used as a space-maintainer, their granular nature decreases their reliability. BG has been used for ridge augmentation for future dental implant placement (76-78). A histological and clinical study reported a clinical success rate of 96.8% with implants placed in BG preserved sites. A human histological study demonstrated that connective tissue was observed in the absence of an inflammatory response while increasing evidence of bone formation was seen in direct relation to the bioactive glass material after 6 months (79). However, there are no systematic reviews available on the use of BG and it is possible that biocompatibility and bone bonding ability could be enhanced if used as carrier materials for growth factors (80).

Calcium Sulfate

Plaster of Paris or the β -hemihydrate form of calcium sulfate (CS) is one of the first materials investigated as a bone graft substitute. It has been extensively used in orthopedic surgery due to its inert, osteoconductive, rapid setting, resorbing and biocompatible properties (81). CS is soluble *in vivo* and acts as a source of calcium for mineral formation. It can be chemically synthesized or naturally obtained from mined gypsum (82). A few studies have used medical grade calcium sulfate for extraction site ridge preservation. Clinical and histological findings have revealed formation of trabecular bone with woven and lamellar arrangements (83-85). Dental implants placed in sites previously preserved with calcium sulfate have shown similar radiographic results to those placed in hydroxyapatite and porcine derived bone grafts (86). However, the main drawbacks are its mechanical strength which fails to provide adequate long term support to the defect site (87). Further, Plaster of Paris fails to form a chemical bond with bone tissue at the early stages due to its poor bioactivity and has a rapid rate of resorption which negatively affects bone regeneration (88).

OSTEOACTIVE AGENTS

Osteoactive agents are materials which possess the ability to stimulate deposition of bone. They can be classified as osteoinducers, osteopromoters and bioactive peptides. The compounds in the first two categories are growth factors whose function is to regulate normal physiological processes and biological activities such as receptor signaling, DNA synthesis and cell proliferation (89). Growth factors are chemotactic, mitogenic and morphogenic in nature. Urist and co-workers demonstrated that demineralized bone matrix had low-molecular weight proteins which induced bone induction, today known as BMP's (90). Since then, significant progress has been made in this field and has now included the commercially-availability of platelet derived growth factors, enamel matrix proteins and bioactive polypeptides.

Platelets contain a number of different growth factors which are released into the tissue after injury. These include transforming growth factor (TGF- β), platelet derived growth factor (PDGF), insulin-like growth factor (IGF), and fibroblast growth factor (FGF) which act as differential factors on hard and soft tissues (91). Commercially-available PDGF-B (GEM-21, Osteohealth, Shirley, NY) is packaged in a 0.3 mg/ml concentration in combination with β -TCP and has shown to result in excellent bone quality and quantity for future implant placement (92). Platelet rich plasma (PRP) is a second potential source of concentrated platelets currently in use for bone regeneration. The processes for PRP preparation involves the collection of whole blood (with the anticoagulant citrate dextrose)

that undergoes two stages of centrifugation designed to separate PRP from low-platelet plasma and red blood cells. Platelets are activated by mixing with a solution of calcium chloride thrombin, which activates the clotting cascade mechanism. The entire process, starting from its activation to secretion of factors, is completed in 10–15 minutes (93). A randomized clinical trial tested PRP against a control group composed of iliac crest grafts in sinus augmentation procedures. This investigation could not elicit any appreciable clinical advantage with the use of PRP (94). However, a meta-analysis by Bae and co-workers demonstrated that bone regeneration was higher in sites treated with PRP compared to other sites. In terms of implant stability, there were no significant differences between the test and control groups. They concluded that there was sufficient evidence to support the use of PRP (95). A systematic review also reported that PRP improved the handling characteristics of particulate bone graft but had very limited positive effects on bone healing (96). A disadvantage of using PP is the appreciable start-up costs the centrifuge and the time involved in preparing the PRP.

Enamel matrix proteins (EMP) have shown potential in the regeneration of lost periodontal attachment. This is achieved due to the effect of these proteins in the formation of acellular cementum, a key tissue in the development of a functional periodontium (97). However, its use as in ridge augmentation procedures is minimal due to the lack or need for acellular cementum in such sites.

BARRIER MEMBRANES

Membranes are used in ridge preservation and guided-tissue regeneration (GTR) procedures and function as barriers to exclude rapidly-proliferating, non-bone inducing cells. A landmark study by Bowers demonstrated that cells that reach the wound site first tend to form or initiate its lineage (98-100). Membranes aid in excluding epithelial cells from the extraction site so that the osteoblasts are given the opportunity to reach the wound site first and form new bone. After tooth extraction they are commonly used (in combination with bone graft materials) in guided bone regeneration procedures in cases where the buccal plate of bone is thin or completely lost (101). These membranes are available in resorbable and non-resorbable forms. The non-resorbable membranes are primarily made of expanded polytetrafluoroethylene (e-PTFE) and are often reinforced with titanium to enhance pliability and space maintaining properties. However, a second surgery is needed to retrieve these membranes from within the surgical area. The resorbable barrier membranes are made up of Type I and III bovine or porcine collagen and resorb in 18-24 weeks by enzymatic degradation (102). Some are chemically treated to prolong their barrier function. Further, acellular dermal allografts, bovine and human pericardium has been shown to be effective as barrier membranes (103, 104)(105, 106). Lekovic et al. observed the clinical effectiveness of barrier membranes in preserving alveolar ridges after tooth extraction. Results showed that membrane-covered sites presented with significantly less ridge atrophy than control sites (107). Selection of barrier membrane depends on resorbability, defect size and morphology,

operator preference and patient acceptance (108). Difficulties associated with barrier membrane use during socket augmentation include the potential reduction of keratinized gingival, alterations of gingival contours, and migration of the mucogingival junction, as a result of coronal displacement of the flap in an attempt to achieve soft tissue closure over the membrane (109).

SUMMARY

Bone is a dynamic tissue due to its constant ability to form and resorb. Its unpredictable nature can be managed with the use of bone grafts. Numerous surgical techniques and materials have been documented in the literature to augment or preserve bone. The ability of natural or synthetic bone grafts to help form bone largely depends on the innate properties of the graft materials and the host response. These properties include chemical composition, morphology, porosity and particle size. The clinical choice of bone graft materials is dependent on operator and patient factors. Each of the materials presented in this review have demonstrated success in ridge preservation techniques. This is largely due to these materials' biologic or physical resemblance to natural bone. Osteoactive or bio-modifying agents have ushered in a new era of therapy in clinical dentistry. These agents elicit cell and tissue-specific responses that signal the initiation of new bone formation. Further research is needed to determine the application of these bio-modifiers in preserving and augmenting the bone present in the human extraction socket. Thus, while autologous grafts are the gold standard, the requirement for a second surgical site and the availability and predictability of commercially available materials has questioned the need for autogenous grafts (110). Advances in material science, cellular/molecular biology, and surgical techniques will continue to provide therapeutically meaningful outcomes in bone regeneration procedures.

IN VIVO ASSESSMENT OF OSSEOUS WOUND HEALING USING BONE PUTTY IN THE SURGICAL MANAGEMENT OF TOOTH EXTRACTIONS

INTRODUCTION TO CLINICAL STUDY

The extraction of teeth is a common procedure performed in clinical dentistry to address severely decayed, periodontally-involved, non-restorable or impacted teeth. A majority of these extractions are performed using lidocaine as the local anesthetic agent (111).

Unfortunately, exodontia can be associated with significant post-operative pain and bleeding especially in patients on anti-coagulant therapy (112). To address post-operative discomfort, analgesics are often prescribed. These analgesics tend to have 4-6 hours duration of action when taken orally, and may require multiple dosing of up to 4-6 tablets daily (113).

However, this can be associated with unwanted side-effects of the gastrointestinal, cardiovascular, and renal systems (114). Prolonging the duration of analgesia without increasing local or systemic levels of these analgesics becomes a desirable goal in clinical practice. Local drug delivery systems have been developed in dentistry but very few addressed delivery of anesthetic or analgesic agents (116-120). In fact, an online search of the MEDLINE database using key words ‘dental’, ‘local’, ‘delivery’, ‘anesthetic’ and ‘analgesic’ identified only 1 study (115) thus highlighting the need for further study. Xybrex bone putty is an implantable, hand-moldable (with a consistency similar to modeling clay), absorbable delivery system that provides the controlled release of lidocaine and is based on a Food and Drug Administration-approved absorbable bone hemostat. Its constituents are a

bioresorbable mixture of calcium stearate (a wax-like tamponade), 16% (w/w) lidocaine, liquid vitamin E (for handling properties) and alkylene oxide copolymer (a dispersing agent). It has been previously shown to provide several days of functional sciatic nerve blockade in rats (116) and is currently being marketed to orthopedic surgeons for local pain management and bone hemostasis. It is possible that hemostatic bone putty containing a slow release anesthetic may be therapeutically beneficial in the management of simple and complicated exodontia. Further, a mixture of bone putty with particulate bone material may provide these same benefits in addition to helping conserve the three dimensional architecture of the extraction socket in preparation for implant placement (9). The main objectives of this pilot, preclinical study are to assess the safety profile, biocompatibility and healing response of oral tissues to this bone putty in a dog tooth extraction model.

MATERIALS AND METHODS

Surgical Procedure

The animal experimental protocol was approved by the Institutional Animal Care and Use Committee (IACUC) of the University of North Carolina at Chapel Hill. Five female beagle dogs approximately a year old and weighing approximately 25 pounds were used in this study. All dogs had a full set of erupted permanent teeth with minimal plaque around the necks of the teeth. The dog extraction site model was used for this study (117). The animals were anesthetized intravenously with 4-6mg/kg sodium pentothal. Once under anesthesia, the animals were intubated to maintain a patent airway. The level of anesthesia was maintained and monitored with the help of a blood pressure cuff and pulse oximeter by a veterinarian. Blood was drawn from each of the animals for a pre-operative blood chemistry panel inclusive of liver function tests. Thereafter, 2% lidocaine was infiltrated into the buccal and lingual tissues of the right side of the mandibular arch. The mandibular right 1st, 2nd, 3rd and 4th premolars were hemisected with a thin fissure bur under copious irrigation and atraumatically extracted with elevators and forceps. The extraction sockets were thoroughly debrided and grafted with one of the four treatment arms: a) bone putty only [BP], b) bovine xenograft particulate (BioOss, Osteohealth Inc., Shirley, NY) and collagen plug (CollaPlug-Zimmer Dental, Carlsbad, CA), [X] c) xenograft particles sandwiched between layers of putty placed in the coronal and apical aspect [XBX], d) A 3:1 mixture by weight of putty and xenograft particle respectively [XB3].

The xenograft/collagen plug socket served as the control in each animal. The extraction sockets were then sutured and stabilized with 4-0 chromic gut suture.

Post-Operative Care and Euthanasia

The dogs were maintained on a mush diet for the entire duration of the study. Post operatively, Ibuprofen 400mg and Amoxicillin 500mg were given orally, three times a day for 3 and 7 days respectively. Visual observations of soft tissue healing were made every two days for 6 weeks. After 6 weeks, a second round of blood was drawn for complete blood and electrolyte count. Thereafter, the animals were euthanized with an overdose of pentobarbital (120mg/kg IV) through the carotid arteries. A mixture of 5% glutaraldehyde and 4% formaldehyde were infused and mandibles dissected *en-bloc*. The right side was resected from the canine to the 1st molar with a high speed disc bur and placed in 4% paraformaldehyde.

Blood Chemistry Panel

Pre-surgical and 6 week blood samples were assayed for complete blood chemistry panel including liver function tests which included albumin, alanine transaminase (SGPT) and aspartate transaminase (SGOT). This was done as lidocaine is metabolized mainly in the liver and thus helps determine any toxicity.

Radiographic Analysis

Conventional radiographs were taken immediately after resection (Faxitron X-ray Lincolnshire, IL, USA) to qualitatively examine for the presence of residual material and general appearance of the socket. This was followed by a micro computed tomography (μ CT) scan (SCANCO Medical μ CT 40, Brüttisellen, Switzerland) to acquire basis images from which axial slices and cross-sectional images were generated. Each slice was 0.07mm in the

bucco-lingual direction with 1144 slices obtained per sample. The entire section was scanned with a resolution of 1024x1024 pixels. Each slice was then examined at a 2x magnification and the sockets were marked as a region of interest. All material present within the region of interest in each socket was included and determined to be the 'Total Volume'. After scanning, the 3-D data sets were segmented by using individual global thresholds, above which all pixels are considered bone, and below which all pixels are considered non-bone. The threshold of each data set was determined using an adaptive method, where the gray level data set is segmented at different levels. The threshold, where the volume fraction changes the least, i.e. the steepest gradient of gray levels, was chosen as the threshold for the data set (Scanco Medical AG, 1997). These μ CT images were then analyzed in 3D using μ CT analysis software (SCANCO Medical, Brüttisellen, Switzerland) according to manufacturer's instructions. Ratio of Bone Volume to Total Volume of extraction socket and Mean Bone Density measurements (as measured with mg HA/mm³) were obtained.

Histological Analysis

Each specimen was fixed in 10% buffered formalin after harvesting. The specimens were then decalcified using an immunohistochemistry-compatible demineralizing agent (ImmunoCalTM - Decal Chemical Co., Tallman, NY). After demineralization, each specimen was processed for routine histology and embedded in paraffin to make tissue blocks. Sections were cut in the bucco-lingual dimension. The sections were stained in Haematoxylin-Eosin and Gomori Trichrome staining. Serial sections were observed under a light microscope (Olympus DX41, Center Valley, PA) Magnifications of 100x, 200x and 400x was used to qualitatively assess each extraction socket/graft site.

Statistical Analysis

A One-Way Analysis of Variance, Kruskal-Wallis Test and the post-hoc Dunn's multiple comparison tests were used to compare the animals with the different treatment groups as the variables (GraphPad Software Inc., La Jolla, CA).

RESULTS

Handling Characteristics

The BP material was moldable and could be shaped and compressed into the socket with finger pressure (Figure 1). Rapid and sustained hemostasis was obtained when applied into the extraction socket. The material tended to be somewhat sticky but was favorable when mixed with xenograft particulate.

Safety Assessment

All the animals tolerated the procedure well and did not display any signs such as raised body temperatures or any swelling on the face, indicative of infection, over the entire duration of the study. The 48 hour visual examinations of the extraction sockets over the duration of 6 weeks revealed the normal stages of healing of extraction sockets. Initially the area was filled with a whitish granulation tissue. This slowly turned pinkish red, eventually resulting in epithelial closure over the extraction site. Rapid and complete soft tissue closure was noted over each of the extraction sockets in all the animals regardless of the treatment arm (Figure 2). Comparison of pre- and post-operative clinical chemistries revealed normal mean levels of most of the blood chemistries and liver function tests. Table 1 and 2 displays the blood chemistry panel for 2 representative animals with the mean ranges of each test. No significant differences were noted for any of the clinical chemistries for all the animals.

Radiological Assessment

Conventional 2D radiograph taken after 6 weeks revealed complete socket fill in all sockets of all the animals (Figure 3). Radiographic density was comparable amongst all the sites. μ CT analysis was performed to determine the density of the materials. This is shown in Table 3. Significant differences can be noted between the materials with the bone putty having the lowest and the xenograft having the highest density. μ CT analysis for the ratio of bone volume to total volume for each of the material and animals is shown in Table 4. The bone density measurements for the different treatment groups are shown in Table 5. The BP-treated sites had a mean ratio of bone volume to total volume of 0.557 ± 0.05 . In comparison, the X sites had a mean ratio of 0.5544 ± 0.05 while the treatment arms XBX and XB3 had mean ratios of 0.482 and 0.491 respectively with similar standard deviations of 0.114. The mean bone density for BP and X sites was 816 ± 12.7 mg HA/mm³ and 841.7 ± 20.97 mg HA/mm³ respectively. The XBX group had a mean density of 838.6 ± 3.91 mg HA/mm³ while the XB3 group had a mean density of 822 ± 11.8 mg HA/mm³. There were no statistically significant differences between the different treatment arms for bone density. Overall there were no statistically significant differences between treatment groups when compared with a Dunn's multiple comparison tests at a p value ≤ 0.05

Histological Assessment

Serial sections were observed under a light microscope at multiple magnifications. The socket could be identified due to the difference in the depth of staining between the cortical bone and immature vital bone as well as the presence of the cement line lines and woven bone in the new bone and lamellar bone in the native mandible. Each socket demonstrated some loss of buccal bone as in agreement with other animal studies (118).

The sockets treated with BP contained appreciable amounts of vital bone. Voids could be observed which may have been previously filled with the bone putty material (Figure 4) but the material was likely lost during processing of the tissue. As expected, the sockets grafted with xenograft and collagen sponge [X] contained remnants of xenograft particles between the newly formed bone (Figure 5). The XBX and XB3 sites showed similar findings as the bone putty and xenograft sockets except for 1 animal that displayed evidence of a foreign body reaction with inflammatory cell infiltrate in one XBX site (Figure 6). That socket showed that there is no bone surrounding the xenograft particle (Figure 7). All other sockets appeared to display normal healing.

Gomori Trichrome staining was also used to distinguish new bone and osteoid from native lamellar bone. Osteons can be seen in Figure 8 representing the BP grafted sites stained blue indicating that the connective tissue present in the sockets was indeed bone matrix that is maturing in those areas. The areas of voids can also be observed as mentioned earlier. Figure 9 illustrates a xenograft site [X]. Bone particles (stained light blue) can be seen surrounded by osteoid and bone matrix. Areas which are stained with a pinkish hue are suggestive of more mature bone.

DISCUSSION

The present study in animals evaluated the use of hemostatic and anesthetic bone putty following tooth extraction in different configurations and was compared to a xenograft and a collagen plug which is often used for extraction and site preservations procedures in human extraction sockets. The main goals of this study were to assess the material's safety profiles locally and systemically with the help of blood chemistry panel as well as to characterize the radiographic and histological response. Secondly we sought to note its handling characteristics and hemostatic properties. Human clinical trials will assess the analgesic properties.

We noted that although the material was slightly sticky, this property appeared to help maintain it within the extraction sockets. We also noted immediate and sustained hemostasis (i.e. the bleeding from the socket did not last more than a few seconds) in sockets grafted with BP, XB3, or XB4. Anecdotally, the control socket demonstrated rapid hemostasis although it was slightly slower than sites grafted with the bone putty.

Healing progressed normally and complete soft tissue closure was observed in the surgical site over the 6 week period without any untoward allergic or anaphylactic reactions. At 6 weeks, μ CT analysis all specimens failed to demonstrate statistically significant ($p \leq 0.05$) differences in bone density suggesting that the bone putty did not interfere with bone metabolism compared to control sockets. Further, with the exception of 1 socket, the histological images containing the bone putty material did not show any untoward

inflammatory reaction after 6 weeks. A few voids were noted histologically in the BP-containing sockets in the absence of an inflammatory infiltrate which may have been previously occupied by the material. This could be due to the decalcification and histological processing. Alternatively, the material could be well on its way to resorption within the socket. Indeed, in orthopedic surgical procedures, the BP is resorbed in approximately 4 weeks time (personal communication, Orthocon, Inc., Colts Neck, NJ). In agreement with other studies, the X particles did not resorb completely over 6 weeks. It has been previously reported that xenograft particles could be observed after 6 months in dogs (47).

As seen in Figure 10 the ratio of bone volume to total volume of the socket ranged around 40%-60%. The high standard deviation was noted in XB3 and XB3 grafted sites possibly due to varied bone formation in these sites. Further, the density of sockets grafted with BP was lower than those grafted with X (Figure 11). This is consistent with the fact that BP does not contain any mineralized particles. Conversely, xenograft is made of inorganic bovine bone and as expected, sockets grafted with X showed the highest density compared to sockets containing BP. In addition, it is possible that differences in bone formation and resorption rates may vary between animals.

The calcification of bone matrix increases bone density over time (119). Histologically, most of the sockets showed a minimal inflammatory infiltrate suggesting that all materials used were well tolerated by the animals. One socket in one animal showed evidence of a foreign body reaction with minimal formation of bone in one of the sockets (Figure 6, 7). Further studies should help clarify this finding. However, the material is FDA approved for use in orthopedic procedures and has been noted to demonstrate a minimal inflammatory reaction in other animal models (personal communication, Orthocon Inc., Colts Neck, NJ).

This finding could also be attributed to the fact that the uses in orthopedic medicine are under sterile conditions and the dogs were not in a gnotobiotic state so they may have had significant contamination from daily activities like eating and chewing.

Nevertheless, we noted bone formation in sockets grafted with BP and also noted that it did not interfere with bone formation when combined with X.

The potential limitations of this study were: that the analgesic properties of the BP were not determined; the lack of randomization; small number of animals; the absence of dynamic histomorphometry; and the absence of untreated extraction sites (clot only)

CONCLUSIONS

Our pre-clinical pilot study indicates that bone putty, when used alone or in combination with xenograft bone particulate, did not induce adverse local, systemic or radiographic responses.

With the exception of one socket, the histological assessment indicated that the bone putty tested did not interfere with the normal healing process in an extraction socket. Thus this bone putty appears to be a safe, bio-compatible product when used in extraction sockets.

Further studies are required to confirm these findings as well as to assess its analgesic properties in extraction sockets.

FIGURES AND TABLES

Table 1. Blood chemistry tests of two representative animals (before surgery).

Test	Animal 1	Animal 2	Reference Range	Units
Total Protein	5.7	5.7	5.0-7.4	g/dL
Albumin	3.6	3.4	2.7-4.4	g/dL
Globulin	2.1	2.3	1.6-3.6	g/dL
Cholesterol	143	221	92-324	mg/dL
SGOT	30	21	15-66	U/L
SGPT	33	74	12-118	U/L
Alkaline Phosphatase	25	20	5-131	U/L
GGT	<5	<5	1-12	U/L
Total Bilirubin	0.2	0.2	0.1-0.3	mg/dL
Amylase	605	580	290-1125	U/L
Urea Nitrogen	12	16	6-25	mg/dL
Creatinine	0.5	0.7	0.5-1.6	mg/dL
BUN/Creatinine ratio	24	23	4-27	Ratio
Phosphorus	5.3	4.3	2.5-6.0	mg/dL
Glucose	96	107	70-138	mg/dL
Calcium	9.7	10.4	8.9-11.4	mg/dL
Magnesium	1.4	1.6	1.5-2.5	mEq/L
Sodium	145	146	139-154	mEq/L
Potassium	4.2	4.6	3.6-5.5	mEq/L
Triglycerides	21	26	29-291	mg/dL
CPK	122	128	59-895	U/L

Table 2. Blood chemistry tests of two representative animals (after surgery).

Test	Animal 1	Animal 2	Reference Range	Units
Total Protein	5.6	5.6	5.0-7.4	g/dL
Albumin	3.5	3.4	2.7-4.4	g/dL
Globulin	2.1	2.2	1.6-3.6	g/dL
Cholesterol	163	176	92-324	mg/dL
SGOT	23	27	15-66	U/L
SGPT	25	39	12-118	U/L
Alkaline Phosphatase	27	24	5-131	U/L
GGT	<5	<5	1-12	U/L
Total Bilirubin	0.1	0.1	0.1-0.3	mg/dL
Amylase	635	694	290-1125	U/L
Urea Nitrogen	12	15	6-25	mg/dL
Creatinine	0.4	0.7	0.5-1.6	mg/dL
BUN/Creatinine ratio	30	21	4-27	Ratio
Phosphorus	4.0	3.8	2.5-6.0	mg/dL
Glucose	94	104	70-138	mg/dL
Calcium	9.0	10.3	8.9-11.4	mg/dL
Magnesium	1.4	1.5	1.5-2.5	mEq/L
Sodium	144	152	139-154	mEq/L
Potassium	3.2	4.5	3.6-5.5	mEq/L
Triglycerides	24	32	29-291	mg/dL
CPK	103	166	59-895	U/L

Table 3. Density measurements of the materials (mg/mm³).

Materials	Density(mg/mm³)
BP	387.66
X	607.45
XB3	435.93
XBX	452.71

Table 4. Summary statistics for Ratio of Bone Volume to Total Volume ($p \leq 0.05$).

	BP	X	XBX	XB3
<u>Minimum</u>	0.4795	0.4876	0.3118	0.3408
<u>25% Percentile</u>	0.5112	0.5078	0.3832	0.3716
<u>Median</u>	0.5565	0.5494	0.4705	0.5359
<u>75% Percentile</u>	0.6050	0.6035	0.5874	0.5891
<u>Maximum</u>	0.6115	0.6038	0.5968	0.6053
<u>Mean Ratio</u>	0.5578	0.5544	0.4823	0.4914
<u>Std. Deviation</u>	0.05220	0.05002	0.1143	0.1142
<u>Std. Error</u>	0.02334	0.02237	0.05111	0.05108
<u>Lower 95% CI</u>	0.4929	0.4923	0.3404	0.3496
<u>Upper 95% CI</u>	0.6226	0.6165	0.6242	0.6333

Table 5. Summary statistics for Bone Density Measurements (measured in mg HA/mm³) (p≤0.05).

	BP	X	XBX	XB3
Minimum	800.9	816.9	833.8	809.2
25% Percentile	802.3	823.0	835.1	810.3
Median	822.2	843.5	837.6	824.8
75% Percentile	826.6	859.4	842.6	832.2
Maximum	827.6	872.7	842.7	837.8
Mean	816.0	841.7	838.6	822.0
Std. Deviation	12.70	20.97	3.911	11.80
Std. Error	5.7	9.4	1.7	5.3
Lower 95% CI	800.2	815.6	833.7	807.3
Upper 95% CI	831.8	867.7	843.5	836.6

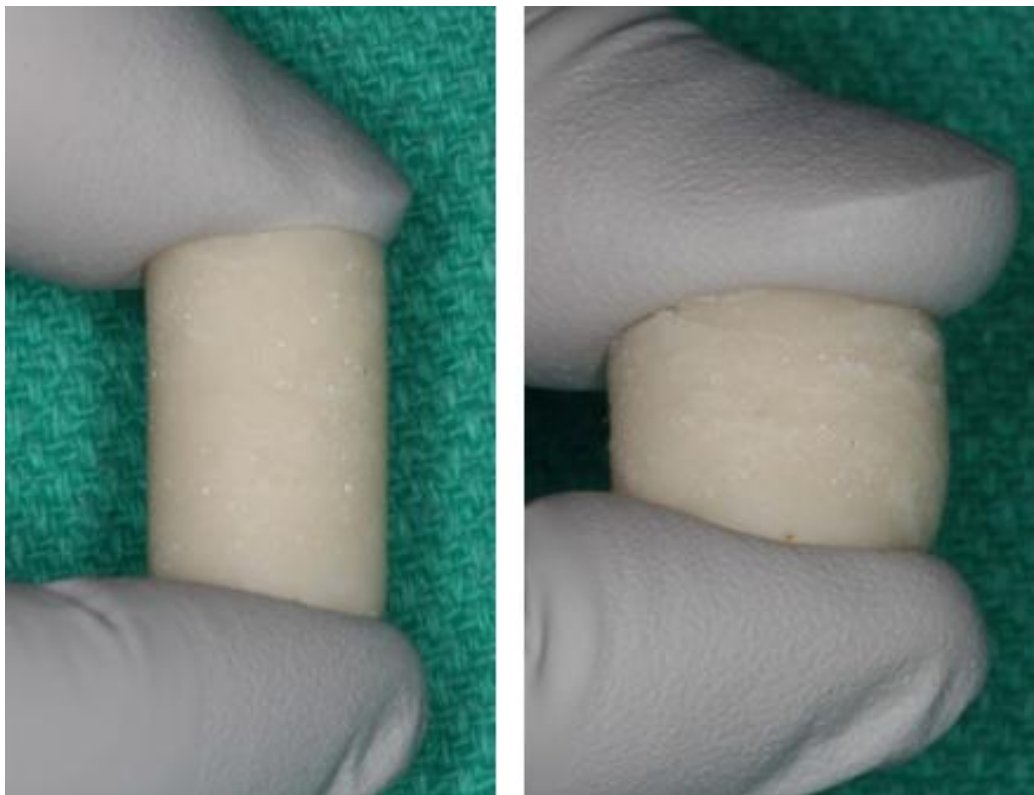


Figure 1. Demonstration of the compressible characteristics of bone putty.

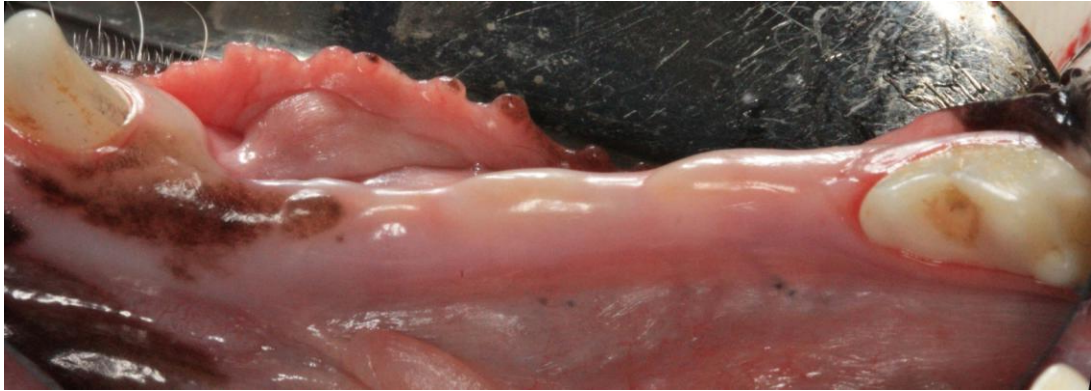


Figure 2. Six week post-operative clinical view. Occlusal view of the right mandibular ridge demonstrating complete closure of extraction sockets and lack of clinical signs of inflammation.

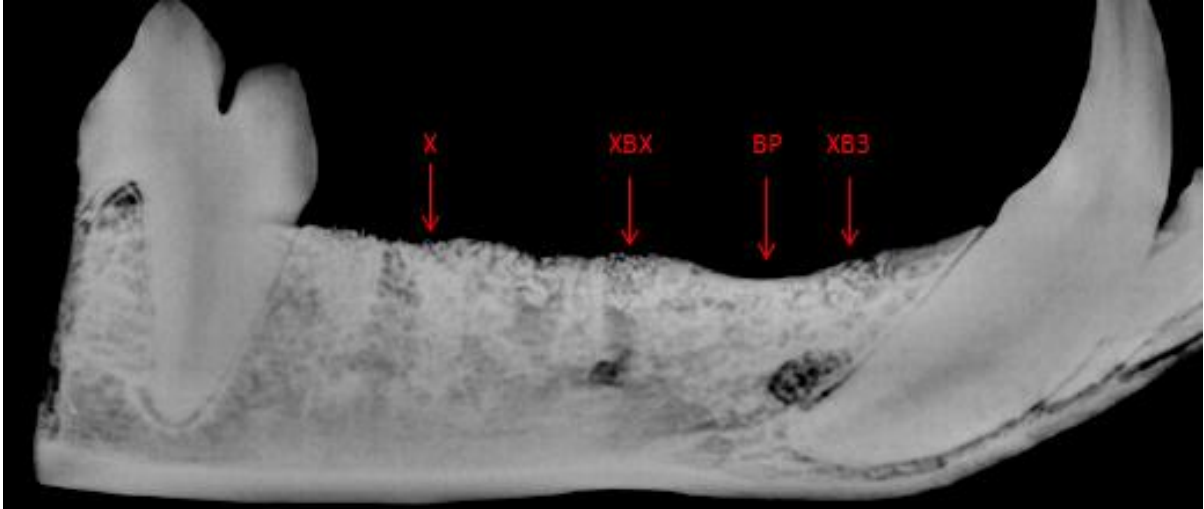


Figure 3. Conventional radiograph taken at time of euthanasia (6 weeks post-op). This figure represent an image from one of the animals. Each of the sockets is represented by the configuration grafted.

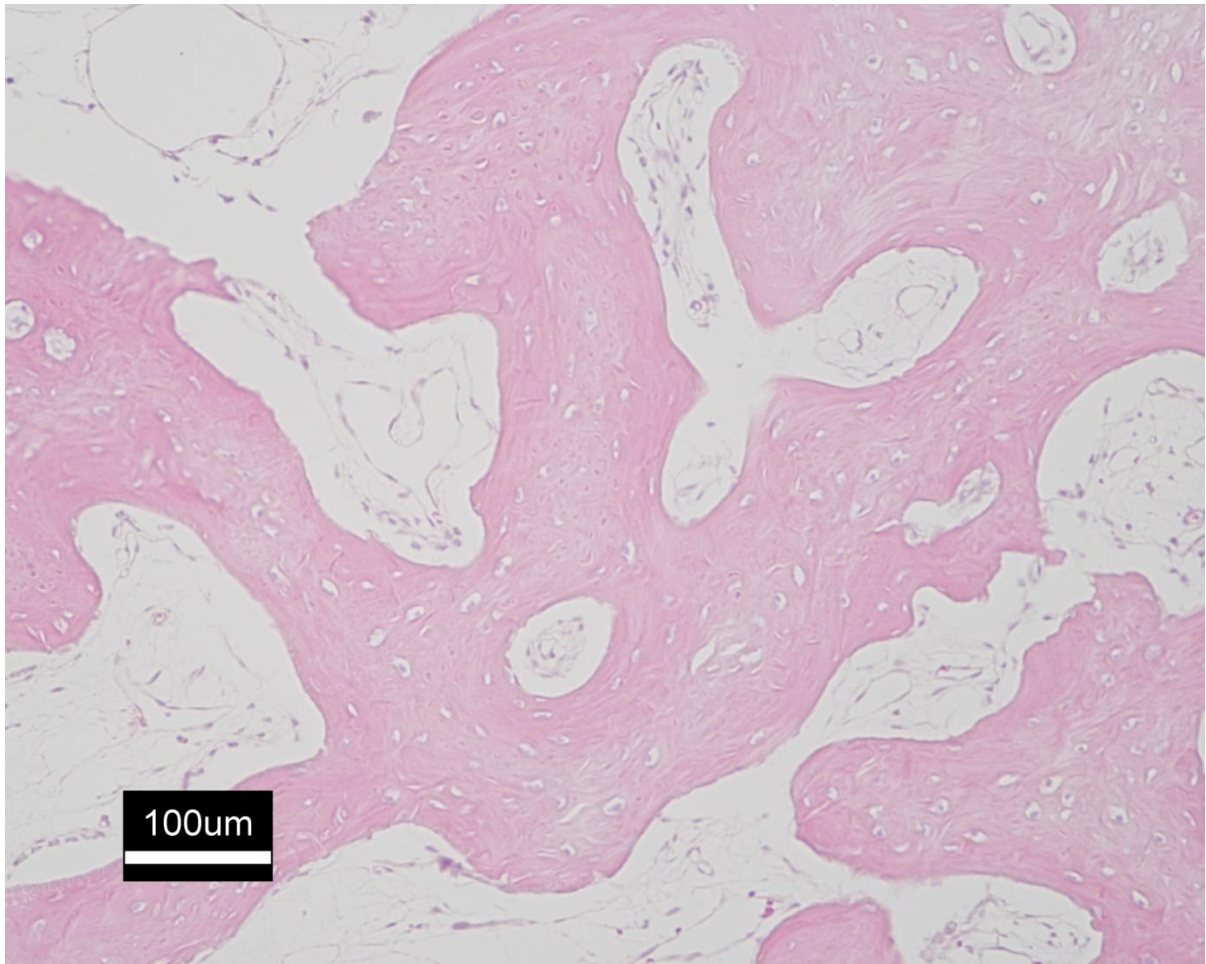


Figure 4. Photomicrograph of a socket treated with bone putty (BP). Note the islands of bone tissue. Hematoxylin and eosin stain. Magnification – 100X.

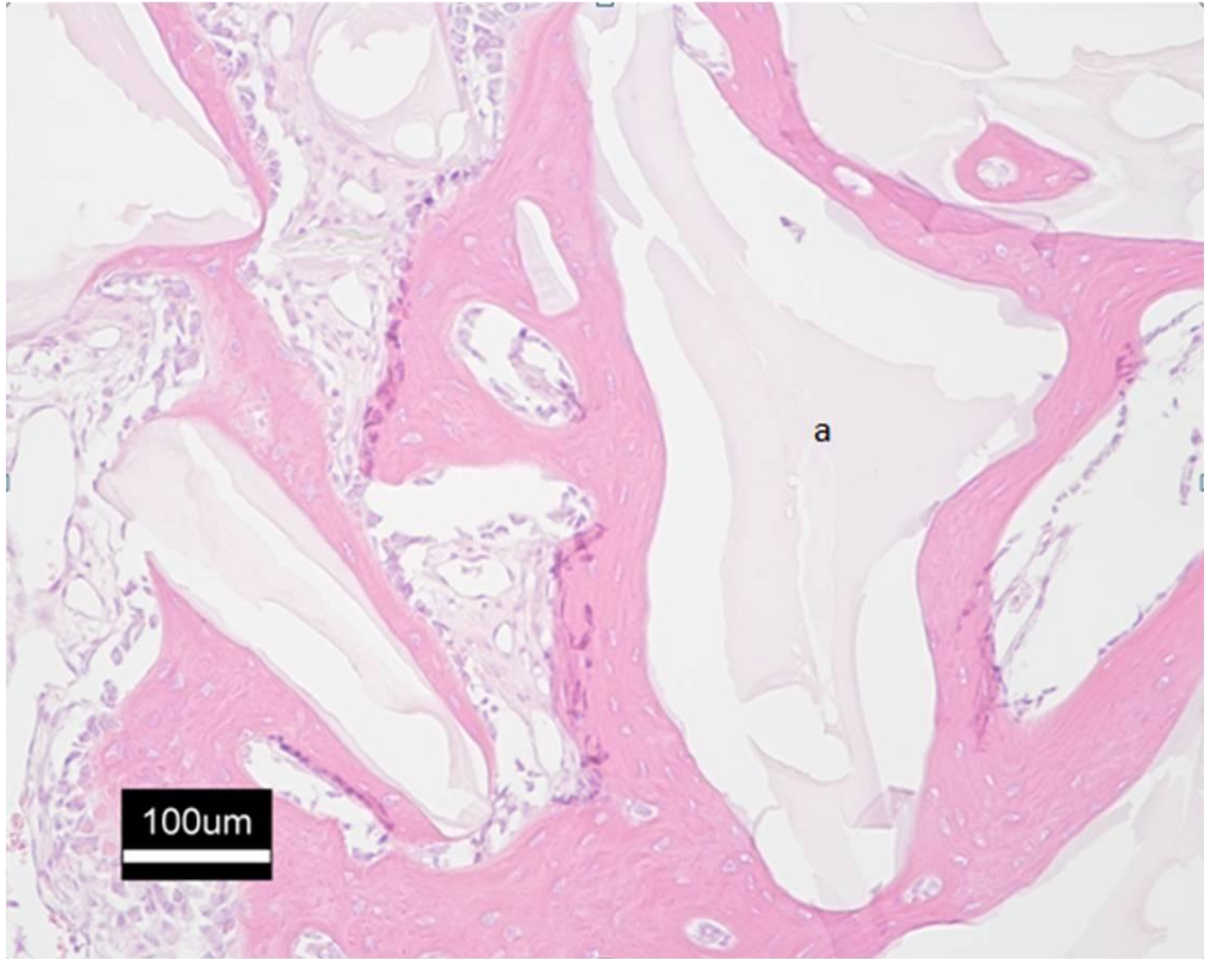


Figure 5. Photomicrograph of a Xenograft particle(a) surrounded by vital bone in a site grafted with xenograft. Hematoxylin and eosin staining. Magnification – 100X.

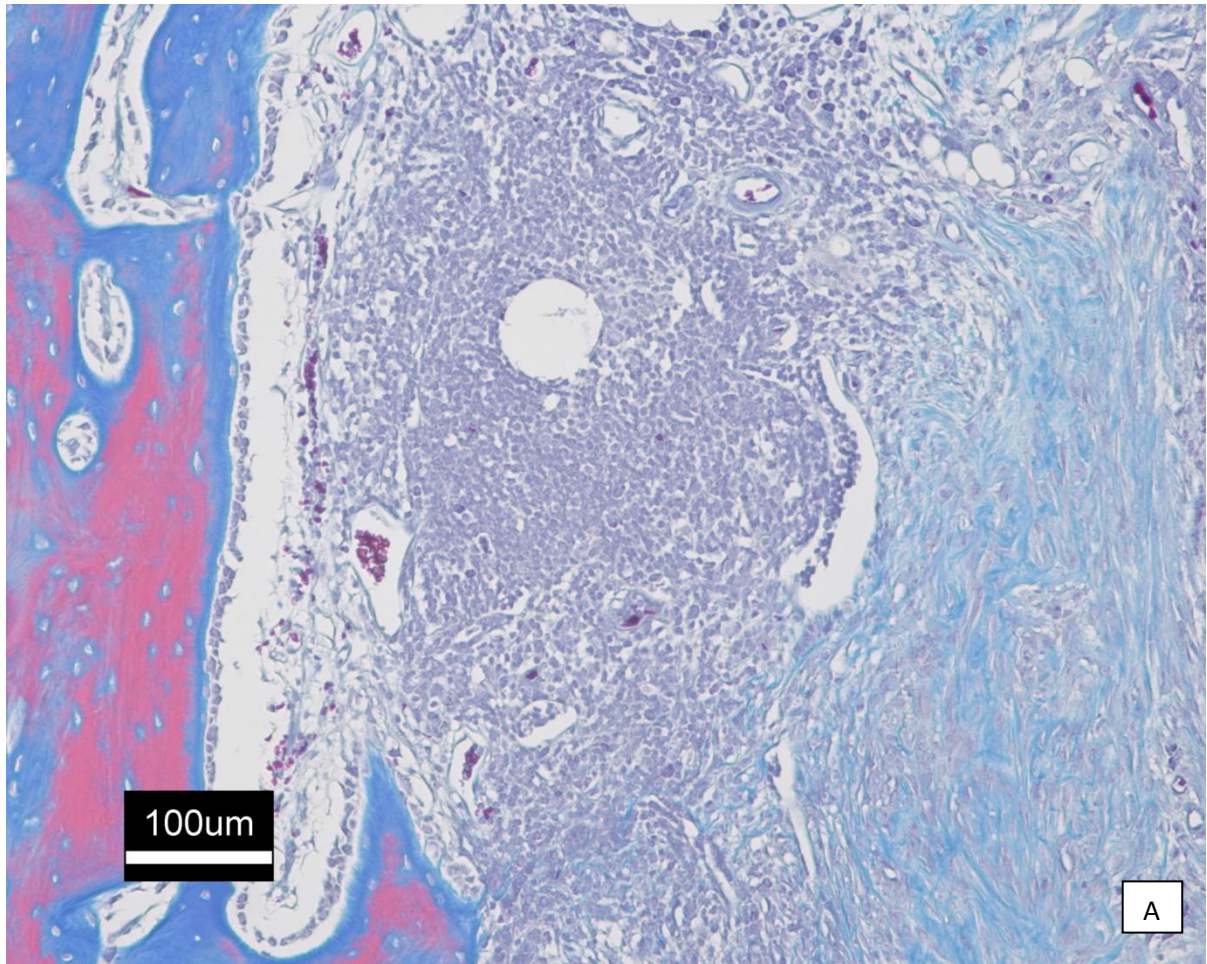


Figure 6. Photomicrograph of XBX site in one animal. Inflammatory cell infiltrate seen adjacent to the wall of the socket which is stained pink. Gomori Trichrome staining. Magnification – 100X.

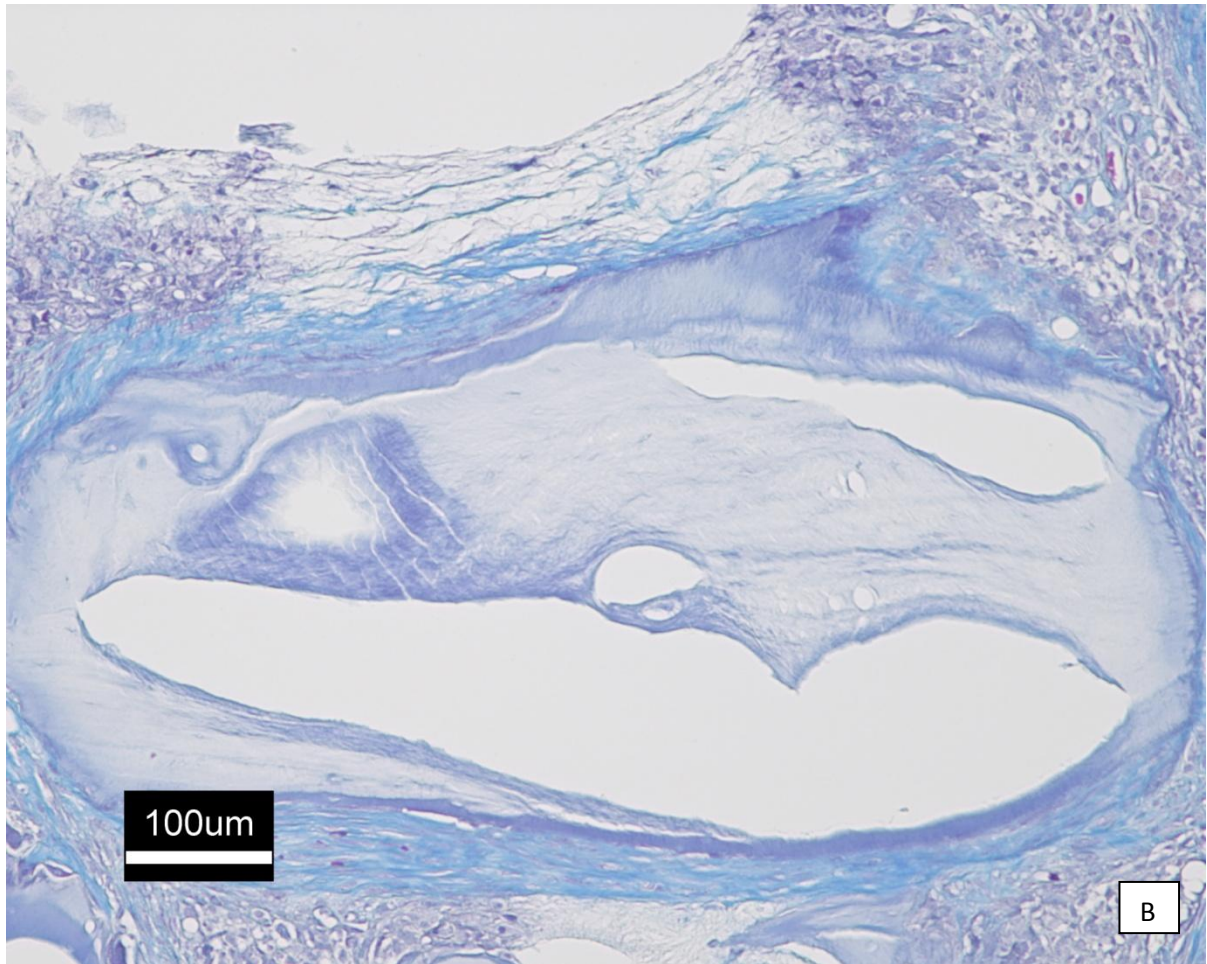


Figure 7. Photomicrograph of a xenograft particle in a XBX filled socket in one animal. Note the minimal amount of bone forming cells around the xenograft particle. Gomori Trichrome staining. Magnification – 100X.

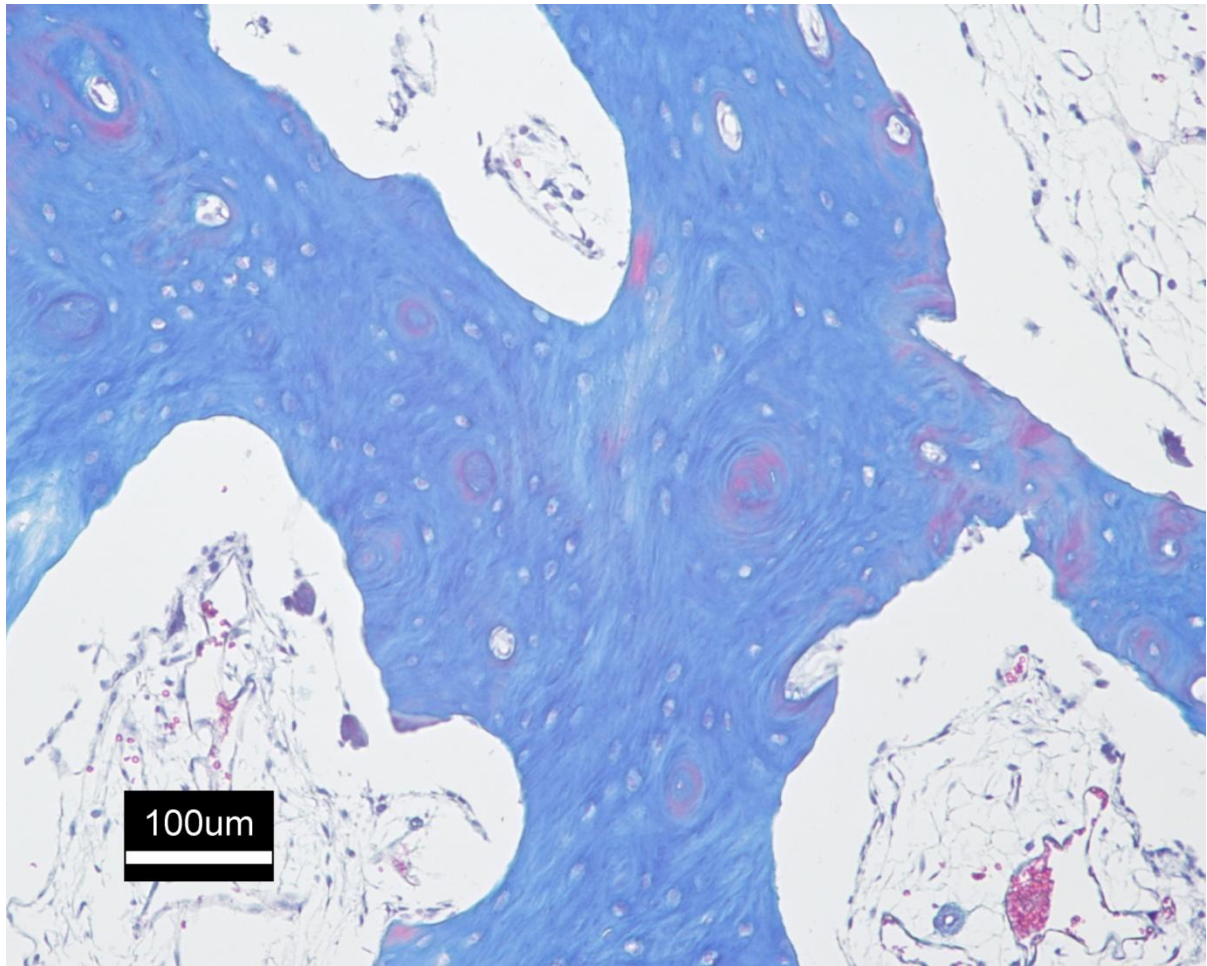


Figure 8. Photomicrograph of BP site with Gomori Trichrome staining. Immature vital bone is stained blue while the pink hue is suggestive of an advanced stage in the maturation process. Magnification – 100X.

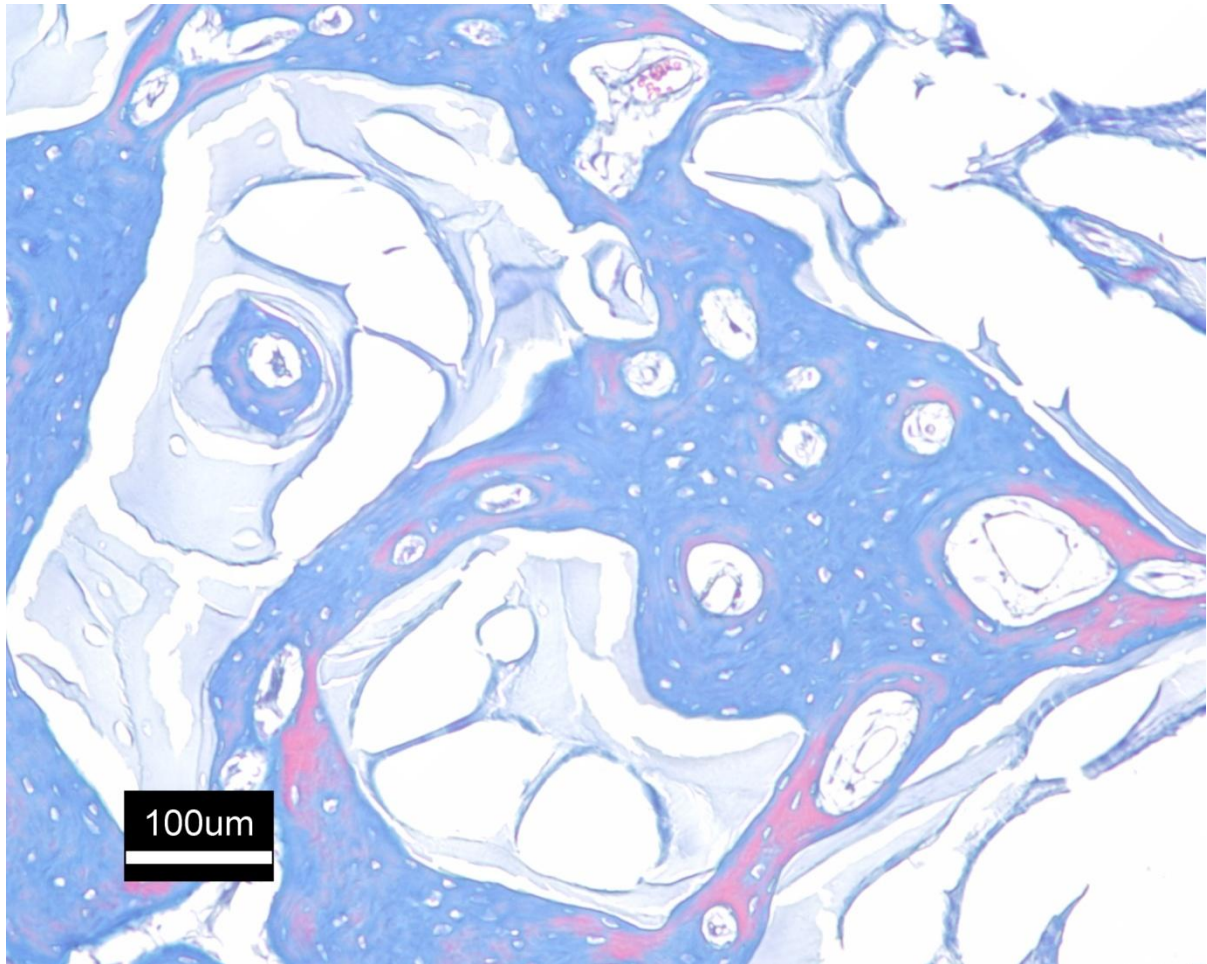


Figure 9. Photomicrograph of xenograft particles (light blue) surrounded by osseous tissue which is stained a darker shade of blue. The pink staining indicates an advanced stage of maturation when compared to the dark blue stained tissue. Gomori Trichrome staining. Magnification – 100X.

Ratio of Bone Volume to Total Volume with region of interest

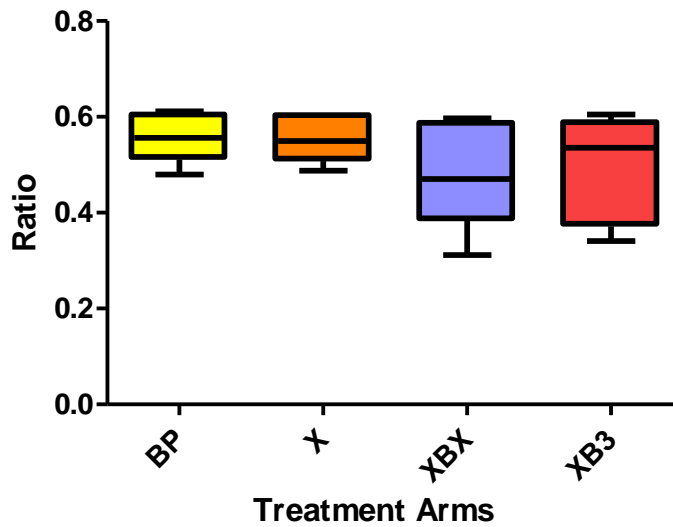


Figure 10. A box plot showing the ratio of bone volume to total volume within the region of interest. The X-axis shows the ratio while the Y-axis shows the different treatment arms.

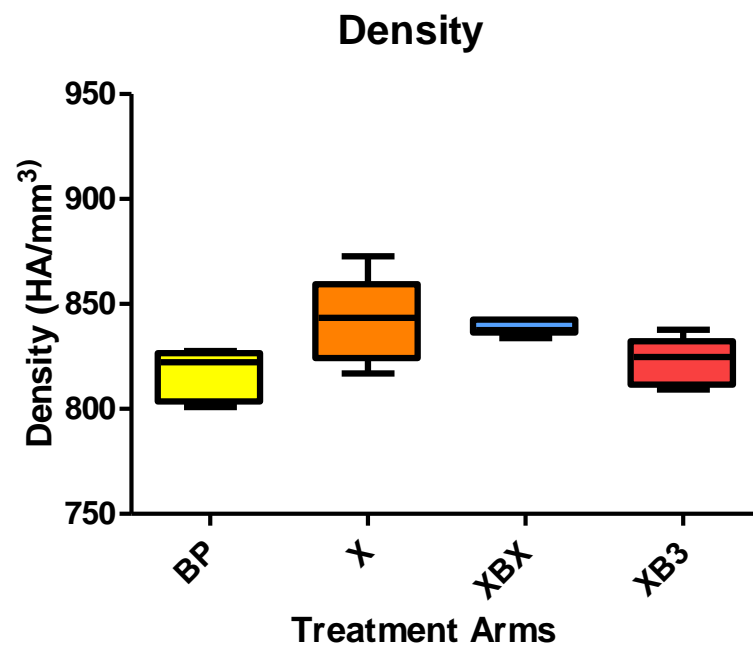


Figure 11. Box plot representing the density measurements in mg HA/mm³.

REFERENCES

1. Hupp JR. Preprosthetic surgery. In: Hupp JR, Ellis EI, Tucker M, editors. **Contemporary Oral and Maxillofacial Surgery**. 5th ed. Philadelphia: Mosby; 2008.
2. Frost HM. A 2003 update of bone physiology and wolff's law for clinicians. Angle Orthod. 2004 Feb;74(1):3-15.
3. Frost HM. Perspectives: Bone's mechanical usage windows. Bone Miner. 1992 Dec;19(3):257-71.
4. Atwood DA. Some clinical factors related to rate of resorption of residual ridges. 1962. J Prosthet Dent. 2001 Aug;86(2):119-25.
5. Grunder U, Polizzi G, Goene R, Hatano N, Henry P, Jackson WJ, et al. A 3-year prospective multicenter follow-up report on the immediate and delayed-immediate placement of implants. Int J Oral Maxillofac Implants. 1999 Mar-Apr;14(2):210-6.
6. Polizzi G, Grunder U, Goene R, Hatano N, Henry P, Jackson WJ, et al. Immediate and delayed implant placement into extraction sockets: A 5-year report. Clin Implant Dent Relat Res. 2000;2(2):93-9.
7. Tallgren A. The continuing reduction of the residual alveolar ridges in complete denture wearers: A mixed-longitudinal study covering 25 years. 1972. J Prosthet Dent. 2003 May;89(5):427-35.
8. Proceedings of the 4th international team for implantology (ITI) consensus conference, august 2008, stuttgart, germany. Int J Oral Maxillofac Implants. 2009;24 Suppl:7-278.
9. Reynolds MA, Aichelmann-Reidy ME, Branch-Mays GL. Regeneration of periodontal tissue: Bone replacement grafts. Dent Clin North Am. 2010 Jan;54(1):55-71.
10. Urist MR. Bone: Formation by autoinduction. Science. 1965 Nov 12;150(698):893-9.
11. Boyne PJ. Osseous repair of the postextraction alveolus in man. Oral Surg Oral Med Oral Pathol. 1966 Jun;21(6):805-13.
12. Martin P. Wound healing--aiming for perfect skin regeneration. Science. 1997 Apr 4;276(5309):75-81.
13. Aukhil I. Biology of wound healing. Periodontol 2000. 2000 Feb;22:44-50.
14. Doherty MJ, Ashton BA, Walsh S, Beresford JN, Grant ME, Canfield AE. Vascular pericytes express osteogenic potential in vitro and in vivo. J Bone Miner Res. 1998 May;13(5):828-38.

15. Friedenstein AJ, Chailakhyan RK, Gerasimov UV. Bone marrow osteogenic stem cells: In vitro cultivation and transplantation in diffusion chambers. Cell Tissue Kinet. 1987 May;20(3):263-72.
16. Kuru L, Griffiths GS, Petrie A, Olsen I. Alkaline phosphatase activity is upregulated in regenerating human periodontal cells. J Periodontal Res. 1999 Feb;34(2):123-7.
17. Devlin H, Sloan P. Early bone healing events in the human extraction socket. Int J Oral Maxillofac Surg. 2002 Dec;31(6):641-5.
18. Amler MH. The time sequence of tissue regeneration in human extraction wounds. Oral Surg Oral Med Oral Pathol. 1969 Mar;27(3):309-18.
19. Nevins M, Camelo M, De Paoli S, Friedland B, Schenk RK, Parma-Benfenati S, et al. A study of the fate of the buccal wall of extraction sockets of teeth with prominent roots. Int J Periodontics Restorative Dent. 2006 Feb;26(1):19-29.
20. Khan SN, Cammisa FP, Jr, Sandhu HS, Diwan AD, Girardi FP, Lane JM. The biology of bone grafting. J Am Acad Orthop Surg. 2005 Jan-Feb;13(1):77-86.
21. Pinholt EM, Haanaes HR, Roervik M, Donath K, Bang G. Alveolar ridge augmentation by osteoinductive materials in goats. Scand J Dent Res. 1992 Dec;100(6):361-5.
22. Pinholt EM, Bang G, Haanaes HR. Alveolar ridge augmentation by osteoinduction in rats. Scand J Dent Res. 1990 Oct;98(5):434-41.
23. Becker W, Urist M, Becker BE, Jackson W, Parry DA, Bartold M, et al. Clinical and histologic observations of sites implanted with intraoral autologous bone grafts or allografts. 15 human case reports. J Periodontol. 1996 Oct;67(10):1025-33.
24. Araujo MG, Lindhe J. Dimensional ridge alterations following tooth extraction. an experimental study in the dog. J Clin Periodontol. 2005 Feb;32(2):212-8.
25. Lekovic V, Kenney EB, Weinlaender M, Han T, Klokkevold P, Nedic M, et al. A bone regenerative approach to alveolar ridge maintenance following tooth extraction. report of 10 cases. J Periodontol. 1997 Jun;68(6):563-70.
26. Barone A, Aldini NN, Fini M, Giardino R, Calvo Guirado JL, Covani U. Xenograft versus extraction alone for ridge preservation after tooth removal: A clinical and histomorphometric study. J Periodontol. 2008 Aug;79(8):1370-7.
27. Goldberg VM, Stevenson S. Natural history of autografts and allografts. Clin Orthop Relat Res. 1987 Dec;(225):7-16.
28. Schallhorn RG. The use of autogenous hip marrow biopsy implants for bony crater defects. J Periodontol. 1968 May;39(3):145-7.

29. Buser D, Dula K, Belser UC, Hirt HP, Berthold H. Localized ridge augmentation using guided bone regeneration. II. surgical procedure in the mandible. Int J Periodontics Restorative Dent. 1995 Feb;15(1):10-29.
30. Buser D, Dula K, Belser U, Hirt HP, Berthold H. Localized ridge augmentation using guided bone regeneration. 1. surgical procedure in the maxilla. Int J Periodontics Restorative Dent. 1993;13(1):29-45.
31. Jensen J, Sindet-Pedersen S. Autogenous mandibular bone grafts and osseointegrated implants for reconstruction of the severely atrophied maxilla: A preliminary report. J Oral Maxillofac Surg. 1991 Dec;49(12):1277-87.
32. Misch CM, Misch CE, Resnik RR, Ismail YH. Reconstruction of maxillary alveolar defects with mandibular symphysis grafts for dental implants: A preliminary procedural report. Int J Oral Maxillofac Implants. 1992 Fall;7(3):360-6.
33. Barker D, Walls AW, Meechan JG. Ridge augmentation using mandibular tori. Br Dent J. 2001 May 12;190(9):474-6.
34. Proussaefs P. Clinical and histologic evaluation of the use of mandibular tori as donor site for mandibular block autografts: Report of three cases. Int J Periodontics Restorative Dent. 2006 Feb;26(1):43-51.
35. Petrungaro PS, Amar S. Localized ridge augmentation with allogenic block grafts prior to implant placement: Case reports and histologic evaluations. Implant Dent. 2005 Jun;14(2):139-48.
36. Jensen J, Sindet-Pedersen S, Oliver AJ. Varying treatment strategies for reconstruction of maxillary atrophy with implants: Results in 98 patients. J Oral Maxillofac Surg. 1994 Mar;52(3):210,6; discussion 216-8.
37. Block MS, Finger I, Lytle R. Human mineralized bone in extraction sites before implant placement: Preliminary results. J Am Dent Assoc. 2002 Dec;133(12):1631-8.
38. Babbush CA. The use of a new allograft material for osseous reconstruction associated with dental implants. Implant Dent. 1998;7(3):205-12.
39. Minichetti JC, D'Amore JC, Hong AY, Cleveland DB. Human histologic analysis of mineralized bone allograft (puros) placement before implant surgery. J Oral Implantol. 2004;30(2):74-82.
40. Boyan BD, Ranly DM, Schwartz Z. Use of growth factors to modify osteoinductivity of demineralized bone allografts: Lessons for tissue engineering of bone. Dent Clin North Am. 2006 Apr;50(2):217,28, viii.

41. Piattelli A, Scarano A, Corigliano M, Piattelli M. Comparison of bone regeneration with the use of mineralized and demineralized freeze-dried bone allografts: A histological and histochemical study in man. *Biomaterials*. 1996 Jun;17(11):1127-31.
42. Bender SA, Rogalski JB, Mills MP, Arnold RM, Cochran DL, Mellonig JT. Evaluation of demineralized bone matrix paste and putty in periodontal intraosseous defects. *J Periodontol*. 2005 May;76(5):768-77.
43. Holtzclaw D, Toscano N, Eisenlohr L, Callan D. The safety of bone allografts used in dentistry: A review. *J Am Dent Assoc*. 2008 Sep;139(9):1192-9.
44. Waasdorp J, Reynolds MA. Allogeneic bone onlay grafts for alveolar ridge augmentation: A systematic review. *Int J Oral Maxillofac Implants*. 2010 May-Jun;25(3):525-31.
45. Holtzclaw D, Toscano N, Eisenlohr L, Callan D. The safety of bone allografts used in dentistry: A review. *J Am Dent Assoc*. 2008 Sep;139(9):1192-9.
46. Araujo M, Linder E, Wennstrom J, Lindhe J. The influence of bio-oss collagen on healing of an extraction socket: An experimental study in the dog. *Int J Periodontics Restorative Dent*. 2008 Apr;28(2):123-35.
47. Berglundh T, Lindhe J. Healing around implants placed in bone defects treated with bio-oss. an experimental study in the dog. *Clin Oral Implants Res*. 1997 Apr;8(2):117-24.
48. Norton MR, Odell EW, Thompson ID, Cook RJ. Efficacy of bovine bone mineral for alveolar augmentation: A human histologic study. *Clin Oral Implants Res*. 2003 Dec;14(6):775-83.
49. Giannoudis PV, Dinopoulos H, Tsiridis E. Bone substitutes: An update. *Injury*. 2005 Nov;36 Suppl 3:S20-7.
50. Hallman M, Lundgren S, Sennerby L. Histologic analysis of clinical biopsies taken 6 months and 3 years after maxillary sinus floor augmentation with 80% bovine hydroxyapatite and 20% autogenous bone mixed with fibrin glue. *Clin Implant Dent Relat Res*. 2001;3(2):87-96.
51. Belay ED, Schonberger LB. Variant creutzfeldt-jakob disease and bovine spongiform encephalopathy. *Clin Lab Med*. 2002 Dec;22(4):849,62, v-vi.
52. Sogal A, Tofe AJ. Risk assessment of bovine spongiform encephalopathy transmission through bone graft material derived from bovine bone used for dental applications. *J Periodontol*. 1999 Sep;70(9):1053-63.
53. Yukna RA, Callan DP, Krauser JT, Evans GH, Aichelmann-Reidy ME, Moore K, et al. Multi-center clinical evaluation of combination anorganic bovine-derived hydroxyapatite

matrix (ABM)/cell binding peptide (P-15) as a bone replacement graft material in human periodontal osseous defects. 6-month results. J Periodontol. 1998 Jun;69(6):655-63.

54. Vastardis S, Yukna RA, Mayer ET, Atkinson BL. Periodontal regeneration with peptide-enhanced anorganic bone matrix in particulate and putty form in dogs. J Periodontol. 2005 Oct;76(10):1690-6.

55. Demers C, Hamdy CR, Corsi K, Chellat F, Tabrizian M, Yahia L. Natural coral exoskeleton as a bone graft substitute: A review. Biomed Mater Eng. 2002;12(1):15-35.

56. Giannoudis PV, Dinopoulos H, Tsiridis E. Bone substitutes: An update. Injury. 2005 Nov;36 Suppl 3:S20-7.

57. Topazian RG, Hammer WB, Boucher LJ, Hulbert SF. Use of alloplastics for ridge augmentation. J Oral Surg. 1971 Nov;29(11):792-8.

58. Ogoose A, Kondo N, Umezu H, Hotta T, Kawashima H, Tokunaga K, et al. Histological assessment in grafts of highly purified beta-tricalcium phosphate (OSferion) in human bones. Biomaterials. 2006 Mar;27(8):1542-9.

59. Gutierrez M, Lopes MA, Sooraj Hussain N, Lemos AF, Ferreira JM, Afonso A, et al. Bone ingrowth in macroporous bonelike for orthopaedic applications. Acta Biomater. 2008 Mar;4(2):370-7.

60. Allori AC, Sillon AM, Warren SM. Biological basis of bone formation, remodeling, and repair-part II: Extracellular matrix. Tissue Eng Part B Rev. 2008 Sep;14(3):275-83.

61. Yamasaki H, Sakai H. Osteogenic response to porous hydroxyapatite ceramics under the skin of dogs. Biomaterials. 1992;13(5):308-12.

62. Ripamonti U. Osteoinduction in porous hydroxyapatite implanted in heterotopic sites of different animal models. Biomaterials. 1996 Jan;17(1):31-5.

63. Kuboki Y, Takita H, Kobayashi D, Tsuruga E, Inoue M, Murata M, et al. BMP-induced osteogenesis on the surface of hydroxyapatite with geometrically feasible and nonfeasible structures: Topology of osteogenesis. J Biomed Mater Res. 1998 Feb;39(2):190-9.

64. Daculsi G, Passuti N, Martin S, Deudon C, Legeros RZ, Raher S. Macroporous calcium phosphate ceramic for long bone surgery in humans and dogs. clinical and histological study. J Biomed Mater Res. 1990 Mar;24(3):379-96.

65. Ye F, Lu X, Lu B, Wang J, Shi Y, Zhang L, et al. A long-term evaluation of osteoinductive HA/beta-TCP ceramics in vivo: 4.5 years study in pigs. J Mater Sci Mater Med. 2007 Nov;18(11):2173-8.

66. Ong JL, Chan DC. Hydroxyapatite and their use as coatings in dental implants: A review. Crit Rev Biomed Eng. 2000;28(5-6):667-707.
67. LeGeros RZ. Calcium phosphate-based osteoinductive materials. Chem Rev. 2008 Nov;108(11):4742-53.
68. Heymann D, Guicheux J, Rousselle AV. Ultrastructural evidence in vitro of osteoclast-induced degradation of calcium phosphate ceramic by simultaneous resorption and phagocytosis mechanisms. Histol Histopathol. 2001 Jan;16(1):37-44.
69. LeGeros RZ. Calcium phosphate materials in restorative dentistry: A review. Adv Dent Res. 1988 Aug;2(1):164-80.
70. Schopper C, Moser D, Sabbas A, Lagogiannis G, Spassova E, Konig F, et al. The fluorohydroxyapatite (FHA) FRIOS alipore is a suitable biomaterial for the reconstruction of severely atrophic human maxillae. Clin Oral Implants Res. 2003 Dec;14(6):743-9.
71. Wang M. Developing bioactive composite materials for tissue replacement. Biomaterials. 2003 Jun;24(13):2133-51.
72. van Eeden SP, Ripamonti U. Bone differentiation in porous hydroxyapatite in baboons is regulated by the geometry of the substratum: Implications for reconstructive craniofacial surgery. Plast Reconstr Surg. 1994 Apr;93(5):959-66.
73. Pollick S, Shors EC, Holmes RE, Kraut RA. Bone formation and implant degradation of coralline porous ceramics placed in bone and ectopic sites. J Oral Maxillofac Surg. 1995 Aug;53(8):915,22; discussion 922-3.
74. Nevins M, Giannobile WV, McGuire MK, Kao RT, Mellonig JT, Hinrichs JE, et al. Platelet-derived growth factor stimulates bone fill and rate of attachment level gain: Results of a large multicenter randomized controlled trial. J Periodontol. 2005 Dec;76(12):2205-15.
75. Merkx MA, Maltha JC, Stoelinga PJ. Assessment of the value of anorganic bone additives in sinus floor augmentation: A review of clinical reports. Int J Oral Maxillofac Surg. 2003 Feb;32(1):1-6.
76. Gatti AM, Simonetti LA, Monari E, Guidi S, Greenspan D. Bone augmentation with bioactive glass in three cases of dental implant placement. J Biomater Appl. 2006 Apr;20(4):325-39.
77. Galindo-Moreno P, Avila G, Fernandez-Barbero JE, Mesa F, O'Valle-Ravassa F, Wang HL. Clinical and histologic comparison of two different composite grafts for sinus augmentation: A pilot clinical trial. Clin Oral Implants Res. 2008 Aug;19(8):755-9.

78. Scarano A, Degidi M, Iezzi G, Pecora G, Piattelli M, Orsini G, et al. Maxillary sinus augmentation with different biomaterials: A comparative histologic and histomorphometric study in man. *Implant Dent.* 2006 Jun;15(2):197-207.
79. Norton MR, Wilson J. Dental implants placed in extraction sites implanted with bioactive glass: Human histology and clinical outcome. *Int J Oral Maxillofac Implants.* 2002 Mar-Apr;17(2):249-57.
80. Thomas MV, Puleo DA, Al-Sabbagh M. Bioactive glass three decades on. *J Long Term Eff Med Implants.* 2005;15(6):585-97.
81. Scarano A, Orsini G, Pecora G, Iezzi G, Perrotti V, Piattelli A. Peri-implant bone regeneration with calcium sulfate: A light and transmission electron microscopy case report. *Implant Dent.* 2007 Jun;16(2):195-203.
82. Thomas MV, Puleo DA. Calcium sulfate: Properties and clinical applications. *J Biomed Mater Res B Appl Biomater.* 2009 Feb;88(2):597-610.
83. Aimetti M, Romano F, Griga FB, Godio L. Clinical and histologic healing of human extraction sockets filled with calcium sulfate. *Int J Oral Maxillofac Implants.* 2009 Sep-Oct;24(5):902-9.
84. Guarnieri R, Aldini NN, Pecora G, Fini M, Giardino R. Medial-grade calcium sulfate hemihydrate (surgiplaster) in healing of a human extraction socket--histologic observation at 3 months: A case report. *Int J Oral Maxillofac Implants.* 2005 Jul-Aug;20(4):636-41.
85. Sbordon L, Bortolaia C, Perrotti V, Pasquantonio G, Petrone G. Clinical and histologic analysis of calcium sulfate in treatment of a post-extraction defect: A case report. *Implant Dent.* 2005 Mar;14(1):82-7.
86. Crespi R, Cappare P, Gherlone E. Dental implants placed in extraction sites grafted with different bone substitutes: Radiographic evaluation at 24 months. *J Periodontol.* 2009 Oct;80(10):1616-21.
87. Kenny SM, Buggy M. Bone cements and fillers: A review. *J Mater Sci Mater Med.* 2003 Nov;14(11):923-38.
88. Jamali A, Hilpert A, Debes J, Afshar P, Rahban S, Holmes R. Hydroxyapatite/calcium carbonate (HA/CC) vs. plaster of paris: A histomorphometric and radiographic study in a rabbit tibial defect model. *Calcif Tissue Int.* 2002 Aug;71(2):172-8.
89. Wozney JM, Rosen V, Celeste AJ, Mitsock LM, Whitters MJ, Kriz RW, et al. Novel regulators of bone formation: Molecular clones and activities. *Science.* 1988 Dec 16;242(4885):1528-34.
90. Urist MR. Bone: Formation by autoinduction. *Science.* 1965 Nov 12;150(698):893-9.

91. Nauth A, Giannoudis PV, Einhorn TA, Hankenson KD, Friedlaender GE, Li R, et al. Growth factors: Beyond bone morphogenetic proteins. J Orthop Trauma. 2010 Sep;24(9):543-6.
92. Nevins ML, Camelo M, Schupbach P, Kim DM, Camelo JM, Nevins M. Human histologic evaluation of mineralized collagen bone substitute and recombinant platelet-derived growth factor-BB to create bone for implant placement in extraction socket defects at 4 and 6 months: A case series. Int J Periodontics Restorative Dent. 2009 Apr;29(2):129-39.
93. Arora NS, Ramanayake T, Ren YF, Romanos GE. Platelet-rich plasma: A literature review. Implant Dent. 2009 Aug;18(4):303-10.
94. Badr M, Coulthard P, Alissa R, Oliver R. The efficacy of platelet-rich plasma in grafted maxillae. A randomised clinical trial. Eur J Oral Implantol. 2010 Autumn;3(3):233-44.
95. Bae JH, Kim YK, Myung SK. Effects of platelet-rich plasma (PRP) on sinus bone graft: Meta-analysis. J Periodontol. 2010 Nov 23.
96. Arora NS, Ramanayake T, Ren YF, Romanos GE. Platelet-rich plasma in sinus augmentation procedures: A systematic literature review: Part II. Implant Dent. 2010 Apr;19(2):145-57.
97. Hammarstrom L, Heijl L, Gestrelus S. Periodontal regeneration in a buccal dehiscence model in monkeys after application of enamel matrix proteins. J Clin Periodontol. 1997 Sep;24(9 Pt 2):669-77.
98. Bowers GM, Chadroff B, Carnevale R, Mellonig J, Corio R, Emerson J, et al. Histologic evaluation of new attachment apparatus formation in humans. part I. J Periodontol. 1989 Dec;60(12):664-74.
99. Bowers GM, Chadroff B, Carnevale R, Mellonig J, Corio R, Emerson J, et al. Histologic evaluation of new attachment apparatus formation in humans. part II. J Periodontol. 1989 Dec;60(12):675-82.
100. Bowers GM, Chadroff B, Carnevale R, Mellonig J, Corio R, Emerson J, et al. Histologic evaluation of new attachment apparatus formation in humans. part III. J Periodontol. 1989 Dec;60(12):683-93.
101. Schwartzmann M. Use of collagen membranes for guided bone regeneration: A review. Implant Dent. 2000;9(1):63-6.
102. Kozlovsky A, Aboodi G, Moses O, Tal H, Artzi Z, Weinreb M, et al. Bio-degradation of a resorbable collagen membrane (bio-gide) applied in a double-layer technique in rats. Clin Oral Implants Res. 2009 Oct;20(10):1116-23.

103. Thomaidis V, Kazakos K, Lyras DN, Dimitrakopoulos I, Lazaridis N, Karakasis D, et al. Comparative study of 5 different membranes for guided bone regeneration of rabbit mandibular defects beyond critical size. Med Sci Monit. 2008 Apr;14(4):BR67-73.
104. Murphy KG, Gunsolley JC. Guided tissue regeneration for the treatment of periodontal intrabony and furcation defects. A systematic review. Ann Periodontol. 2003 Dec;8(1):266-302.
105. Ashman A. Postextraction ridge preservation using a synthetic alloplast. Implant Dent. 2000;9(2):168-76.
106. Bartee BK. Extraction site reconstruction for alveolar ridge preservation. part 2: Membrane-assisted surgical technique. J Oral Implantol. 2001;27(4):194-7.
107. Lekovic V, Camargo PM, Klokkevold PR, Weinlaender M, Kenney EB, Dimitrijevic B, et al. Preservation of alveolar bone in extraction sockets using bioabsorbable membranes. J Periodontol. 1998 Sep;69(9):1044-9.
108. AlGhamdi AS, Ciancio SG. Guided tissue regeneration membranes for periodontal regeneration--a literature review. J Int Acad Periodontol. 2009 Jul;11(3):226-31.
109. Wang HL, Kiyonobu K, Neiva RF. Socket augmentation: Rationale and technique. Implant Dent. 2004 Dec;13(4):286-96.
110. Lupovici J. Revisiting the hopeless ridge: Part I--challenging the gold standard. Compend Contin Educ Dent. 2009 Apr;30(3):130,2, 134-9; quiz 140, 154.
111. Malamed SF. Local anesthetics: Dentistry's most important drugs, clinical update 2006. J Calif Dent Assoc. 2006 Dec;34(12):971-6.
112. Scully C. Medical problems in dentistry. 6th ed. Churchill Livingstone Elsevier; 2010.
113. Seymour AR, Meechan GJ, Yates SM. Pharmacology and dental therapeutics. 3rd ed. New York: Oxford University Press; 1999.
114. Fischer LM, Schlienger RG, Matter CM, Jick H, Meier CR. Discontinuation of nonsteroidal anti-inflammatory drug therapy and risk of acute myocardial infarction. Arch Intern Med. 2004 Dec 13-27;164(22):2472-6.
115. Mukherjee B, Roy G, Ghosh S. Development of denticap, a matrix based sustained release formulation for treatment of toothache, dental infection and other gum problem. Curr Drug Deliv. 2009 Apr;6(2):199-207.
116. Wang CF, Djalali AG, Gandhi A, Knaack D, De Girolami U, Strichartz G, et al. An absorbable local anesthetic matrix provides several days of functional sciatic nerve blockade. Anesth Analg. 2009 Mar;108(3):1027-33.

117. Block MS, Kent JN. A comparison of particulate and solid root forms of hydroxylapatite in dog extraction sites. J Oral Maxillofac Surg. 1986 Feb;44(2):89-93.
118. Cardaropoli G, Araujo M, Lindhe J. Dynamics of bone tissue formation in tooth extraction sites. an experimental study in dogs. J Clin Periodontol. 2003 Sep;30(9):809-18.
119. Figueiredo M, Henriques J, Martins G, Guerra F, Judas F, Figueiredo H. Physicochemical characterization of biomaterials commonly used in dentistry as bone substitutes--comparison with human bone. J Biomed Mater Res B Appl Biomater. 2010 Feb;92(2):409-19.